



Symptomatic Severe Stenosis of Cavernous Internal Carotid Artery Stenting: A Case Report with Short Literature Review

Mohan Karki¹ Girish Rajpal¹

¹Department of Neuro-Interventional Surgery, Max Super Speciality Hospital, Vaishali, Ghaziabad, Uttar Pradesh, India

Address for correspondence Girish Rajpal, MCh, FINR, Department of Neuro-Interventional Surgery, Max Super Speciality Hospital, Vaishali, Ghaziabad, Uttar Pradesh 201012, India (e-mail: brainsavior@gmail.com).

Asian J Neurosurg

Abstract

Intracranial internal carotid artery (ICA) stenosis is rarely reported as compared with extracranial ICA stenosis. Atherosclerosis is one of the major beginnings of stenosis of vasculatures, which may lead to ischemic stroke causing morbidity and mortality. We report the case of a 60-year-old man presented to us with complaints of multiple episodes of dizziness, mild headache, and transient left arm weakness for 3 months and had history of smoking, hypercholesterolemia (high level of low-density lipoprotein level = 220 mg/dL), diabetes mellitus, and hypertension under medication. No neurological deficits were observed at the time of admission. Patient underwent angioplasty and stenting with drug-eluting balloon-expandable coronary stent. Patient was discharged well at the 3rd day of procedure. No recurrence of stroke and restenosis were noted till 3 months of follow-up period. Stenting following angioplasty for treatment of symptomatic severe cavernous ICA stenosis with everolimus-eluting coronary balloon-expandable stent, Xience Xpedition, is safe and effective.

Keywords

- ▶ cavernous internal carotid artery
- ▶ severe stenosis
- ▶ angioplasty
- ▶ everolimus-eluting coronary stent
- ▶ outcome

Introduction

Acute ischemic stroke ipsilateral to intracranial artery stenosis (50–99%) was 11% at 1 year and 14% at 2 years have been reported in spite of the use of antithrombotic therapy.¹ Stenting has been shown to increase the safety and efficacy of balloon angioplasty in the treatment of extracranial carotid artery atherosclerosis.² However, stenting for intracranial internal carotid artery (IICA) atherosclerotic stenosis has not been accepted as routine procedure due to unavailability of suitable stent and insufficient outcome.³ But, a randomized control trial conducted by a single center in China described that stenting was a safe and effective treatment method for

carefully selected patients with intracranial atherosclerotic stenosis of the middle cerebral artery,⁴ and similarly, other studies have described it in petrous ICA⁵ and in precavernous ICA.⁶ Furthermore, a randomized controlled trial, Stenting versus Aggressive Medical Therapy for Intra-cranial Arterial Stenosis trial (SAMMPRIS), has described medical therapy as superior to stenting for severe symptomatic IICA stenosis caused by atherosclerosis.⁷ At present, self-expandable stent and drug-eluting balloon-expandable stent have been used for the treatment of ICA stenosis. We describe the successful treatment of symptomatic severe cavernous ICA stenosis with drug-eluting balloon-expandable flexible coronary stent.

DOI <https://doi.org/10.1055/s-0044-1792161>.
ISSN 2248-9614.

© 2024. Asian Congress of Neurological Surgeons. All rights reserved.

This is an open access article published by Thieme under the terms of the Creative Commons Attribution-NonDerivative-NonCommercial-License, permitting copying and reproduction so long as the original work is given appropriate credit. Contents may not be used for commercial purposes, or adapted, remixed, transformed or built upon. (<https://creativecommons.org/licenses/by-nc-nd/4.0/>)

Thieme Medical and Scientific Publishers Pvt. Ltd., A-12, 2nd Floor, Sector 2, Noida-201301 UP, India

Case Presentation

Case presentation with Endovascular Technique

A 60-year old man presented to us with complaints of multiple episodes of dizziness, mild headache, and transient left arm weakness for 3 months and had a history of smoking, hypercholesterolemia with high level of low-density lipoprotein (LDL) (220 mg/dL), diabetes mellitus, and hypertension under medication. No neurological deficits were observed at the time of admission. We performed digital subtraction angiography (DSA) that revealed 99, 60, and 50% stenosis in the cavernous, lacerum, and distal cervical segment, respectively (►Fig. 1A). So, we advised the patient for angioplasty plus stenting for severe stenosis of intracranial part of ICA because of recurrent of minor stroke even after regularly having of dual antiplatelets therapy. Tab Ecospirin 300 mg and tab Brilinta 180 mg were given to the patient few seconds before femoral access. Under local anesthesia, percutaneous access was obtained from the right femoral artery. Note that 5,000 U heparin was given through

introducer femoral sheath. Distal access guiding catheter, 6F Envoy (Cerenovus, Johnson & Johnson), was placed in the proximal ICA with the help of a 0.035-inch guidewire (Radio Focus, Terumo). Lateral, anterior, and oblique images were obtained before procedure. Angioplasty was done for by 1.5 × 10 mm Alveo HP-PTCA Catheter (BROSMED) (►Fig. 1B); and then 2.5 × 15 and 3 × 12 mm NC Trek, Coronary Dilation Catheter (ABBOTT) with support of microwire Whisper ES 0.014-inch (ABBOTT) one by one simultaneously (►Fig. 1C). Successful reduction of stenosis was noted in all the three segments after angioplasty (►Fig. 1D). A second-generation, everolimus-eluting coronary stent, Xience Xpedition, 4 × 15 mm (ABBOTT) was successfully deployed (►Fig. 1E and F). Final angiography was obtained immediately and 20 minutes after the procedure that showed good distal flow without thrombus and successful reduction in stenosis after stenting (►Fig. 1G). No neurological deficits were noted during intra- and postprocedure. Patient was discharged well at 3rd day of the procedure. Patient was counseled to continue tab Ecospirin 75mg/day and tab

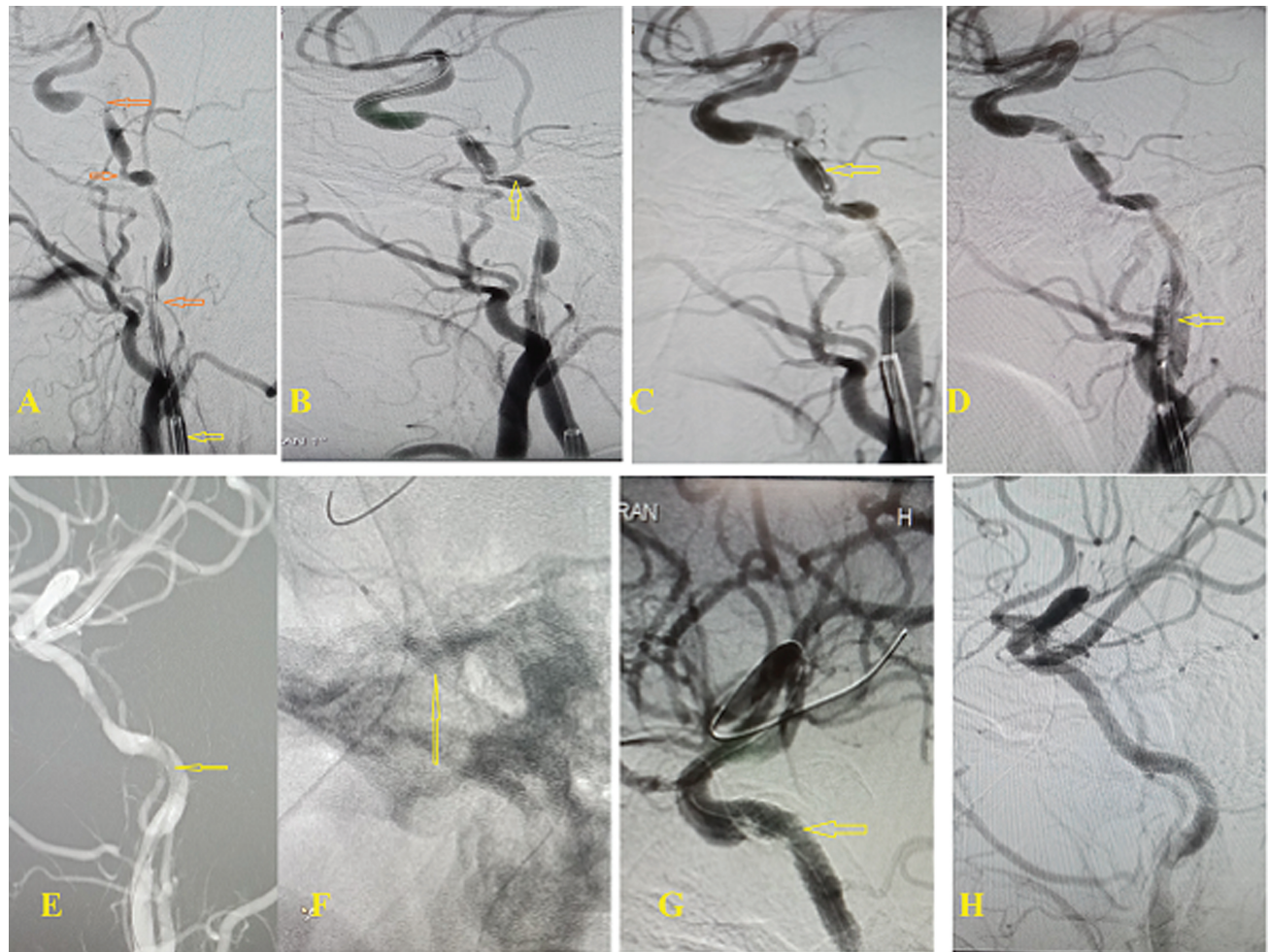


Fig. 1 (A) Lateral view of the internal carotid artery (ICA) with yellow arrow from proximal to distal-distal cervical, lacerum, and cavernous segment stenosis; red arrow, balloon of Alveo HP PTCA at cervical stenosis region; and yellow arrow, Envoy catheter. (B) Lateral view of ICA with yellow arrow—balloon of Alveo HP PTCA. (C) Lateral view of ICA after balloon dilation with yellow arrow—NC Trek, coronary dilation catheter. (D and E) Lateral and anteroposterior view of ICA with yellow arrow—everolimus-eluting balloon-expandable coronary stent. (F) Yellow arrow—Stent placement in the cavernous segment before deployment. (G) Lateral and successful dilation of the stenotic segment after stent deployment. (H) Anteroposterior view of ICA showing follow-up digital subtraction angiography (DSA) at 3 months without restenosis.

Brilinta 90mg/ twice a day for 3 months, after which he was advised to continue 75 mg/day Ecospirin only. At follow-up of 3 months, he had no any recurrence of symptoms (► Fig. 1H). This study is retrospective, so informed consent was taken from the patient and hospital, and approved by the Local Institutional Review Board.

Discussion

Stroke initiates a significant health burden in the population, with an estimated 16 million new stroke each year and prevalence exceeding 60 million.⁸ Atheroma plaque may develop along the course of ICA and its major branches into middle and anterior cerebral artery. Intracranial atherosclerotic disease is one of the major predictors for ischemic stroke worldwide, where middle cerebral arteries are most commonly affected, followed by the basilar artery, ICAs, and vertebral arteries.⁹ Our patient had a history of being a chronic smoker, hypercholesterolemia, hypertension, as well as diabetes mellitus and these are major risk factors for intracranial and extracranial carotid artery lumen narrowing because of deposition of atheroma plaque that may impair distal perfusion or distal embolization, which is similar to a report by another study.⁹ Diagnosis of carotid atherosclerosis is mainly done with computerized tomography angiography, magnetic resonance angiography, transcranial Doppler, and DSA, where DSA is an invasive procedure, but preferred as a gold standard screening modality.

Management of severe extracranial internal carotid stenosis with symptomatic patients (> 70%) can be performed by revascularization with carotid endarterectomy or angioplasty with stenting and dual-antiplatelet therapy.¹⁰ Similarly, aggressive medical management or endovascular therapy can be applied for severe IICA stenosis with symptomatic patients. Treatment of vascular stenosis with stent improves acute and long-term patency, and minimizes the risk of mortality as well as the distal embolization by snaring atheroma plaque between vessel wall and stent.² Nevertheless, angioplasty plus stenting have been considered as an alternative approach for the treatment of intracranial artery stenosis with the development of flexible low-profile self- and balloon-expandable stent.^{11,12} These procedure has not been beneficial due to unfitness of stent to track well in the intracranial vasculature. A large randomized control trial, SAMMPRIS,⁷ described that medical therapy was superior to stenting for severe symptomatic intracranial carotid stenosis with unfavorable outcome.

First-generation drug-eluting balloon-expandable coronary stent is associated with higher rate of in-stent restenosis (ISR) because of low radial force on the wall of the vessels,¹³ which is similar to the report by a study where angioplasty alone without stent placement also caused higher restenosis because of the elastic recoil of the blood vessels.¹⁴ A second-generation drug-eluting coronary stent has been discovered to tackle this complication, where it reduces the risk of ISR due to antiproliferative agents that prevent intraluminal hyperplasia.¹⁵ We successfully treated our patient with a second-generation,

everolimus drug-eluting balloon-expandable coronary stent for cavernous ICA, and no stroke as well as neurological deficits and restenosis were observed during the intra- and postprocedure and at 3 months of follow-up period, which is similar to the results of other studies.¹⁶ But, 4.5 to 14.7% of stroke rate have been reported at 30 days after stent placement in intracranial arteries.^{7,11,17,18} We believed that medical management with dual-antiplatelet therapy for 3 months followed by single-antiplatelet therapy, lowering LDL with statin therapy (< 100 mg/dL), targeting blood pressure 140 to 130/90 to 80 mm hg or controlling hypertension antihypertensive therapy, and lifestyle modification such as smoking prohibition, weight loss, diet control, and exercise routinely should be advised to patients for the treatment of symptomatic intracranial stenosis with stenting.¹⁹ However, our patient had a successful outcome without any recurrence of stroke following the procedure. There are some limitations, such as this is a retrospective study of a single case and the follow-up period is too short. Large number of cases with long follow-up period are required to study and evaluate proper effectiveness of this study.

Conclusion

Stenting following angioplasty for the treatment of symptomatic severe cavernous ICA stenosis with everolimus-eluting coronary balloon-expandable stent, Xience Xpedition, is safe and effective. However, proper patient selection, proper pre-/intra-/postprocedural medication, and lifestyle modification should be followed to obtain successful outcome in patients with symptomatic severe intracranial atherosclerotic stenosis.

Authors' Contributions

M.K. conceived and designed the study, collected data, and wrote and drafted the manuscript. G.R. was responsible for editing and providing technical feedback with the design and analyses.

Ethical Approval

This is a retrospective study, so informed consent was taken from the institute and all involved participants included in this study.

Funding

None.

Conflict of Interest

None declared.

References

- 1 Kasner SE, Chimowitz MI, Lynn MJ, et al; Warfarin Aspirin Symptomatic Intracranial Disease Trial Investigators. Predictors of ischemic stroke in the territory of a symptomatic intracranial arterial stenosis. *Circulation* 2006;113(04):555-563
- 2 Yadav JS, Roubin GS, Iyer S, et al. Elective stenting of the extracranial carotid arteries. *Circulation* 1997;95(02):376-381

- 3 Sacco RL, Adams R, Albers G, et al; American Heart Association American Stroke Association Council on Stroke Council on Cardiovascular Radiology and Intervention American Academy of Neurology. Guidelines for prevention of stroke in patients with ischemic stroke or transient ischemic attack: a statement for healthcare professionals from the American Heart Association/American Stroke Association Council on Stroke: co-sponsored by the Council on Cardiovascular Radiology and Intervention: the American Academy of Neurology affirms the value of this guideline. *Stroke* 2006;37(02):577-617
- 4 Miao Z, Jiang L, Wu H, et al. Randomized controlled trial of symptomatic middle cerebral artery stenosis: endovascular versus medical therapy in a Chinese population. *Stroke* 2012;43(12):3284-3290
- 5 Feldman RL, Trigg L, Gaudier J, Galat J. Use of coronary Palmaz-Schatz stent in the percutaneous treatment of an intracranial carotid artery stenosis. *Cathet Cardiovasc Diagn* 1996;38(03):316-319
- 6 Al-Mubarak N, Gomez CR, Vitek JJ, Roubin GS. Stenting of symptomatic stenosis of the intracranial internal carotid artery. *AJNR Am J Neuroradiol* 1998;19(10):1949-1951
- 7 Chimowitz MI, Lynn MJ, Derdeyn CP, et al; SAMMPRIS Trial Investigators. Stenting versus aggressive medical therapy for intracranial arterial stenosis. *N Engl J Med* 2011;365(11):993-1003
- 8 Mukherjee D, Patil CG. Epidemiology and the global burden of stroke. *World Neurosurg* 2011;76(06):S85-S90
- 9 Banerjee C, Chimowitz MI. Stroke caused by atherosclerosis of the major intracranial arteries. *Circ Res* 2017;120(03):502-513
- 10 Barrett KM, Brott TG. Stroke caused by extracranial disease. *Circ Res* 2017;120(03):496-501
- 11 Fiorella D, Levy EI, Turk AS, et al. US multicenter experience with the wingspan stent system for the treatment of intracranial atheromatous disease: periprocedural results. *Stroke* 2007;38(03):881-887
- 12 Gupta R, Schumacher HC, Mangla S, et al. Urgent endovascular revascularization for symptomatic intracranial atherosclerotic stenosis. *Neurology* 2003;61(12):1729-1735
- 13 Gröschel K, Schnaudigel S, Pilgram SM, Wasser K, Kastrup A. A systematic review on outcome after stenting for intracranial atherosclerosis. *Stroke* 2009;40(05):e340-e347
- 14 Marks MP, Wojak JC, Al-Ali F, et al. Angioplasty for symptomatic intracranial stenosis: clinical outcome. *Stroke* 2006;37(04):1016-1020
- 15 Bangalore S, Kumar S, Fusaro M, et al. Short- and long-term outcomes with drug-eluting and bare-metal coronary stents: a mixed-treatment comparison analysis of 117 762 patient-years of follow-up from randomized trials. *Circulation* 2012;125(23):2873-2891
- 16 Ma L, Wang F, Feng H, et al. Endovascular treatment of symptomatic severe intracranial atherosclerotic stenosis with a novel intracranial dedicated drug-eluting stent: a more effective treatment approach. *Front Neurol* 2024;15:1304524
- 17 SSYLIVIA Study Investigators. Stenting of Symptomatic Atherosclerotic Lesions in the Vertebral or Intracranial Arteries (SSYLIVIA): study results. *Stroke* 2004;35(06):1388-1392
- 18 Bose A, Hartmann M, Henkes H, et al. A novel, self-expanding, nitinol stent in medically refractory intracranial atherosclerotic stenoses: the Wingspan study. *Stroke* 2007;38(05):1531-1537
- 19 Narwal P, Cutting S, Prabhakaran S, Yaghi S. Diagnosis and management of active intracranial atherosclerotic disease: a case study. *Stroke* 2018;49(06):e221-e223