



# A Comparison of Anterior and Posterior Dental Autotransplants: A Systematic Review

Fulvia Galletti<sup>1</sup> Niccolò Motta Jones<sup>2</sup> Francisco Real-Voltas<sup>2</sup> Alice Rose Greethurst<sup>2</sup>  
Lorenza Stagno d'Alcontres<sup>3</sup> Gabriele Cervino<sup>1</sup> Luca Fiorillo<sup>1,4,5</sup> Francesca De Angelis<sup>6</sup>  
Cosimo Galletti<sup>7</sup>

<sup>1</sup> Department of Biomedical and Dental Sciences and Morphological and Functional Imaging, University of Messina, Messina, Italy

<sup>2</sup> School of Dentistry, Department of Integrated Dentistry, International University of Catalonia, San Cugat del Vallès, Barcelona, Spain

<sup>3</sup> Private Practice, Messina, Italy

<sup>4</sup> Department of Dental Cell Research, Dr. D.Y. Patil Dental College and Hospital, Dr. D.Y. Patil Vidyapeeth, Pimpri, Pune, Maharashtra, India

<sup>5</sup> Multidisciplinary Department of Medical-Surgical and Odontostomatological Specialties, University of Campania "Luigi Vanvitelli," Naples, Italy

<sup>6</sup> Department of Oral and Maxillo-Facial Sciences, Sapienza University of Rome; Rome, Italy

<sup>7</sup> Faculty of Medicine and Surgery, Kore University of Enna, Enna, Italy

**Address for correspondence** Luca Fiorillo, DDS, PhD, Department of Biomedical and Dental Sciences and Morphological and Functional Imaging University of Messina, Via Consolare Valeria, 1–98100 Messina, Italy (e-mail: lfiorillo@unime.it).

Eur J Gen Dent

## Abstract

The ability to restore both function and aesthetics after tooth loss is a cornerstone of modern dentistry. Various treatments are available for replacing missing teeth, among which dental autotransplantation has emerged as an innovative approach. Historically, tooth autotransplantation has been a common remedy for dental avulsion in young patients; however, in recent years, it has gained recognition as a viable and predictable option for replacing hopeless teeth in adults as well. This study aims to systematically evaluate and compare the effectiveness of anterior versus posterior dental autotransplants, while also providing an overview of the techniques employed in these procedures. Utilizing online platforms such as PubMed and the UIC University library, articles published between 2010 and 2023 were selected for review. The findings of this systematic review indicate that dental autotransplantation, regardless of whether it occurs in the anterior or posterior region, yields optimal aesthetic and functional results alongside long-term positive outcomes. Autotransplantation is particularly beneficial for trauma-related tooth loss, especially in younger patients, where ongoing bone growth necessitates the preservation of bone levels. The studies reviewed consistently demonstrate that this technique offers significant advantages in terms of function, appearance, and structural integrity, with compelling evidence supporting its long-term viability. In summary, dental autotransplantation is a valuable treatment option that not only addresses the immediate concerns following tooth loss but also contributes to maintaining oral health and aesthetics over time.

## Keywords

- ▶ dental autotransplants
- ▶ dental autotransplantation
- ▶ anterior sector
- ▶ posterior sector
- ▶ success rate

DOI <https://doi.org/10.1055/s-0044-1793850>.  
ISSN 2320-4753.

© 2024. The Author(s).

This is an open access article published by Thieme under the terms of the Creative Commons Attribution License, permitting unrestricted use, distribution, and reproduction so long as the original work is properly cited. (<https://creativecommons.org/licenses/by/4.0/>)  
Thieme Medical and Scientific Publishers Pvt. Ltd., A-12, 2nd Floor, Sector 2, Noida-201301 UP, India

## Introduction

Dental autotransplantation is a unique procedure that combines traditional dental techniques with recent technological advancements. It involves the surgical transplantation of a patient's own tooth from one location in their mouth to another. This procedure is typically considered when a tooth is lost or deemed nonviable due to trauma, decay, or congenital absence. The main advantage of dental autotransplantation is that the transplanted tooth integrates naturally into the patient's jawbone, maintaining natural aesthetics and function. The process requires careful selection of a suitable donor tooth, typically a developing premolar or wisdom tooth, and precise surgical technique to ensure successful reattachment and minimal complications. With advances in imaging technology, such as three-dimensional (3D) computed tomography (CT) scans, and improved surgical protocols, dental autotransplantation has become a viable option for patients seeking to preserve their natural teeth and avoid prosthetic replacements.

Dental autotransplantation has historical roots in earlier cultures, including those of the ancient Egyptians, Greeks, and Romans. These ancient cultures understood the importance of teeth for chewing and attractiveness. Attempts to replace missing or damaged teeth have been documented in the past, using materials such as human and animal teeth, as well as stones and metals.<sup>1</sup>

Dental autotransplantation has thrived in the modern era as a well-established method supported by science. The journey of dental autotransplants from its rudimentary beginnings to its current state exemplifies the dynamic interplay between historical practices and modern advancements. Each phase of development has been influenced by evolving knowledge in surgical techniques, regenerative medicine, and understanding of dental health, ultimately enhancing patient outcomes today.

There are various reasons why this technique has become more popular. First, it provides a practical way to replace missing teeth with real, living alternatives. Second, it gives people the choice to keep teeth that would otherwise need to be removed because of damage, periodontal disease, or other dental issues. Finally, dental autotransplantation aligns with the rising need for patient-centered and minimally invasive dental care. With the development of cutting-edge dental imaging technologies like cone-beam computed tomography (CBCT), the technique of dental autotransplantation has evolved dramatically. For effective autotransplantation outcomes, thorough assessment of tooth architecture, root morphology, and bone density is made possible by CBCT.<sup>2</sup>

Additionally, increased success rates and fewer postoperative complications have been made possible by advancements in dental tools, materials, and surgical methods. The operation normally entails the cautious extraction of the donor tooth, careful implantation of the donor tooth into its new location, and site preparation in the recipient area. The effectiveness of a dental autotransplant depends on several variables, including careful patient selection, precise root

growth assessment, and rigorous adherence to surgical guidelines. Time is one of the key factors in the success of this therapy. Many authors have discussed the importance of preparing the host socket prior to the extraction of the transplanted tooth. This preparation maintains the integrity of the periodontal tissues, thus reducing the risk of ankylosis. To minimize the time the tooth spends outside the dental alveolus, CBCT scans are used to provide 3D replicas of the donor tooth. These replicas are then printed to scale and used to plan the autotransplant surgery, ensuring the socket is ready to receive the donor tooth.<sup>3</sup>

Most surgeries require some kind of socket manipulation to allow for the correct placement of the autotransplanted tooth. The first modern-day autotransplantations were conducted in the 1950s, and the success rate was as low as 50%. This low success rate was due to the poor quality of the technique and the high level of trauma during the extraction of the replacing teeth.<sup>4</sup>

The success of dental autotransplants varies depending on a variety of factors such as root formation, clinician expertise, extraoral time, anatomy of the tooth, anatomy of the host socket, and blood flow in the needed region. Among these factors, the viability of the periodontal ligaments (PDLs) stands above most others. The importance of a viable PDL is crucial for the success of this surgery.<sup>5,6</sup>

The PDL is the anatomical structure that connects the tooth to the alveolar bone. It allows for proprioception, one's ability to recognize the force applied to the dental structure. It consists of type 1 collagen fibers and blood vessels, and is innervated to allow proper sensory perception. Between the root surface and the lamina dura, there is a radiolucent area called the PDL space. This area may expand in conditions including periodontal disease, vertical root fracture, and/or occlusal trauma.<sup>7</sup>

Traditional dental autotransplants were performed using autogenous third molars to replace nonrestorable or missing first molars. As the technique improved and success rates increased, the idea of implementing this surgery in the aesthetic area began. For anterior dental autotransplants, aesthetic satisfaction is a significant factor in patient contentment.

When replacing anterior teeth, the chosen teeth for this procedure are usually canines and premolars. When choosing the donor tooth, various characteristics must be taken into account; one of the most important is the stage of root formation. When the donor tooth has an open apex, the success rate is higher and endodontic treatments are not always necessary. Conversely, when the tooth has a closed apex, an endodontic procedure is required for the surgery's success.<sup>8,9</sup>

This treatment has been proven successful in many different case reports. Anterior and posterior autotransplants have been studied but rarely compared.

Despite being a well-established procedure, several gaps in current knowledge exist that can significantly impact clinical practice and patient outcomes. There is a lack of large-scale, long-term studies evaluating the success rates of dental autotransplants in diverse populations and

demographic groups. Understanding the longevity and success rates of autotransplanted teeth can aid in patient selection and treatment planning. If certain demographic groups show lower success rates, clinicians may need to adjust their recommendations and provide additional support or alternative treatments. Also, there is insufficient consensus on the specific indications for dental autotransplantation, particularly regarding the types of teeth most suitable for the procedure (e.g., wisdom teeth vs. anterior teeth). Clinicians may face uncertainty when deciding whether to perform an autotransplantation versus other treatment options, such as implants or bridges. Clear guidelines can improve decision-making and outcomes for patients. Variability in surgical techniques, preservation protocols (like storage media), and postoperative care increases the difficulty in establishing best practices. Standardizing procedures could enhance success rates and reduce complications, thereby improving patient outcomes. Clear protocols can help training and increase the confidence of less experienced practitioners. Also, there is limited understanding of the biological mechanisms underlying successful autotransplantation, including the factors influencing periodontal healing, root development, and pulp vitality posttransplant. Greater insights into these biological factors can inform better techniques, improve prognosis prediction, and enable advances in regenerative dentistry. Among other gaps, there is a lack of research on the emotional and psychosocial impacts of dental autotransplants on patients, particularly in children and adolescents. Understanding these aspects can improve patient support during the treatment process and posttreatment care, thus enhancing the overall patient experience and adherence to follow-up care. There are insufficient comparative studies between dental autotransplants and other options such as dental implants, especially regarding cost-effectiveness and quality-of-life outcomes. Clinicians need evidence-based data to guide treatment decisions; understanding how autotransplantation compares with other options can lead to better resource allocation in treatment plans.

Finally, limited research exists identifying predictors of failure in dental autotransplants, such as age, type of tooth, and preexisting conditions. Identifying risk factors for unsuccessful outcomes can aid practitioners in patient selection, preoperative counseling, and development of tailored postoperative care plans.

Addressing these gaps in knowledge surrounding dental autotransplants is pivotal to advancing clinical practice. Improved understanding will enhance the predictability of outcomes, refine treatment protocols, and ultimately lead to better health-related quality of life for patients. Engaging in future research will help delineate best practices, better inform patient consent processes, and improve overall satisfaction with dental treatment options.

This systematic review aims to reach a conclusion about the success of anterior and posterior autotransplants and to offer an overview of the techniques used in these procedures, understanding the gaps in current scientific literature and offering dentists clinical recommendations.

## Methods

### Search Strategy

For this systematic review, an independent electronic literature search was conducted using the online platforms PubMed and UIC University library. In this study, articles published between 2010 and 2023 were selected.

A series of key words were utilized in different combinations for the research: “Dental autotransplants” OR “Dental autotransplantation” AND “Anterior sector,” “Dental autotransplants” OR “Dental autotransplantation” AND “Posterior sector,” “Success rate” AND “Dental autotransplants” OR “Dental autotransplantation.”

### Study Selection Process

For this study, specific criteria were introduced for the selection process. The following are the specific inclusion and exclusion criteria.

Inclusion criteria:

- Articles published after 2010.
- Official language of publication must be English.
- Case reports.
- Assessment of the integrity of the autotransplanted tooth.

Exclusion criteria:

- Article published before 2010.
- Articles in which the official language is not English.
- Articles that are not case reports.
- Case reports on animals.

### Selection of Studies

Studies were selected based on the clear inclusion and exclusion criteria previously mentioned. After an initial thorough scanning, duplicates and articles that did not respond to the article question were removed.

### Data Extraction and Method of Analysis

Data gathered from the selected studies were added in a result table. Data such as author, publication year, study design, and outcomes were introduced when present. Risk of bias was assessed using the Joanna Briggs Institute critical appraisal tools (– **Tables 1** and **2**).

A total of 281 articles were identified through the research of the database of PubMed and the library of the Universitat Internacional de Catalunya (UIC). After the removal of duplicates, 219 articles were then screened and filtered through the inclusion and exclusion criteria. Ten articles were deemed suitable for this research. The Preferred Reporting Items for Systematic Reviews and Meta-Analyses (PRISMA) flow diagrams were then prepared to outline the process of study selection. Two diagrams were designed to separate the research between anterior and posterior dental autotransplantations as the research itself was done separately.

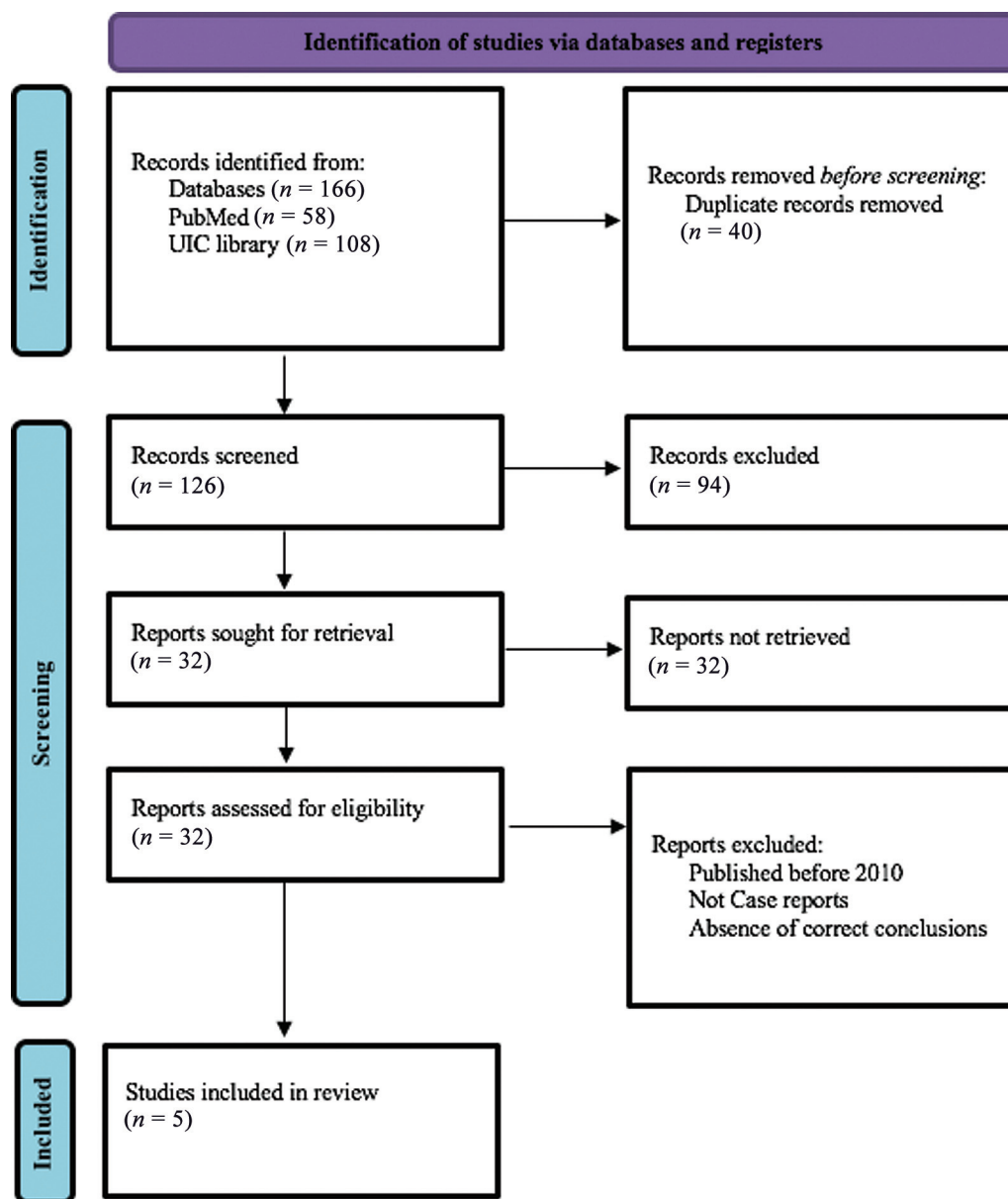
– **Figs. 1** and **2** show the flowcharts illustrating the study selection processes for anterior and posterior dental autotransplants.

**Table 1** Risk of bias assessment for anterior dental autotransplantation articles (Quality of Assessment Joanna Briggs)

Anterior	Demographic characteristics described	Patient's history described	Current clinical condition described	Diagnostic tests and assessment methods described	Intervention/procedure described	Postintervention clinical condition described	Adverse effects described	Takeaway lesson described	Overall appraisal
Premolar transplantation to replace a missing central incisor	+	+	+	+	+	+	-	+	Include/exclude
Multidisciplinary approach for autotransplantation and restoration of a maxillary premolar into an area of an avulsed anterior tooth: a case report with a 6-year follow-up	+	+	+	+	+	+	+	+	Include/exclude
Mandibular premolar transplantation to replace missing maxillary anterior teeth: a multidisciplinary approach	+	-	+	+	+	+	-	+	Include/exclude
Guided autotransplantation of an immature premolar to the maxillary incisor region with immediate restoration of esthetics: a case report	+	+	+	+	+	+	-	+	Include/exclude
Tooth autotransplantation using an interdisciplinary approach to rehabilitation in a young patient: case report with 7-year follow-up	+	-	+	+	+	+	-	+	Include/exclude

**Table 2** Risk of bias assessment for posterior dental autotransplantation articles (Quality of Assessment Joanna Briggs)

Posterior	Demographic characteristics described	Patient's history described	Current clinical condition described	Diagnostic tests and assessment methods described	Intervention/procedure described	Postintervention clinical condition described	Adverse effects described	Takeaway lesson described	Overall appraisal
Orthognathic treatment with autotransplantation of a third molar	+	+	+	+	+	+	+	+	Include/exclude
Immediate oral surgical management of external dental fistula: technical note of immediate tooth autotransplantation	+	+	+	+	+	+	-	+	Include/exclude
Third molar autotransplant planning with a tooth replica	+	+	+	+	+	+	-	+	Include/exclude
Reconsidering some standards in immediate autotransplantation of teeth: case report with 2-year follow-up	+	+	+	+	+	+	-	+	Include/exclude
Autotransplantation of mandibular third molar with buccal cortical plate to replace vertically fractured mandibular second molar: a novel technique	+	+	+	+	+	+	-	+	Include/exclude



**Fig. 1** Flowchart illustrating study selection process for anterior dental autotransplants.

The following systematic review was registered on PROSPERO on September 30, 2024, with code ID 595886.

## Results

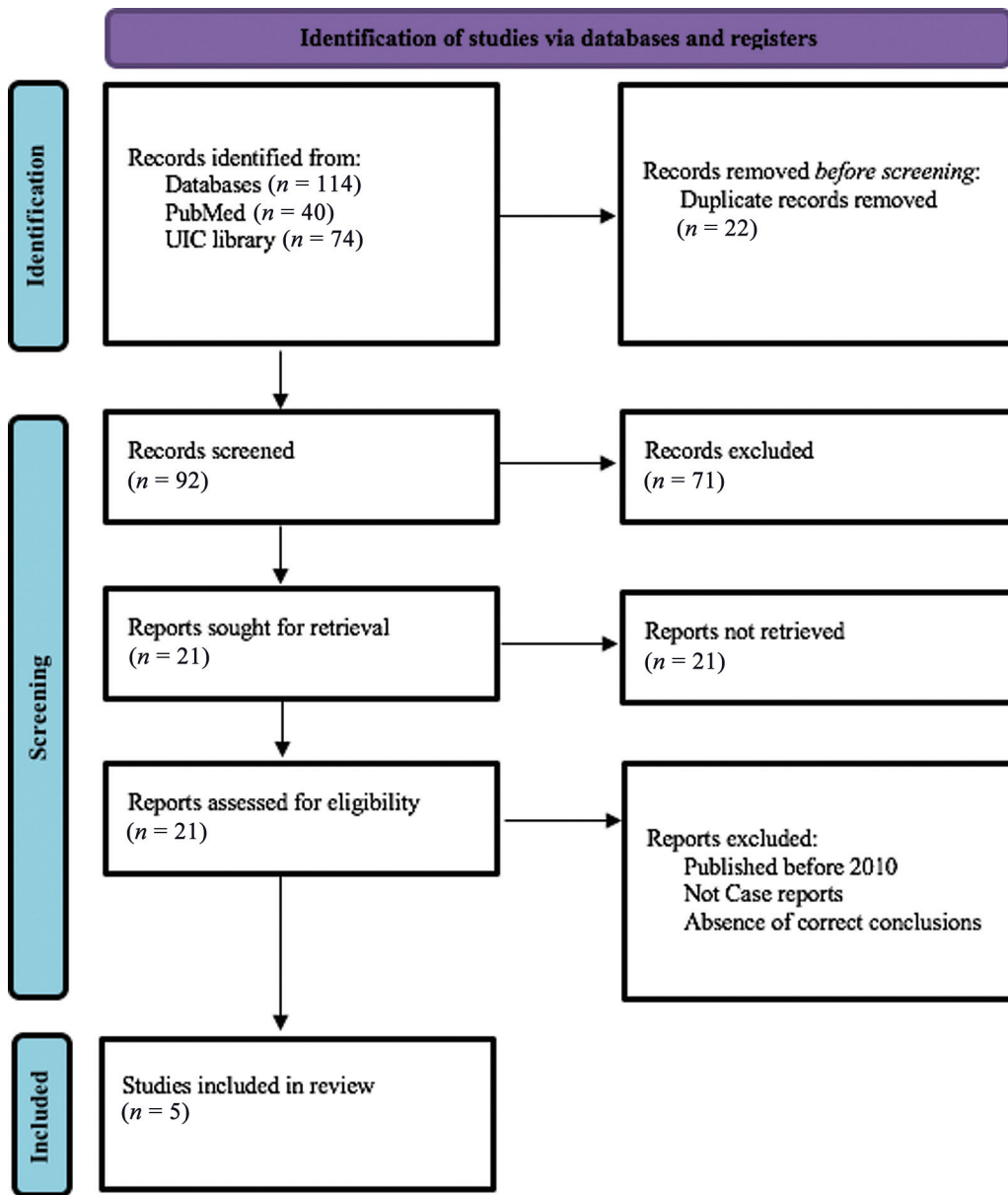
The articles regarding anterior autotransplantations provided 100% survivability rate in all studies. Tooth mobility was analyzed in all articles except the study by Tankittiwat et al.<sup>10</sup>

None presented tooth mobility when analyzing the final results. Probing depth was also considered a variable to quantify the survivability of this procedure. All articles presented physiological probing except for the articles by Cunha et al<sup>13</sup> and Velozo et al,<sup>12</sup> which did not specify this variable in the results.

Endodontic treatment was performed in two out of the five articles. 3D-printed replicas were used in two cases, and

radiographic pathology was not present in any of the studies, although it was not analyzed in Tankittiwat et al's article.<sup>10</sup>

Regarding posterior autotransplantations, every article presented tooth survivability throughout the course of the treatment and checkups. There was no presence of tooth mobility in any of the articles. Regarding probing, two of the three presented pathological probing, while the other three had physiological depths. Root canal treatment was performed in four of the five articles. 3D replicas were used in two cases, and no radiographic pathology was described in any of the studies. The articles describe a series of examinations of outcomes and considerations of the autotransplantation technique of anterior and posterior teeth following dental injuries of traumatic origin or dental agenesis, allowing us to assess its efficacy, clinical implications, and diverse techniques implemented. Cunha et al describe the use of the autotransplantation technique in a young patient with an



**Fig. 2** Flowchart illustrating study selection process for posterior dental autotransplants.

avulsed maxillary incisor. A premolar was transplanted in the position of the maxillary incisor, allowing for the maintenance of the bone margin levels; this perfectly describes the viability of this technique and allows for short- and long-term bone preservation.<sup>13</sup>

Berlin-Broner et al described the efficacy of this technique from an aesthetic and functional perspective. A maxillary premolar was autotransplanted to a maxillary incisor and followed a 6-year control period. The results showed good aesthetic outcomes as well as good preservation of the hard and soft tissues surrounding the tooth. Furthermore, they assessed the efficacy of this technique with the addition of endodontic treatment in cases of external inflammatory resorption.<sup>14</sup>

Tankittiwat et al describe the first monthly checkup as “thick PDL space, normal alveolar bone level, large pulpal size, but the remaining three fourths of root length.” This not

only provides additional confirmation of the efficacy of this technique but also highlights its advantage in orthodontically planned treatment.<sup>10</sup>

Abella Sans et al provided a case of a maxillary premolar transplanted to a maxillary central incisor. At a 2-year follow-up, the tooth presented “no pain, swelling, mobility, discoloration, and with periodontal probing depths within normal limits”; the case did present obliteration of the canal in the autotransplanted teeth.<sup>11</sup>

The presence of pulp calcification was also noted in Velozo et al.’s study, which required endodontic treatment. Post-endodontic treatment, a 3-year follow-up presented healing of the periapical tissues.<sup>12</sup>

Regarding posterior autotransplantation, Choi and Hwang described the use of orthognathic surgery and autotransplantation as a combined therapy. The combination of both allowed for a successful dental and skeletal result. This

approach presents the potential for introducing autotransplantation into more complex orthodontic cases with surgical necessities.<sup>15</sup>

Ohga et al presented a case of a dental autotransplantation as a treatment for a dental fistula with apical periodontitis. The study provides long-term stability of the transplanted tooth with additional bone formation during the 6-year checkups.<sup>16</sup> It further emphasizes the idea of autotransplantation being a less invasive strategy, especially for managing apical periodontitis associated with dental fistulas.

Finally, Al-Khanati and Beit provided a critical perspective on one of the fundamental steps of dental autotransplantation; endodontic treatment. Successful transplantation has been shown without the necessity of an endodontic treatment in a mature tooth, questioning the need to perform endodontic treatments 2 weeks post-op.<sup>17</sup>

Zufía et al presented a change in what is known as the standard procedure for autotransplant. The authors were presented with a periodontally compromised tooth with a significant defect in the buccal region due to a vertical root fracture. Then they decided to proceed with the autotransplantation of the third molar with a buccal bone plate to try and solve the vertical defect.<sup>18</sup>

The comparison between anterior and posterior dental autotransplants reveals significant differences in focus and challenges. Anterior transplants prioritize aesthetics and phonetic function, crucial for maintaining facial harmony during expressions like smiling and talking. The gingival margin and the appearance of the transplanted tooth are vital, especially in the maxillary anterior region, as highlighted in study by Albaloochy et al,<sup>19</sup> which emphasize the role of root development and ease of extraction for successful outcomes. On the other hand, posterior transplants concentrate on functional restoration, particularly for chewing, with molars playing a key role in mastication. The anatomy and root complexity of the posterior teeth make extraction and placement more challenging, as noted by Zufía et al.<sup>18</sup>

Both anterior and posterior autotransplantations benefit from computer-aided design and computer-aided manufacturing (CAD-CAM) technology, as noted by Peña-Cardelles et al, which reduces extraoral time and minimizes damage to the PDL, improving success rates<sup>20</sup>: in this study, a 12-month follow-up confirmed the efficacy of the 3D models and the digital planification, as well the increase in predictability due to its higher precision and reduced extraoral time of the donor tooth (► **Tables 3–6**).

While there is no significant statistical difference in survival rates, the secondary outcomes, such as aesthetic satisfaction in anterior cases and functional restoration in posterior cases, differ. Both, however, offer biological advantages over dental implants, particularly regarding bone regeneration and proprioception.

## Discussion

The introduction of CAD-CAM in this type of technique, as described by Peña-Cardelles et al<sup>20</sup> allows for prior planning of the surgery the printing of an exact replica outside of the

mouth. By doing this, the authors describe a significant decrease in the time the donor tooth is outside of the mouth.

Velozo et al<sup>12</sup> also use 3D-printed replicas as a way to reduce extraoral time through the use of CBCT scans. This reduction minimizes the risk of damage to the PDL. Abella Sans et al,<sup>11</sup> in their study, further confirm the effectiveness of CAD-CAM in increasing the success of this surgery. They describe an improvement in survival rates to 95.5 to 100% and the ability to reduce extraoral time to an average of 12 seconds, compared with the 5-minute average of conventional techniques.

One of the main differences between anterior and posterior autotransplants is the difficulty in extracting the donor tooth. The location and root anatomy are critical factors when trying to extract the tooth in the most atraumatic way. From an anterior perspective, achieving a good aesthetic result is essential for maintaining harmony between the teeth during facial expressions such as talking, smiling, and laughing. In a systematic review by Singh et al, the authors describe dental autotransplantation as a highly successful treatment but stress the importance of further studies. Their results show success rates “above 90%, even with long-term follow-up and a survival rate up to 98%.”<sup>21</sup>

As shown in Zufía et al’s study,<sup>18</sup> autotransplantation combined with a bone plate attached to the transplanted tooth is a viable technique for resolving both tooth loss and vertical bone defects.

This positive effect of dental autotransplantation can also be seen in a study by Plakwicz et al, where a third molar was transplanted to the socket of an ankylosed first mandibular molar. The first molar produced lower marginal bone than the adjacent teeth. The donor tooth was placed at the level of the ankylosed tooth and later extruded using orthodontics, allowing it to achieve the correct position in occlusion. “The marginal bone level of the transplanted molar, which was equal to that of the adjacent teeth” is the result of a successful autotransplantation.<sup>22</sup>

The ability to reform the PDL allows for bone migration, which would not be possible with a dental implant. Anterior autotransplantations have been the subject of fewer studies compared with the autotransplantation of third molars in the posterior sector. In a systematic review following traumatic dental injuries, Albaloochy et al examined the results of 144 autotransplanted premolars in 120 patients, with a mean age of 12.2 years and an average follow-up of 3.7 years. There was a 93% survival rate and an 80% success rate. Uncontrolled external inflammatory resorption (2.7%), external replacement resorption (12.5%), and both resorption types in 4.9% of teeth were unfavorable outcomes. Conditions at the recipient location, graft handling, and donor tooth root maturity were all strongly correlated with periodontal healing. Twenty-seven of the immature teeth had pulp revascularization, with 70% exhibiting healing signals. The study found that autotransplanted premolars in the front maxilla have good results, with donor tooth root development and ease of extraction and implantation serving as important prognostic markers.<sup>19</sup>



**Table 3** Results table for anterior dental autotransplantation

Article title	Authors	Date of publication	Type of study	Results	Conclusions
Premolar transplantation to replace a missing central incisor	Cunha et al	March 2015	Case report	Successful transplantation with good periodontal support	Autotransplantation can achieve aesthetic and functional results, with long-term positive outcomes
Multidisciplinary approach for autotransplantation and restoration of a maxillary premolar into an area of an avulsed anterior tooth: a case report with a 6-year follow-up	Berlin-Broner et al	May 2023	Case report	Positive outcome with no significant complications after 6 y	Autotransplantation is a viable option for missing anterior teeth in young patients
Mandibular premolar transplantation to replace missing maxillary anterior teeth: a multidisciplinary approach	Tankittiwat et al	September 2021	Case report	Successful space closure and aesthetic restoration	Demonstrates the efficacy of autotransplantation with multidisciplinary treatment in complex cases
Guided autotransplantation of an immature premolar to the maxillary incisor region with immediate restoration of esthetics: a case report	Abella Sans et al	2024	Case report	Patient follow up at 4 wk presented "no sign of pain, mobility, and sinus tract," periapical healing, and root formation	Demonstrates the efficacy of premolar autotransplantation in an orthodontically planned guided surgery
Tooth autotransplantation using an interdisciplinary approach to rehabilitation in a young patient: case report with 7-year follow-up	Veloze et al	2021	Case report	Mandibular premolar was successfully transplanted to the maxillary central incisor. The patient underwent endodontic treatment 4 y posttransplantation	Successful transplantation with regain of class II relationship, and correction of upper crowding and periapical tissues

**Table 4** Results table for posterior dental autotransplantations

Article title	Authors	Date of publication	Type of study	Results	Conclusions
Orthognathic treatment with autotransplantation of a third molar	Choi and Hwang	November 2013	Case report	Successful treatment improving facial appearance and function without the need for an implant	Effective for patients with mandibular protrusion and facial asymmetry
Immediate oral surgical management of external dental fistula: technical note of immediate tooth autotransplantation	Ohga et al	2021	Case report	Successful treatment with new bone formation after 6 y	Less invasive therapy for apical periodontitis with external dental fistula
Third molar autotransplant planning with a tooth replica	Peña-Cardelles et al	2021	Case report	Successful use of 3D-printed tooth replica for transplant planning	3D-printed replicas improve predictability and prognosis of autotransplants
Reconsidering some standards in immediate autotransplantation of teeth: case report with 2-year follow-up	Al-Khanati and Beit	2022	Case report	Successful immediate autotransplantation with healthy outcomes over 2 y	Challenges the necessity of routine endodontic treatment for all autotransplanted mature teeth
Autotransplantation of mandibular third molar with buccal cortical plate to replace vertically fractured mandibular second molar: a novel technique	Zufia et al	2017	Case report	Successful	Provides a variation to the original technique with the addition of bone plates

**Table 5** Table of Variables for Anterior dental autotransplantations

Anterior								
Article title	Authors	Survivability	Tooth mobility	Physiological probing	Endodontic treatment	3D replica	Radiographic pathology	
Premolar transplantation to replace a missing central incisor	Cunha et al	Yes	No	NA	No	NO	No	
Multidisciplinary approach for autotransplantation and restoration of a maxillary premolar into an area of an avulsed anterior tooth: a case report with a 6-year follow-up	Berlin-Broner et al	Yes	No	Yes	Yes	No	No	
Mandibular premolar transplantation to replace missing maxillary anterior teeth: a multidisciplinary approach	Tankittiwat et al	Yes	NA	Yes	No	No	NA	
Guided autotransplantation of an immature premolar to the maxillary incisor region with immediate restoration of esthetics: a case report	Abella Sans et al	Yes	No	Yes	No	Yes	No	

**Table 5** (Continued)

Anterior							
Article title	Authors	Survivability	Tooth mobility	Physiological probing	Endodontic treatment	3D replica	Radiographic pathology
Tooth autotransplantation using an interdisciplinary approach to rehabilitation in a young patient: case report with 7-year follow-up	Veloza et al	Yes	No	NA	Yes	Yes	No

**Table 6** Table of variables for posterior dental autotransplantations

Posterior							
Article title	Authors	Survivability	Tooth mobility	Physiological probing	Endodontic treatment	3D replica	Radiographic pathology
Orthognathic treatment with autotransplantation of a third molar	Choi and Hwang	Yes	No	No	Yes	No	No
Immediate oral surgical management of external dental fistula: technical note of immediate tooth autotransplantation	Ohga et al	Yes	NA	No	Yes	No	No
Third molar autotransplant planning with a tooth replica	Peña-Cardelles et al	Yes	No	Yes	Yes	Yes	No
Reconsidering some standards in immediate autotransplantation of teeth: case report with 2-year follow-up	Al-Khanati and Beit	Yes	No	Yes	No	Yes	No

(Continued)

**Table 6** (Continued)

Posterior							
Article title	Authors	Survivability	Tooth mobility	Physiological probing	Endodontic treatment	3D replica	Radiographic pathology
Autotransplantation of mandibular third molar with buccal cortical plate to replace vertically fractured mandibular second molar: a novel technique	Zuffa et al	Yes	No	yes	Yes	No	No

Studies analyzing anterior autotransplantations demonstrate their great efficiency in providing an optimal aesthetic result, from a good gingival margin to a good crown/veneer restoration. The ability to reform the PDL gives the autotransplanted tooth a significant advantage over dental implants.<sup>23</sup> Its ability to regain proprioception allows the patient to feel and understand the pressure and forces of chewing. Another advantage of maintaining the PDL is the ability to guide bone generation; as stated in Cunha et al, the bone managed to regenerate only thanks to the “preservation of the cementum and the periodontal ligament.”<sup>13</sup>

As Maddalone et al confirm in their study, the major factors that positively influence the exit of the dental autotransplants were fixation with splint and a periodontal probing depth less than 4 mm after the healing period.<sup>24</sup>

Regarding the retaining system in dental autotransplants, it has been the center of discussion for its effect on improving the survivability of the transplanted teeth. Not every case presented in the included articles use the retaining system. Excessive use and implementation of rigid splint retainers can increase the chance of ankylosis of the tooth, while options such as semi-rigid or thermoplastic removable retainers are safer and allow for a higher chance of reintegration. The splint retainers should be used for around 1 to 6 weeks depending on the mobility of the tooth at the time of reimplantation.<sup>24,25</sup>

When assessing the integrity and importance of maintaining the PDL, Berlin-Broner et al describe an increased risk of inflammatory resorption.<sup>14</sup> This condition is usually associated with “the stage of root development”; the more the root is formed, the higher the risk of inflammatory resorption. In this specific case, with the root being an open apex and suffering from inflammatory resorption 2.5 months after autotransplantation, the authors explain this phenomenon due to having damaged more than 25% of the PDL during the extraoral phase. The pathology was then resolved with intracanal medication and endodontic treatment. The authors further discuss the necessity of endodontic treatment in open apex teeth, concluding that each case must be assessed individually. If the tooth does not present any pulp-related pathology, revascularization is possible. In closed apices, endodontic treatment can be performed during the extraoral phase or 2 weeks post-op. However, standard protocols are sometimes questioned and experimented with to understand how personalized the autotransplantation treatment should be.<sup>14</sup>

In Al-Khanati and Beit’s case report, the authors present a mature upper right third molar autotransplantation to a first lower right molar socket without the need for standard endodontic treatment. Results after 2 years show no discoloration and a positive outcome to vitality tests.<sup>10</sup>

To determine if there is a difference between the outcomes of posterior and anterior dental autotransplantation, we can see that the technique used in these treatments is essentially the same, with adjustments made to individualize the treatment for the patient’s needs. All studies presented in this article provide evidence of the high survivability of this kind of treatment and highlight its ability to be customized

based on difficulty, anatomy, and necessity. Anterior autotransplantations are highly regarded for complying with aesthetic and phonetic functions, with the gingival margin essential for the harmony of the smile and its exposure during smiling and speaking. Conversely, posterior autotransplantations focus on restoring specific dental elements for functional purposes. Molars are essential for effective mastication, making the replacement of missing first or second molars crucial. Comparing dental autotransplantation and dental implants, Singh et al's study indicates a 5-year survival rate for dental autotransplantation ranging between 81 and 98.2%.<sup>21</sup>

Comparatively, Howe et al showed a 96.4% survival rate for implants at 10 years.<sup>26-28</sup>

Despite significant advancements in dental autotransplants, several limitations are evident in current research. One major limitation is the methodological variability between studies. Different extraction techniques, handling and management of donor teeth, and varying criteria for outcome assessment make it challenging to directly compare results across studies. This variability can affect the interpretation of findings and their universal applicability.

Additionally, many studies suffer from relatively small sample sizes and short follow-up periods. Small samples can limit the generalizability of results, while short follow-ups may not reveal long-term complications or sustained effectiveness of the treatment over time.

Inconsistent reporting of complications is another significant issue. Not all studies provide detailed information on complications such as inflammatory resorption or ankylosis, which can lead to a partial view of the risks associated with dental autotransplantation.

Differences in the management of mature versus immature roots, and the variable approach to endodontic treatment, represent further limitations. The lack of standardized protocols for managing root maturity can affect outcomes and predictability.

Finally, the absence of standardized protocols, such as the duration of splint use or fixation techniques, impacts the reproducibility and overall effectiveness of the treatment. While personalized treatments can be a strength, variations in clinical practices can lead to disparate results.

Future researches, in addition to filling these gaps present in the literature and in this review, will have to make use of the new technologies available today. Among these, the use of CAD-CAM technology and 3D printing has already demonstrated improvements in preoperative planning and treatment precision. These technologies allow for the creation of exact replicas of donor teeth and reduce the time the tooth is outside the mouth, thereby minimizing the risk of PDL damage. Future implementation of these technologies could standardize techniques and improve the reproducibility of results.

Advanced imaging technologies, such as CBCT, provide detailed images that can improve the assessment of root morphology and surgical planning. Integrating these technologies with artificial intelligence (AI) based predictive

analytics could further optimize treatment personalization and anticipate potential complications.

Innovative biomaterials and regenerative techniques represent another promising area. The development of new materials for bone grafts and PDL regeneration can enhance the integration and success of dental autotransplants. Future researches could benefit from focusing on how these materials and techniques can be better integrated into treatment protocols.

Additionally, the use of remote monitoring technologies and data management systems could facilitate more accurate and detailed patient follow-up. Applying long-term monitoring systems and analyzing collected data could help identify patterns of success and complications, thus improving treatment strategies and outcome predictions.

Finally, adopting standardized protocols and evidence-based guidelines could reduce variability between studies and improve the comparability of results. Creating a shared knowledge base and standardizing clinical practices could lead to significant improvements in research quality and consistency regarding dental autotransplants.

In summary, new technologies not only have the potential to enhance the effectiveness of dental autotransplantation treatments but also to address the limitations of current research, contributing to a deeper understanding and more predictable outcomes in the future.

## Conclusions

The analysis of autotransplantation for trauma-related tooth loss, particularly in young patients, highlights its efficacy in maintaining both functional and aesthetic outcomes. The consensus across multiple studies underscores the technique's ability to preserve bone health during critical growth periods, making it a viable alternative to traditional dental implants.

While autotransplantation requires meticulous planning and patient selection, its long-term success in producing biologically active teeth is well documented. The findings suggest that minor adaptations in the procedure can be tailored to the individual needs of patients, which might enhance outcomes without compromising the treatment's foundational principles.

It is important to note that, despite a slightly lower survival rate compared with modern dental implants, autotransplantation remains a preferred method for adolescents. This preference is mainly due to the procedure's compatibility with ongoing bone development, effectively allowing the transplanted tooth to integrate into the growing occlusion.

In the cases where autotransplantation does not succeed, alternative treatments, such as fixed or removable prosthetics, are viable options, ensuring that patients can still achieve satisfactory restorative results. However, the need for further research is evident, as the current body of evidence, while promising, does not establish the long-term effectiveness of this approach comprehensively.

The success of autotransplanted teeth depends on various factors, and there are several practical recommendations that dentists can follow to maximize the chances of success:

- **Donor selection:** Carefully choose the donor tooth, preferably a healthy permanent tooth with a favorable prognosis. Teeth such as premolars are often considered ideal.
- **Surgical planning:** Plan the intervention in detail, considering the future position of the tooth, root dimensions, and the possibility of any complications.
- **Surgical technique:** Use a gentle surgical technique to minimize trauma to surrounding tissues. It is important to preserve the PDL and soft tissues during the extraction of the donor tooth.
- **Timing:** Minimize the ischemic time (the period during which the tooth lacks vascularization) by keeping the donor tooth in a culture solution or an appropriate medium until the time of transplantation.
- **Minimal manipulation:** Avoid excessive manipulation of the donor tooth or exposing it to contamination during its retrieval and transplantation.
- **Stabilization:** Encourage the stability of the autotransplanted tooth by using appropriate fixation techniques, such as splinting, during the healing period.
- **Postoperative management:** Provide clear instructions for postoperative care and monitor the patient for any signs of complications, such as infections or rejection.
- **Regular follow-up:** Conduct regular checkups to monitor the healing of the transplanted tooth, the integrity of the PDL, and the surrounding bone health.
- **Patient education:** Educate the patient about the importance of good oral hygiene and dietary restrictions post-surgery to promote proper healing.
- **Multidisciplinary collaboration:** Consider collaborating with orthodontists or maxillofacial surgeons when necessary to achieve optimal results.

In conclusion, dental autotransplantation offers significant benefits, especially in the pediatric and adolescent populations, but more extensive studies are needed to solidify its position as a go-to treatment in cases of trauma-related tooth loss.

#### Authors' Contributions

F.G. was responsible for conceptualization, methodology, and writing—original draft preparation. N.M.J., L.F., L.S.D., and G.C. contributed to writing—review and editing. A.R.G., L.F., and C.G. contributed to visualization. F.R.-V., F.D.A., and C.G. supervised the study. C.G. was responsible for project administration. All the authors read and approved the final version of the manuscript.

#### Data Availability Statement

Data are available on request from the corresponding author.

#### Funding

None.

#### Conflict of Interest

None declared.

#### References

- 1 Nimčenko T, Omerca G, Varinauskas V, Bramanti E, Signorino F, Ciccù M Tooth auto-transplantation as an alternative treatment option: a literature review. *Dent Res J (Isfahan)* 2013;10(01):1–6
- 2 Kakde K, K R. Tooth autotransplantation as an alternative biological treatment: a literature review. *Cureus* 2022;14(10):e30491
- 3 Hwang LA, Chang CY, Su WC, Chang CW, Huang CY. Rapid prototyping-assisted tooth autotransplantation is associated with a reduced root canal treatment rate: a retrospective cohort study. *BMC Oral Health* 2022;22(01):25
- 4 Martin K, Nathwani S, Bunyan R. Autotransplantation of teeth: an evidence-based approach. *Br Dent J* 2018;224(11):861–864
- 5 Dioguardi M, Quarta C, Sovereto D, et al. Autotransplantation of the third molar: a therapeutic alternative to the rehabilitation of a missing tooth: a scoping review. *Bioengineering (Basel)* 2021;8(09):120
- 6 Peeran SW, Ramalingam K. Periodontal ligament. In: *Essentials of Periodontics and Oral Implantology*. Chennai, India: Saranraj JPS Publication; 2021
- 7 Levi PA Jr, Coleman DK, Jeong YN, Rudy RJ. *Non-Surgical Control of Periodontal Diseases: A Comprehensive Handbook*. 1st ed. Berlin: Springer; 2016
- 8 de Freitas Coutinho NB, Nunes FC, Gagno Intra JB, et al. Success, survival rate, and soft tissue esthetic of tooth autotransplantation. *J Endod* 2021;47(03):391–396
- 9 Strbac GD, Schnappauf A, Giannis K, Bertl MH, Moritz A, Ulm C. Guided autotransplantation of teeth: a novel method using virtually planned 3-dimensional templates. *J Endod* 2016;42(12):1844–1850
- 10 Tankittiwat P, Thittiwong R, Limmonthol S, et al. Mandibular premolar transplantation to replace missing maxillary anterior teeth: a multidisciplinary approach. *Am J Orthod Dentofacial Orthop* 2021;160(03):459–472
- 11 Abella Sans F, Suresh N, Dummer PMH, Garcia-Font M, Gómez-Rojas A, Nagendrababu V. Guided autotransplantation of an immature premolar to the maxillary incisor region with immediate restoration of esthetics: a case report. *J Endod* 2024;50(02):252–257
- 12 Veloza C, Nogueira LR, Nogueira Filho LR, Capistrano A, de Albuquerque DS. Tooth autotransplantation using an interdisciplinary approach to rehabilitation in a young patient: case report with 7-year follow-up. *Dent Traumatol* 2021;37(03):521–530
- 13 Cunha DL, Masioli MA, Intra JBG, Roldi A, Dardengo CdeS, Miguel JA. Premolar transplantation to replace a missing central incisor. *Am J Orthod Dentofacial Orthop* 2015;147(03):394–401
- 14 Berlin-Broner Y, Torrealba Y, Flores-Mir C, Levin L. Multidisciplinary approach for autotransplantation and restoration of a maxillary premolar into an area of an avulsed anterior tooth: a case report with a 6-year follow-up. *J Endod* 2023;49(05):590–596
- 15 Choi SH, Hwang CJ. Orthognathic treatment with autotransplantation of a third molar. *Am J Orthod Dentofacial Orthop* 2013;144(05):737–747
- 16 Ohga N, Iori T, Sakata K, et al. Immediate oral surgical management of external dental fistula: technical note of immediate tooth autotransplantation. *J Oral Maxillofac Surg Med Pathol* 2021;33(06):623–625
- 17 Al-Khanati NM, Kara Beit Z. Reconsidering some standards in immediate autotransplantation of teeth: case report with 2-year follow-up. *Ann Med Surg (Lond)* 2022;75:103470
- 18 Zufia J, Abella F, Trebol I, Gómez-Meda R. Autotransplantation of mandibular third molar with buccal cortical plate to replace vertically fractured mandibular second molar: a novel technique. *J Endod* 2017;43(09):1574–1578

- 19 Albaloochy A, Duggal M, Vinall-Collier K, Drummond B, Day P. The outcomes of auto-transplanted premolars in the anterior maxilla following traumatic dental injuries. *Dent Traumatol* 2023;39 (Suppl 1):40–49
- 20 Peña-Cardelles JF, Ortega-Concepción D, Moreno-Perez J, et al. Third molar autotransplant planning with a tooth replica. A year of follow-up case report. *J Clin Exp Dent* 2021;13(01):e75–e80
- 21 Singh AK, Khanal N, Acharya N, Hasan MR, Saito T. What are the complications, success and survival rates for autotransplanted teeth? An overview of systematic reviews and meta-analyses. *Healthcare (Basel)* 2022;10(05):835
- 22 Plakwicz P, Czochrowska EM, Milczarek A, Zadurska M. Vertical bone growth following autotransplantation of the developing maxillary third molar to replace a retained mandibular permanent molar: a case report. *Int J Periodont Restor Dent* 2014;34 (05):667–671
- 23 Pera F, Carossa M, Bagnasco F, et al. Comparison between bone-level and tissue-level implants in immediate-loading full-arch rehabilitations: a retrospective multi-center 1-year follow-up study. *Prosthesis* 2023;5(04):1301–1311
- 24 Maddalone M, Bianco E, Spolnik KJ, Mirabelli L, Gagliani M, Fabbro MD. Immediate autotransplantation of molars with closed apex. *J Contemp Dent Pract* 2022;23(04):453–459
- 25 Isa-Kara M, Sari F, Emre-Coşkun M, et al. Stabilization of auto-transplanted teeth using thermoplastic retainers. *Med Oral Patol Oral Cir Bucal* 2011;16(03):e369–e375
- 26 Howe MS, Keys W, Richards D. Long-term (10-year) dental implant survival: a systematic review and sensitivity meta-analysis. *J Dent* 2019;84:9–21
- 27 Reddy N, Vempalli S, Prakash J, et al. Evaluation of the effect of digital dentistry on the accuracy of implant placement and prosthesis fabrication—a systematic review and meta-analysis. *Prosthesis* 2023;5(03):666–677
- 28 Soegiantho P, Suryawinata PG, Tran W, et al. Survival of single immediate implants and reasons for loss: a systematic review. *Prosthesis* 2023;5(02):378–424