

# Lasso Technique for Retrieval of a Dislocated and Impacted Esophageal Stent

# UCTN

With the advent of self-expanding metal stents, esophageal stent insertion has become a relatively simple method of relieving dysphagia due to esophageal cancer. However, stent migration is a well-recognized complication. If dislocation occurs, endoscopic retrieval using a forceps and/or polypectomy snare is usually possible [1]. To use these techniques, at least one end of the stent has to be accessible to the snare.

In the case of distally migrated biliary endoprotheses with impaction into the duodenal wall, a method known as the “lasso technique” has been shown to be a successful way of removing the endoprotheses [2–4]. This technique has also been used to remove a migrated colonic stent [5].

In a 51-year-old woman with advanced distal esophageal carcinoma, a self-expanding metal stent was inserted endoscopically to relieve dysphagia. However, 1 day after implantation, the stent was found to have dislocated into the stomach. Both ends of the stent had become

impacted in the gastric wall, so that stent extraction with a snare or balloon was not possible (Figure 1). Using the lasso technique, a standard guide wire and a snare were advanced through each of the working channels of a double-lumen gastro-scope (Pentax EG-3840TK). The guide wire was advanced until it passed above the middle portion of the stent and was grasped by the snare, which was advanced below. After closure of the snare, the distal part of the guide wire was extracted through the endoscope’s working channel. With traction being applied to both ends of the guide wire, the esophageal stent was drawn up to the tip of the endoscope (Figure 2) and removed by extracting the endoscope. By both collapsing and bending the stent at its midpoint, the sharp barbs at the end of the stent were directed away from the gastric and esophageal mucosa, thus minimizing injury during stent extraction. A second self-expanding metal stent was inserted in the same session, without any complications.

The lasso technique is thus a simple and safe method of extracting esophageal metal stents in the rare cases in which stent dislocation into the stomach occurs, with impaction of both ends of the stent into the gastric wall.

**U. Weickert, R. Jakobs, E. Siegel, D. Schilling, J. F. Riemann**

Dept. of Medicine C (Gastroenterology, Hepatology and Diabetology), Ludwigshafen City Hospital (University of Mainz), Ludwigshafen, Germany.

## References

- 1 May A, Gossner L, Feess G et al. Extraction of migrated selfexpanding esophageal metal stents. *Gastrointest Endosc* 1999; 49: 524–527
- 2 Mergener K, Baillie J. Retrieval of distally migrated, impacted biliary endoprotheses using a novel guidewire/basket “lasso” technique. *Gastrointest Endosc* 1999; 50: 93–95
- 3 Schutz SM, Chinae C, Friedrichs P. Successful endoscopic removal of a severed, impacted Dormia basket. *Am J Gastroenterol* 1997; 92: 679–681
- 4 Smith FCT, O’Connor HJ, Downing R. An endoscopic technique for stent recovery used after duodenal perforation by a biliary stent. *Endoscopy* 1991; 23: 244–245
- 5 Stone CD, Lichtenstein DR. A novel technique for endoscopic removal of a migrated colonic stent. *Gastrointest Endosc* 2001; 54: 522–524

## Corresponding Author

**R. Jakobs, M. D.**

Medizinische Klinik C  
Klinikum der Stadt Ludwigshafen  
Bremsersstraße 79  
67063 Ludwigshafen  
Germany

Fax: +49-621-5034112

E-mail: jakobsr@klilu.de

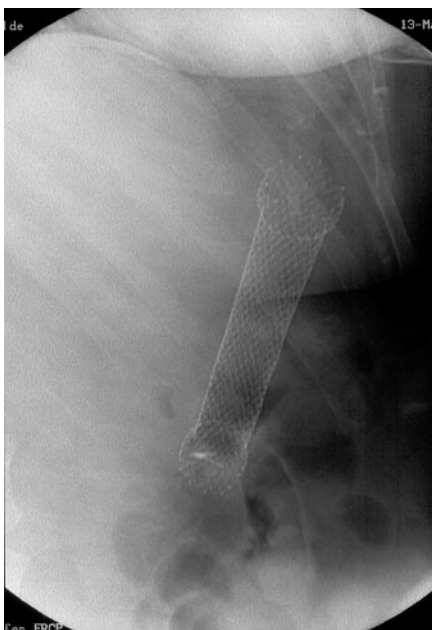


Figure 1 The distally migrated esophageal metal stent.

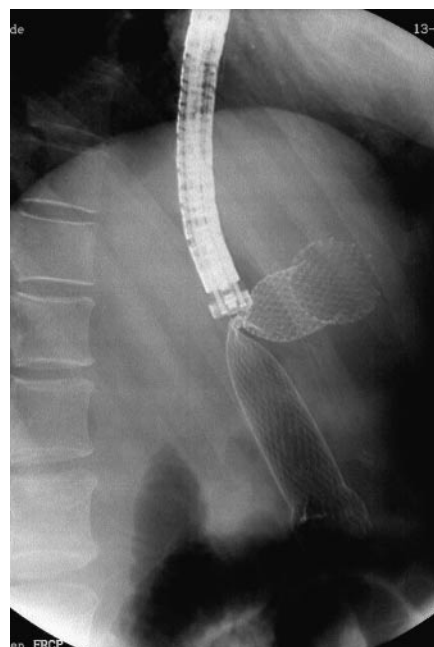


Figure 2 Extraction of the stent using the lasso technique.