

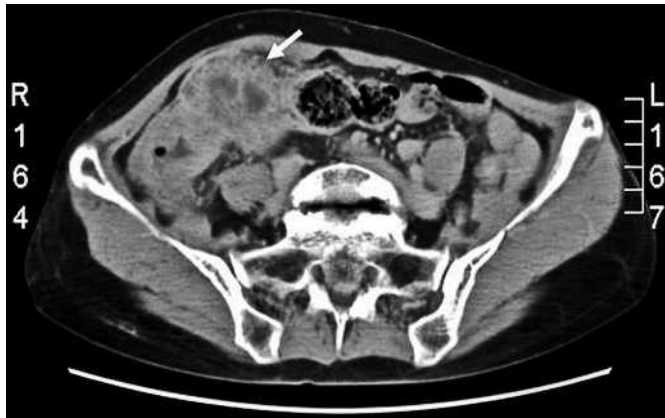

Figure 1 Contrast-enhanced abdominal computed tomography, showing cecal wall thickening and an ill-defined pericecal mass lesion with marginal enhancement (arrow).

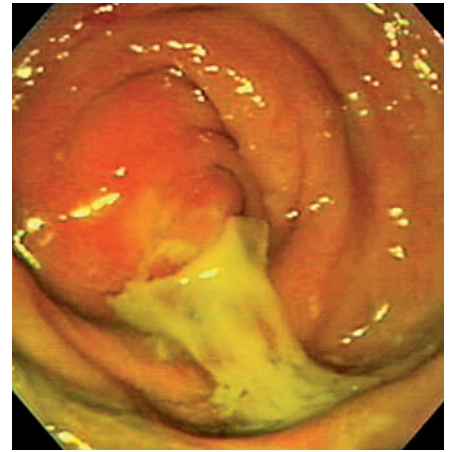


Figure 2 Colonoscopic image showing mucosal bulging, edema, and hyperemia at the appendiceal orifice, with a spontaneous discharge of pus.

A 65-year-old woman presented with intermittent right lower quadrant pain that had persisted for more than 2 weeks. The pain was described as cramping, and was unrelated to food intake or defecation. Five days before admission, a tender mass had become palpable over the right lower quadrant. There had been no fever episodes before she came to the hospital. The physical examination was unremarkable except for a palpable, tender mass over the ileocecal area. The laboratory data were within reference ranges, except for a white blood cell count of  $11700/\text{mm}^3$  (normal:  $4500-10000/\text{mm}^3$ ). Tumor markers, including carcinoembryonic antigen, CA199, and CA125, were normal. Abdominal ultrasonography revealed a heterogeneous mass lesion over the right lower quadrant. Contrast-enhanced computed tomography (CT) showed cecal wall thickening and an ill-defined pericecal mass lesion with marginal enhancement (Figure 1). Because a cecal tumor could not be excluded, colonoscopy was performed, demonstrating mucosal bulging, edema, and hyperemia, with a spontaneous discharge of pus at the appendiceal orifice (Figure 2). A diagnosis of appendicitis with abscess formation was made. Conservative treatment with intravenous antibiotics was administered, and the abdominal mass was not palpable 2 weeks later. The clinical course was uneventful, and the patient remained asymptomatic during the ensuing 3-month follow-up period.

Acute appendicitis is the clinical diagnosis of an inflammatory reaction in the appendix, relying on a detailed history and physical examination. However, up to one-third of patients suspected of having acute appendicitis may present with atypical clinical findings [1]. In addition, 2–6% of the patients may present with a palpable mass [2]. With a concern about possible cecal malignancy, surgeons may be faced with a dilemma when deciding on the appropriate form of management. CT and transabdominal ultrasonography have been reported to demonstrate excellent accuracy in the diagnosis of suspected appendicitis [3]; however, cecal carcinoma may present as a pericecal inflammatory mass, due to a perforation [4]. Colonoscopy therefore appears to be helpful for diagnosing appendicitis when imaging studies are nondiagnostic. With regard to the treatment of appendicitis with abscess formation, a conservative approach with routine follow-up has been recommended [5]. Appendectomy is suggested only when symptoms recur.

Endoscopy\_UCTN\_Code\_CCL\_1AD\_2AG  
Endoscopy\_UCTN\_Code\_CCL\_1AD\_2AD

**S. L. Yan<sup>1</sup>, Y. T. Liu<sup>1</sup>, D. A. Chou<sup>2</sup>**

<sup>1</sup> Division of Gastroenterology, Dept. of Internal Medicine, Show Chwan Memorial Hospital, Changhua, Taiwan

<sup>2</sup> Division of General Surgery, Dept. of Surgery, Show Chwan Memorial Hospital, Changhua, Taiwan.

## References

- Berry J Jr, Malt RA. Appendicitis near its centenary. *Ann Surg* 1984; 200: 567–575
- Hoffmann J. Contemporary management of appendiceal mass. *Br J Surg* 1993; 80: 1350
- Horton MD, Counter SF, Florence MG, Hart MJ. A prospective trial of computed tomography and ultrasonography for diagnosing appendicitis in the atypical patient. *Am J Surg* 2000; 179: 379–381
- Poon RT, Chu KW. Inflammatory cecal masses in patients presenting with appendicitis. *World J Surg* 1999; 23: 713–716
- Tingstedt B, Bexe-Lindskog E, Ekelund M, Andersson R. Management of appendiceal masses. *Eur J Surg* 2002; 168: 579–582

## Corresponding author

**D. A. Chou, M. D.**

Division of General Surgery,  
Dept. of Surgery  
Show Chwan Memorial Hospital  
542 Chung-Shan Road, Section 1  
Changhua 500  
Taiwan

Fax: +886-4-7233190

Email: yslscsmc@hotmail.com

DOI: 10.1055/s-2006-944919