
Application of Clips During ERCP: A New Anchoring Method for Redundant Kerckring's Fold Covering the Duodenal Papilla

During endoscopic retrograde cholangiopancreatography (ERCP), cannulation is more difficult in patients with anatomical variations, papillary stenosis, impacted stone in the papilla, papillary cancer, peripapillary diverticulum, postoperative states such as those after Billroth II or Braun operations, or redundant Kerck-

ring's fold of the duodenum covering the duodenal papilla. Sometimes the grasp forceps can be used for cannulation in patients with redundant Kerckring's folds, as well as peripapillary diverticulum (1), by pushing the duodenal papilla caudally. However, this method is inappropriate for situations of endoscopic sphincterotomy

(EST). A redundant Kerckring's fold in the duodenum covering the duodenal papilla makes it difficult to perform EST and achieve cannulation during ERCP, because the duodenal papilla cannot be properly exposed, and the risk of duodenal mucosal injury or perforation is increased at the redundant portion during EST. We have

therefore used a new technique with the application of clips to expose the duodenal papilla properly during ERCP in a patient with a redundant Kerckring's fold of the duodenum and a common bile duct stone.

A 76-year-old Korean woman was admitted with acute onset of right upper quadrant abdominal pain, and was found to have gallstone pancreatitis. She had a mild fever (37.8 °C), leukocytosis (13 500/mm³) and hyperamylasemia (356 U/l). Abdominal ultrasonography revealed a common bile duct stone. During the duodenoscopic procedure, the duodenal papilla could not be easily located due to a redundant Kerckring's fold in the duodenum (Figure 1). The duodenal papilla was hidden underneath the Kerckring's fold, which was too redundant to expose. Cannulation was attempted several times with the cannula and the pull-type papillotome, but was unsuccessful. We decided to use clips to anchor the redundant Kerckring's fold covering the duodenal papilla to the duodenal mucosa in a cephalad direction. Through the working channel of the duodenoscope (Olympus JF-200), two clips (Hemoclip, Olympus clip MD-850) were applied with the clip-fixing device (Olympus HX-5 LR). After application of the clips, the duodenal papilla was well exposed in a good position for proper cannulation. In this setting, ERCP was easily performed with the standard cannula (Figure 2). After EST with the pull-type papillotome, the common bile duct stone was successfully removed with a Dormia basket.

*W. Y. Bae, B. M. Yoo, K. J. Lee, Y. S. Kim,
K. B. Hahm, J. H. Kim, S. W. Cho*
Dept. of Gastroenterology,
Ajou University School of Medicine,
Suwon, Korea

Reference

1. Boyer J. Duodenal diverticula and ERCP: a new trick. *Endoscopy* 1996; 28: 326.

Corresponding Author

J. H. Kim, M. D.
Dept. of Gastroenterology
Ajou University School of Medicine
5 Wonchon-dong
Palda1-ku
Suwon 442-749
Korea
Fax: + 82-331-219-5999

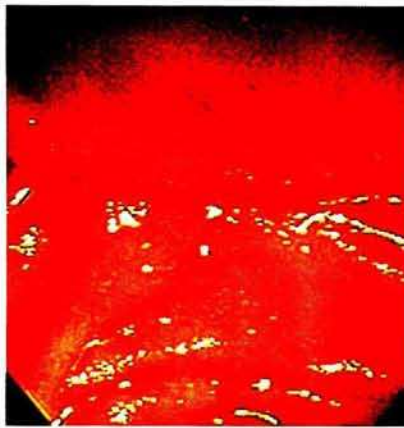


Figure 1: The duodenal papilla was not exposed, due to coverage by a redundant Kerckring's fold.

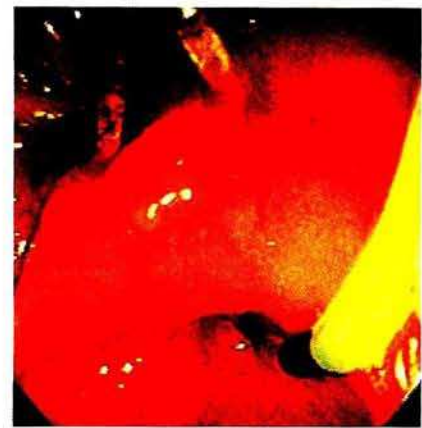

Figure 2: Cannulation was easily performed after the duodenal papilla had been exposed by anchoring the redundant Kerckring's fold to the duodenal mucosa cephalad with two clips.