

Poly-*N*-Acetyl Glucosamine: Will It Replace Cyanoacrylate for Treatment of Gastric Varices? A Pilot Study in a Rabbit Model

Bleeding from gastric varices continues to be a difficult clinical problem. Endoscopic cyanoacrylate injection has been reported to be an effective treatment, but it is cumbersome to perform, and may cause embolism (1). Poly-*N*-acetyl glucosamine (p-GlcNac), a polysaccharide polymer originating from marine microalgae (2,3), has demonstrated rapid and effective hemostasis by stimulating erythrocyte aggregation. P-GlcNac can be formulated as a sterile fully biocompatible gel. We hypothesize that it may be effective for obliterating veins.

Using a 23-gauge needle, 0.3 ml hydrated 4% p-GlcNac gel was injected into both lateral ear veins of six rabbits (New Zealand white rabbits). Two animals were sacrificed at one hour, two at one week, and two at two weeks after injection. Histological specimens were obtained from the injection sites and stained with hematoxylin and eosin.

One hour after p-GlcNac injection, histology demonstrated an occlusion of the vein by a mixture of p-GlcNac gel and erythrocytes in four out of four specimens (Figure 1). After one week, there was an invasion of inflammatory cells into the vessel lumen in four out of four specimens (Figure 2). Eventually, after two weeks, the vein was completely replaced by connective tissue in three out of four specimens (Figure 3).

In summary, intravenous injection of poly-*N*-acetyl glucosamine gel occludes the vein and induces an inflammatory reaction leading to complete replacement of the vessel by connective tissue. These results suggest that p-GlcNac has a potential to induce hemostasis in variceal bleeding, and ultimately to cause obliteration of the vein. P-GlcNac may serve as a better alternative to superglue. Endoscopic injection of this

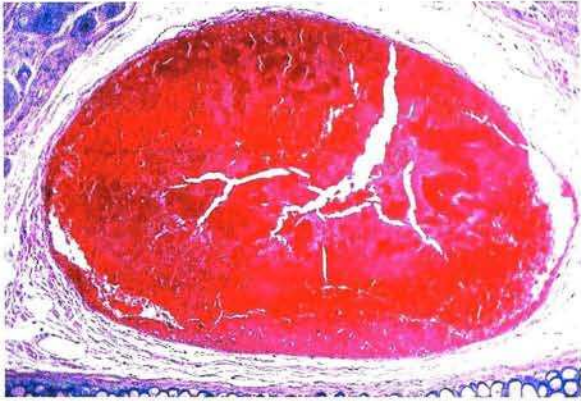


Figure 1: One hour after p-GlcNac injection (hematoxylin-eosin, original magnification x 100).

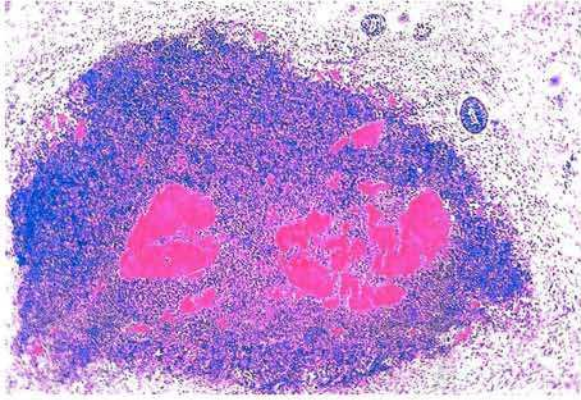


Figure 2: One week after p-GlcNac injection (hematoxylin-eosin, original magnification x 100).

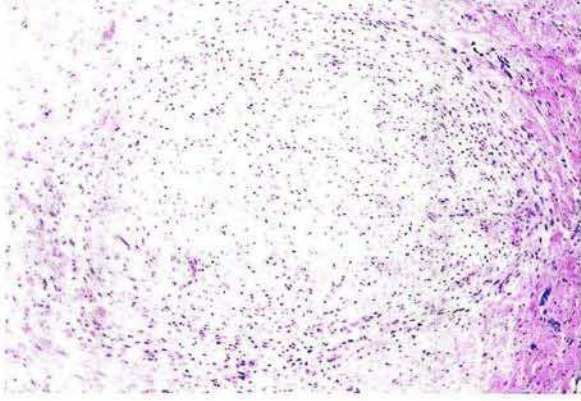


Figure 3: Two weeks after p-GlcNac injection (hematoxylin-eosin, original magnification x 100).

promising substance in the canine portal hypertension model is now being studied.

Acknowledgement

This study was supported by Marine Polymer Technologies (Danvers, Massachusetts, USA).

*D. Kulling*¹, *S. Woo*², *M. V. Demcheva*²,
*R. H. Hawes*¹, *J. N. Vournakis*²

¹ Digestive Disease Center

² Center for Molecular and Structural Biology, Medical University of South Carolina, Charleston, South Carolina, USA

References

1. Soehendra N, Grimm H, Nam VC, Berger B. *N*-butyl-2-cyanoacrylate: a supplement to endoscopic sclerotherapy. *Endoscopy* 1987, 19: 221–4.
2. Vournakis JN, Finkielstein S, Pariser ER, Helton M. Poly-B-1-4-*N*-acetylglucosamine. US Patent 5,623,064. 22 April 1997.
3. Cole DJ, Gattoni S, McClay EF et al. Characterization of a sustained-release delivery system for combined cytokine/peptide vaccination using a poly-*N*-acetyl glucosamine-based polymer matrix. *Clin Cancer Res* 1997; 3: 867–73.

Corresponding Author

D. Kulling, M.D.
Digestive Disease Center
Medical University
of South Carolina
171 Ashley Avenue
Charleston, SC 29425
USA
Fax: +1-803-792-4184