

Severe esophageal burn after transesophageal pacing

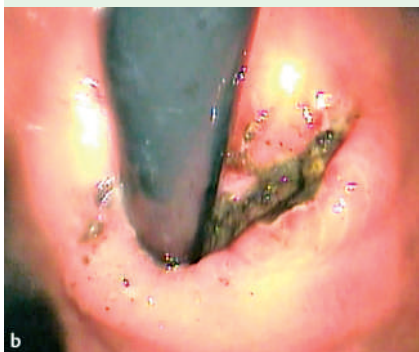
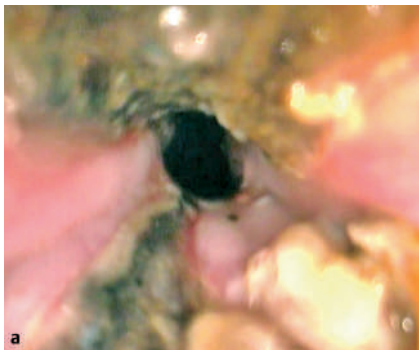
Fig. 1 Endoscopic views of the tissue necrosis in the esophagus (a), reaching down into the cardia (b), 6 hours after pacing.

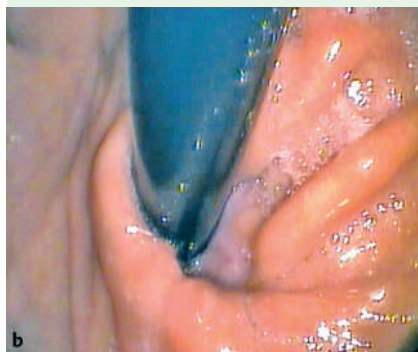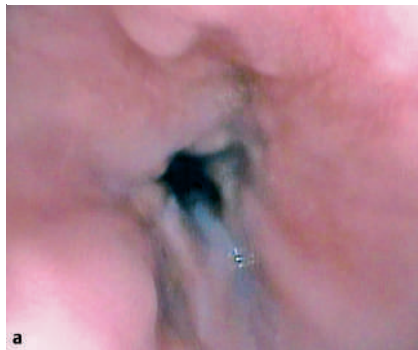


Fig. 2 Endoscopic views of the esophageal lesions (a) and the cardiac lesions (b), 6 weeks after the initial pacing-related electrical burn.

A 13-year-old girl with tachycardia and a 3-week history of fatigue and headaches was admitted with suspected myocarditis. Echocardiography showed a dilated left ventricle with a shortening fraction of 12%. Electrocardiography revealed ectopic atrial tachycardia, with a heart rate of 200 beats per minute. Cardioversion was performed to terminate the tachycardia, but this was unsuccessful. Intravenous amiodarone was started, but within hours the girl had deteriorated. Verapamil and beta blockers were not suitable because of their negative inotropic effects, and so a transesophageal electrode catheter was placed under fluoroscopic guidance. Rapid atrial pacing (320/minute, 20 mA) resulted in atrioventricular block and the ventricular rate fell to 160 beats per minute. The amiodarone treatment was continued and sinus rhythm was achieved after 18 hours, when atrial pacing was stopped.

Esophagogastroduodenoscopy was performed 6 hours after the transesophageal pacing was stopped: areas of deep tissue

necrosis, reaching into stomach, were found in the distal anterior and posterior esophageal wall (● Fig. 1). Less severe but circumferential burns affecting the superficial mucosa were found in the entire distal part of the esophagus. Antibiotic therapy and a 2-week course of prednisolone were initiated. The girl recovered over the following weeks and was able to swallow clear liquids and then solids without difficulty. Six weeks later, esophagogastroduodenoscopy showed no esophageal strictures, revealing only well-healed, scarred lesions, without narrowing of the lumen (● Fig. 2). Her myocardial function had completely normalized.

The distal esophagus lies in direct contact with the left atrium and it is therefore used for transesophageal pacing in severe arrhythmias. In adult studies only minimal esophageal injury was reported in a couple of patients after short-term stimulation [1]. In animal studies, transesophageal pacing of 30-minute duration, 2 msec, and 75–100 mA produced minor

lesions, but longer pacing times may cause lesions at currents of less than 40 mA [2].

Transesophageal pacing can be a life-saving procedure but it has to be kept in mind that prolonged stimulation carries a risk of significant esophageal injury, and follow-up endoscopy should be considered.

Endoscopy_UCTN_Code_CPL_1AH_2AK

H. Köhler¹, S. Zink², J. Scharf³, A. Koch²

¹ Division of Gastroenterology, Kinder- und Jugendklinik, Universitätsklinikum Erlangen, Erlangen, Germany

² Department of Cardiology, Kinder- und Jugendklinik, Universitätsklinikum Erlangen, Erlangen, Germany

³ Intensive Care Unit, Kinder- und Jugendklinik, Universitätsklinikum Erlangen, Erlangen, Germany

References

- 1 Santini M, Pandozi C, Colivicchi F et al. Transesophageal low-energy cardioversion of atrial fibrillation: results with the oesophageal-right atrial lead configuration. *Eur Heart J* 2000; 21: 848–855
- 2 Arzbaecher R, Jenkins JM. A review of the theoretical and experimental bases of transesophageal atrial pacing. *J Electrocardiol* 2002; 35 (Suppl): 137–141

Bibliography

DOI 10.1055/s-2007-966611

Endoscopy 2007; 39: E300

© Georg Thieme Verlag KG Stuttgart · New York · ISSN 0013-726X

Corresponding author

H. Köhler, MD

Kinder- und Jugendklinik
Universitätsklinikum Erlangen
Loschgestraße 15
91054 Erlangen
Germany

Fax: +49-9131-85-33113

henrik.koehler@kinder.imed.uni-erlangen.de