

An Unusual Complication of Surgery for Type A Dissection Treated by Thoracic Endovascular Aortic Repair

Giuseppe Petrilli, MD^{1*}, Giovanni Puppini, MD², Salvo Torre, MD¹, Daniele Calzaferri, MD¹, Antonella Bugana, MD¹, Giuseppe Faggian¹

¹Division of Cardiac Surgery, University of Verona, Verona, Italy; ²Department of Radiology, University of Verona, Verona, Italy

Abstract

A 58-year-old man was admitted to our hospital for massive swelling in an anterior cervical location. Nine years earlier, he underwent surgical repair of a complex type A aortic dissection. This procedure was complicated by a fistula between the anastomosis of the graft and the descending aorta, resulting in massive presternal swelling. Therefore, we performed thoracic endovascular repair with successful sealing of the prosthetic leak, achieving progressive reduction in the collection of fluid. We propose thoracic endovascular aortic repair as an alternative to open surgical repair for the treatment of complicated cases.

Copyright © 2013 Science International Corp.

Key Words

Emergency TEVAR · Periprosthetic leak · Presternal swelling

Introduction

Open thoracic or thoracoabdominal aortic repair carries a significant risk of mortality and morbidity, despite recent literature suggesting a significant improvement [1]. Thoracic endovascular aortic repair (TEVAR) offers the possibility of treating patients who are not candidates, or those who are at extremely high risk for conventional surgical procedures because of their existing comorbidities and has gained increased acceptance across the world, with excellent

short-term results [2]. Utilizing this therapeutic strategy, we report our successful management of a patient who suffered complications after a cardiovascular operation.

Clinical Case

In 2003, a 58-year-old man was admitted to another institution for a type B aortic dissection treated with medical management. After two days, the patient underwent surgical repair because of retrograde intramural hematoma extending to the ascending aorta as shown by computed tomography (CT). In the theater a 26 mm vascular prosthesis was placed extending from the sinotubular junction (STJ) to the aortic arch immediately distal to the origin of left subclavian artery, with direct reimplantation of the epi-aortic vessels. This graft was connected to the descending aorta with another 20 mm vascular prosthesis, anastomosed end-to-side from the neo-ascending aorta to the descending thoracic aorta. This procedure was performed at another surgical institution and is comparable to a technique described by Grieppe et al. [3].

Circulatory arrest duration was two hours with anterograde cerebral perfusion from the right axillary artery. This procedure was complicated by right hemiplegia, probably due to cerebral malperfusion. CT of the brain demonstrated extensive bilateral ischemic



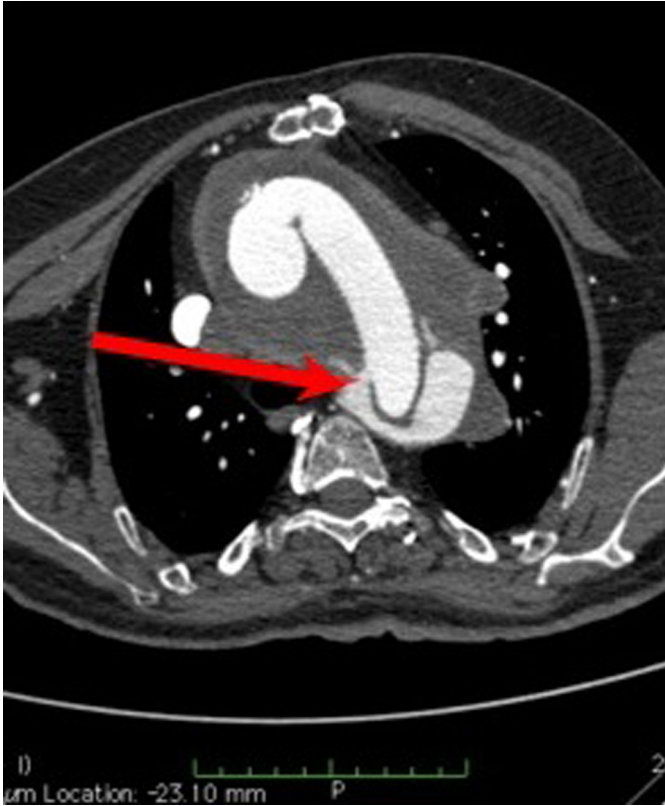

Figure 1. CT shows the periprosthetic fistula, as indicated by the red arrow.

cerebral lesions and evoked potentials showed a left decortication pattern.

Last February, the patient was admitted to our hospital due to the appearance of massive presternal swelling. The patient had a medical history that included hypertension and peripheral vascular disease. He was hemiplegic with cognitive impairment. A CT scan showed the presence of a fistula from the end-to-side anastomosis, connecting the graft to the descending aorta (Fig. 1). The lesion resulted in a voluminous collection of fluid extending from the periaortic to the subcutaneous presternal regions (Latero-lateral (LL) \times Cranio-caudal (CC) \times Postero-anterior (PA) = 8 cm \times 10 cm \times 7 cm), crossing the diastasis of the manubrium (Fig. 2).

Therefore, the patient was transferred to the operating room where endovascular repair was performed under general anesthesia. A standard cut-down over the left femoral artery was performed and percutaneous right axillary access was achieved. Systemic heparin (100 mg) was then administered. A 28/200/24 mm Relay plus (Bolton Medical, Barcelona, Spain) stent-graft was advanced over a stiff wire and navigated in the true lumen under fluoroscopic guidance. The stent-graft was successfully placed from the previous vascular graft to about halfway down the descending thoracic aorta and the anastomosis originating the leakage was excluded. At the end of the delivery there

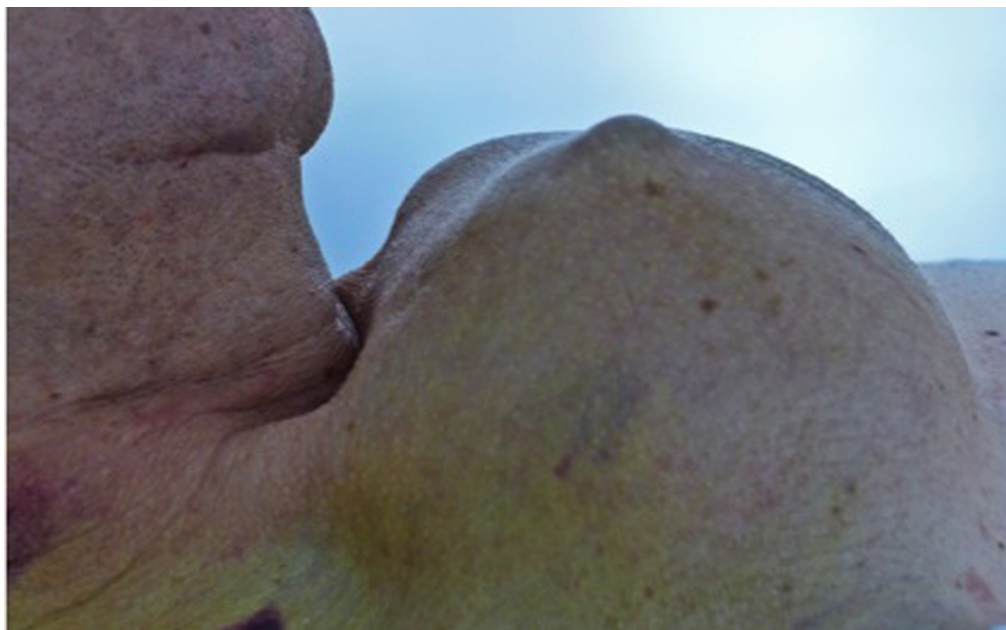


Figure 2. Presternal swelling.

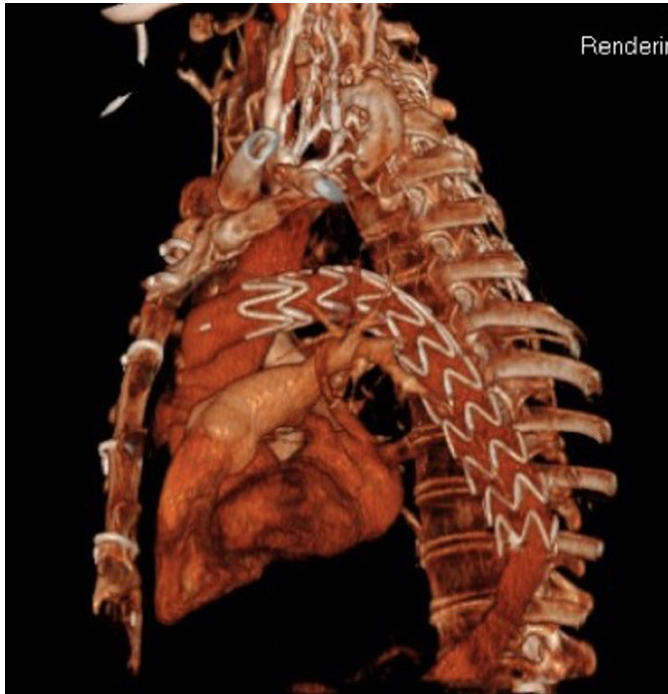

Figure 3. Endoprosthesis in situ.

was evidence of minimum type 1 endoleak, sealed by postdilatation of the endoprosthesis with a 27 mm balloon. Aortography demonstrated a satisfactory result. The patient's condition improved and he was discharged 5 days after surgery.

At one month postsurgery a 3D CT scan image showed the successful sealing of the endoleak (Fig. 3) and at three months, reduction of the hematoma (Fig. 4) was evident.

Discussion

Acute aortic dissection of the descending aorta is still a life-threatening condition with high mortality and morbidity. Currently, there is consensus that acute uncomplicated type B dissections are managed medically. Conventional resection and graft replacement of the descending thoracic aorta has been the preferred method of treatment only in cases with complications such as aortic rupture, malperfusion of end organs, and/or persistent pain despite medical treatment. Open repair carries a 2.9% to 7% risk of paraplegia and an operative mortality rate ranging from

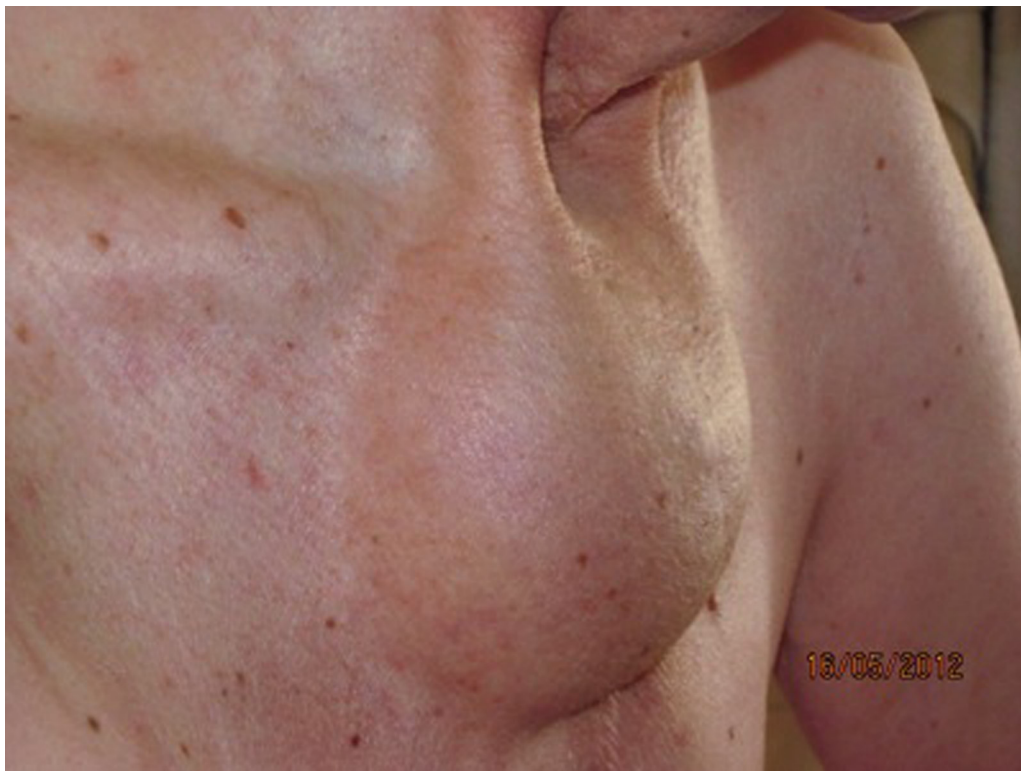

Figure 4. Reduction of presternal swelling after three months.

15% to 23.5%. Nevertheless, the introduction of endovascular stent grafts is revolutionizing the definitive treatment of these injuries. The potential benefits of TEVAR over open repair include no need for thoracotomy or single lung ventilation, decreased use of systemic anticoagulation, avoidance of aortic cross-clamping, less blood loss, less postoperative pain, and a lower paraplegia rate [3]. Indeed, since its introduction more than a decade ago, TEVAR has shown promising results for patients with various thoracic aortic diseases [4]. These include unstable acute type B aortic dissection, chronic type B aortic dissection, and type B dissection with retrograde extension into the ascending aorta [5]. The concept of this procedure was directed toward sealing the proximal intimal tear, redirecting the flow into the true lumen, and promoting depressurization and thrombosis of the false lumen. In addition, such an approach can effectively treat malp-

perfusion syndrome by re-establishing side branch flow in dynamic obstruction [2].

In accordance with this, we adopted TEVAR to repair a dehiscence of an anastomosis between the transverse prosthesis and the descending aorta. The patient's condition has improved considerably and, after three months, the severe subcutaneous and intrathoracic collection of fluid has been considerably reduced.

A surgical alternative would have resulted in a complex reoperation with circulatory arrest to repair the leak, thus exposing the patient to the risk of new complications, especially neurological.

In conclusion, TEVAR is a reliable and flexible method that can be extended to complicated patients where an open surgical option presents a prohibitive risk of mortality.

[Comment on this Article or Ask a Question](#)

References

1. Coady MA, Ikonomidis JS, Cheung AT, Matsumoto AH, Chaikof EL, et al. Surgical management of descending thoracic aortic disease: open and endovascular approaches: a scientific statement from the American Heart Association. *Circulation*. 2010;121:2780–2804. 10.1161/CIR.0b013e3181e4d033
2. Ehrlich MP, Rousseau H, Heijmen R, Piquet P, Beregi JP, Nienaber CA, et al. Midterm results after endovascular treatment of acute, complicated type B dissection: the Talent Thoracic Registry. *J Thorac Cardiovasc Surg*. 2012;145:159–165. 10.1016/j.jtcvs.2011.10.093
3. Griep B, EM: Aneurysms of aortic arch, in Edmonds LH, Jr. (ed.): *Cardiac Surgery in the Adult*. New York, McGraw-Hill, 1997; p. 1209.
4. Akin I, Kische S, Ince H, Nienaber CA. Indication, timing and results of endovascular treatment of type B dissection. *Eur J Endovasc Surg*. 2009;37:289–296. 10.1016/j.ejvs.2008.12.004
5. Cao CQ, Bannon PG, Shee R, Yan TD. Thoracic endovascular aortic repair—indications and evidence. *Ann Thorac Cardiovasc Surg*. 2011;17:1–6. 10.5761/atcs.ra.10.01612

Cite this article as: Petrilli G, Puppini G, Torre S, Calzaferrri D, Bugana A, Faggian G. An Unusual Complication of Surgery for Type A Dissection Treated by Thoracic Endovascular Aortic Repair. *Aorta* 2013;1(2):131–134. DOI:<http://dx.doi.org/10.12945/j.aorta.2013.13-011>

EDITOR'S COMMENTS

This case showcases just how dramatic such false aneurysms can become, with a truly massive suprasternal pulsatile mass. This case would have been difficult (although fully possible) to approach by open

surgery, making an endovascular approach attractive. As the offending fistula appears to be a defect in a graft-to-graft anastomosis, the chosen endovascular stent grafting may indeed lead to permanent obliteration of the tract and the false aneurysm.