

# True Aneurysm of the Proximal Brachial Artery

Pinjala Ramakrishna, MS, FRCS Ed, FICS, Sandeep Mahapatra, MS, DNB\*, Ratna Rajesh, MBBS

Department of Vascular Surgery, Nizam's Institute of Medical Sciences, Hyderabad, Andhra Pradesh, India

## Abstract

**A 35-year-old farmer presented with complaints of pain in the right upper limb for 1 month and bluish discoloration of the right-hand finger tips with tingling and numbness. He sustained injury to the right upper limb while lifting a heavy object 1 mo previously. There was an ovoid swelling of 4 × 2 cm on the medial aspect of the right arm, 12 cm above the medial epicondyle at the level of the armpit with visible pulsations. There was distal neurovascular deficit. Duplex scan of the right upper limb arterial system revealed a pseudoaneurysm of the proximal right brachial artery, with dampened monophasic flow in the ulnar artery and no flow in the radial artery. Spiral computed tomography angiogram showed the presence of an echogenic periarterial lesion in the proximal brachial artery suggestive of pseudoaneurysm or an extrinsic compression by hematoma. Distal brachial artery was found to have filled with thrombus, with non-opacification of the radial and the distal ulnar artery. The patient was posted for excision of the aneurysmal arterial segment. A 5-cm-long reversed segment of vein graft was interposed between the cut ends of the brachial artery. Histopathology: Specimen shows a part of the vessel wall composed of intimal, medial, and adventitial layers with intraluminal thrombus showing evidence of recanalization suggestive of true aneurysm of the brachial artery.**

Copyright © 2013 Science International Corp.

## Key Words

Brachial artery · True aneurysm

## Introduction

A 35-year-old farmer presented to the hospital with complaints of pain in the right upper limb for 1

month and difficulty in lifting heavy weights with that arm. He noticed bluish discoloration of the finger tips of the right arm, with tingling and numbness for 2 days. He had sustained an injury to the right upper limb while lifting a heavy object 1 month previously. He is a nondiabetic, normotensive, chronic smoker, consuming 1-2 packs of cigarettes per day for the last 12 years. He was evaluated by his local doctor and found to have right upper limb ischemia.

## Case History

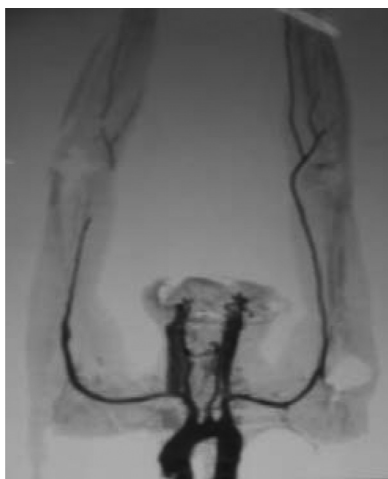### Examination

There was an ovoid 4 × 2 cm swelling on the medial aspect of the right arm, 12 cm above the medial epicondyle, at the level of the armpit, with visible pulsations. Palpation revealed a nontender, pulsatile, nonfluctuant mass, noncompressible, nonreducible, not attached to the overlying skin or underlying muscles or bone. The mass was more mobile in the longitudinal plane than in the transverse plane. There were no palpable axillary or supraclavicular lymph nodes on either side. There was distal neurovascular deficit. No bruit was audible over the swelling. Examination of the precordium revealed no extra heart sounds or murmurs suggestive of valvular heart disease.

### Imaging Studies

Duplex scan of the right upper limb arterial system revealed a pseudoaneurysm of the proximal right brachial artery, with dampened monophasic flow in the ulnar artery and no flow in the radial artery.



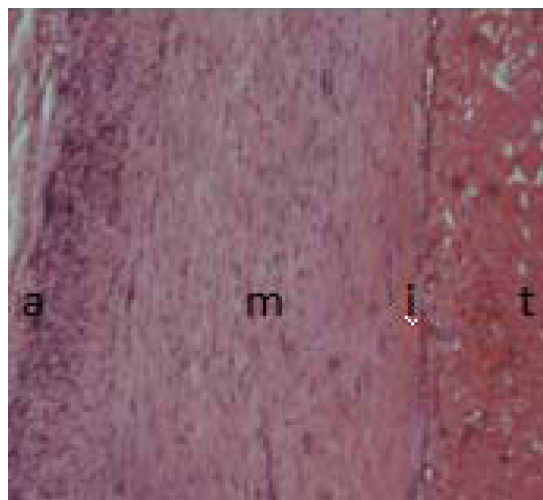


**Figure 1.** Spiral computed tomography angiogram of both the upper limbs. Note defect in right brachial artery.

Spiral CT angiogram (Fig. 1) showed the presence of an echogenic periarterial lesion in the proximal brachial artery suggestive of pseudoaneurysm or an extrinsic compression by hematoma. The distal brachial artery was found to have filled with thrombus with non-opacification of the radial and the distal ulnar artery. The proximal ulnar artery showed patchy contrast uptake.

Segmental blood pressure by hand-held Doppler detected 82 mm Hg pressure in the above-elbow segment of the brachial artery and nondetectable pressure in the below-elbow segment of the artery.

The patient was posted for excision of the aneurysmal arterial segment with interposition vein graft and distal brachial artery embolectomy.

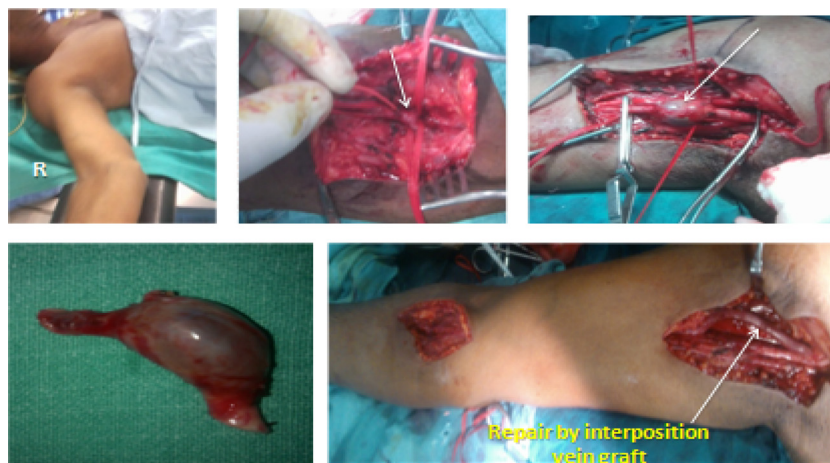

**Figure 3.** Labeled histopathological section showing adventitial layer (a), intimal layer (i), medial layer (m), and intraluminal thrombus (t) showing evidence of recanalization.

*Operative Management*

The patient was placed in the supine position with abducted right upper limb under general anesthesia. A “lazy S” incision was made over the axilla. The aneurysm of the brachial artery was isolated with proximal and distal brachial artery control. The aneurysm was excised. A 5-cm-long reversed segment of vein graft was interposed between the cut ends of the brachial artery (Fig. 2).

The right limb was found to be warm with good capillary filling. The patient had relief of pain and numbness. The radial and ulnar arteries had palpable distal pulses. The biopsy sample revealed true aneu-



**Figure 2.** Perioperative photographs.

rysm of the brachial artery with mural thrombus within.

### Histopathology

Specimen shows a part of the vessel wall composed of intimal, medial, and adventitial layers with intraluminal thrombus, showing evidence of recanalization suggestive of true aneurysm of the brachial artery (Fig. 3).

### Discussion

Brachial artery aneurysms are relatively rare compared to lower extremity aneurysms [1–3]. Most of these are pseudoaneurysms caused by trauma, including iatrogenic trauma, and drug abuse [4,5]. True aneurysms are even rarer entities and can occur in in-

fantile or older age groups [6]. Etiology consists of congenital connective tissue abnormalities, Kawasaki's syndrome, Buerger's disease, or repetitive trauma, and may be idiopathic [4]. Patients can be asymptomatic or present with pulsatile mass or ischemia due to thromboembolic complications (as in our patient) [4]. Distal embolism can occur with transient or minimal ischemic symptoms, or the aneurysm itself can thrombose entirely [7]. The natural history of brachial artery aneurysm is not well defined, and vascular repair is the main treatment option [4,5]. Although endovascular techniques have been used to manage these patients (mainly for pseudoaneurysms), most true brachial artery aneurysm cases have been repaired by open surgery [1,4].

[Comment on this Article or Ask a Question](#)

### References

1. Gray RJ, Stone WM, Fowl RJ, Cherry KJ, Bower TC. Management of true aneurysms distal to the axillary artery. *J Vasc Surg.* 1998;28:606–610. [10.1016/S0741-5214\(98\)70083-7](https://doi.org/10.1016/S0741-5214(98)70083-7)
2. Tetik O, Ozcem B, Calli AO, Gurbuz A. True brachial artery aneurysm. *Tex Heart Inst J.* 2010;37:618–619.
3. Schunn CD, Sullivan TM. Brachial arteriomegaly and true aneurysmal degeneration: case report and literature review. *Vasc Med.* 2002;7:25–27. [10.1191/1358863x02vm411cr](https://doi.org/10.1191/1358863x02vm411cr)
4. Timaran CH. Upper extremity aneurysms. In: Cronenwett JL, Johnston KW eds. *Rutherford's Vascular Surgery*, 7th edition. Philadelphia: Saunders Elsevier, 2010;2138–2139.
5. Hudorović N, Lovričević I, Franjić DB, Brkić P, Tomas D. True aneurysm of brachial artery. *Wien Klin Wochenschr.* 2010;122:588–591. [10.1007/s00508-010-1425-y](https://doi.org/10.1007/s00508-010-1425-y)
6. Bahcivan M, Yuksel A. Idiopathic true brachial artery aneurysm in a nine-month infant. *Interact Cardiovasc Thorac Surg.* 2009;8:162–163.
7. Fann JI, Wyatt J, Frazier RL, Cahill JL. Symptomatic brachial artery aneurysm in a child. *J Pediatr Surg.* 1994;29:1521–1523. [10.1016/0022-3468\(94\)90201-1](https://doi.org/10.1016/0022-3468(94)90201-1)

**Cite this article as:** Ramakrishna P, Mahapatra S, Rajesh R. True Aneurysm of the Proximal Brachial Artery. *Aorta* 2013;1(3):190–192. DOI: <http://dx.doi.org/10.12945/j.aorta.2013.13-016>

### EDITOR'S QUESTIONS:

1. What was it—true or pseudoaneurysm? Why were the imaging studies misleading? Does it really make any difference whether it was true or pseudo?

*It looks like a true aneurysm because there are no signs of infection and anatomically it is affecting all the layers of the arterial wall, without a pseudocapsule and false lumen. The investigations may fail to demonstrate the nature of the aneurysm as true or false when they are small and arising from the medium-size arteries. If we make a diagnosis of a pseudoaneurysm, we try to look for a cause such as mycotic aneurysms secondary to bacterial endocarditis or infection from the adjacent tissues or recent interventions in the*

*neighboring area. The open surgical management of a true aneurysm will include resection of the aneurysm with subsequent interposition vein grafting. However, in the case of a pseudoaneurysm, we have several options for closure of the arterial rent, patch closure, or vein grafting based on the clinical and pathological condition.*

2. Do you think this lesion was caused by the trauma, or was that a red herring?

*According to the information provided by the patient, there was an injury—but it seems that the trauma might have been an incidental finding! In many cases minor trauma may draw one's attention to a lesion such as an aneurysm in the vessels of the extremities.*