

# Mechanism to Valve a Cabrol Fistula for Bleeding Control

John A. Elefteriades

Aortic Institute, Yale University School of Medicine, New Haven, Connecticut

## Key Words

**Aorta · Cabrol fistula**

The Cabrol fistula is an important tool to have in the aortic surgeon's armamentarium. The Cabrol fistula is applied when bleeding from an aortic root reconstruction cannot be controlled by traditional means (suturing, hemostatic agents). The principle of the Cabrol fistula is to return shed arterial blood automatically to the right atrium (or other venous site). Some groups use the Cabrol fistula frequently (Estrera, Department of Cardiothoracic and Vascular Surgery, The University of Texas Medical School at Houston, pers. comm., April 2012) or even uniformly (Sun, Department of Cardiovascular Surgery, Beijing Anzhen Hospital, Beijing Aortic Disease Center, Capital Medical University, pers. comm., October 2012) to avoid even potential bleeding problems. At our institution, we use the Cabrol fistula very selectively, perhaps several times per year.

At times, the Cabrol fistula is immensely effective, converting an unsustainable bleeding situation instantly into a nonevent. The Achilles' heel of this technique, however, is that sometimes there is even more bleeding from the right atrium than there was from the arterial sites, and this bleeding may seep out from the edges of the patch covering the Cabrol fistula.

In several cases over the last 2 years, we have corrected this potential bleeding from the venous end

of the Cabrol fistula by incorporating a valved Contegra graft (Medtronic, Inc., Minneapolis, MN) between the peri-aortic space and the venous outlet. The valve in the Contegra graft permits only unidirectional flow. The result is that all bleeding from the venous side is prevented. The Cabrol space is kept completely dry of blood by unidirectional flow across the valve. We have used the innominate vein for the venous outlet, as this vein is an ideal size and easily accessible and the venous pressure can be controlled by raising the head of the bed. We have been very pleased with this modification of the Cabrol fistula, which we feel makes the use of the Cabrol all benefit with nearly no liability.

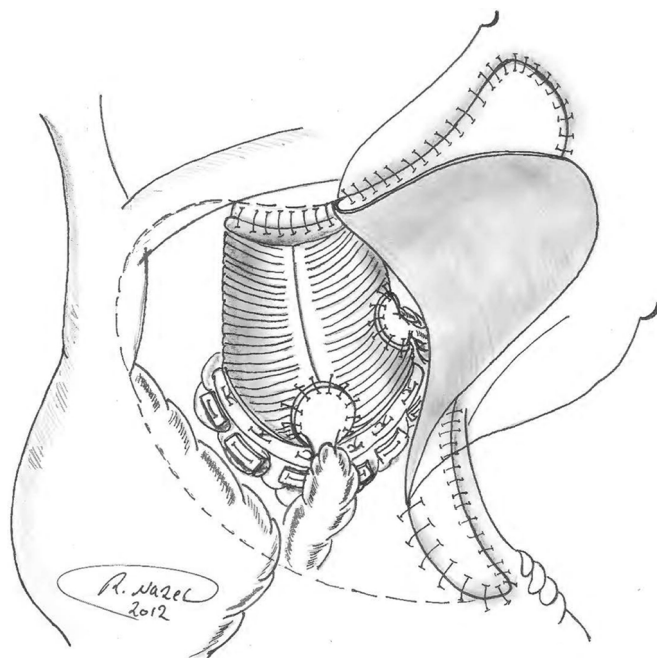
We published this technique recently in the *Annals of Thoracic Surgery* [1].

The key images are reproduced here as well. [Figure 1](#) shows a pericardial patch being sewn to the connective tissues surrounding the region of a composite graft replacement. [Figure 2](#) shows the patch in place and a Contegra graft being sewn to the innominate vein.

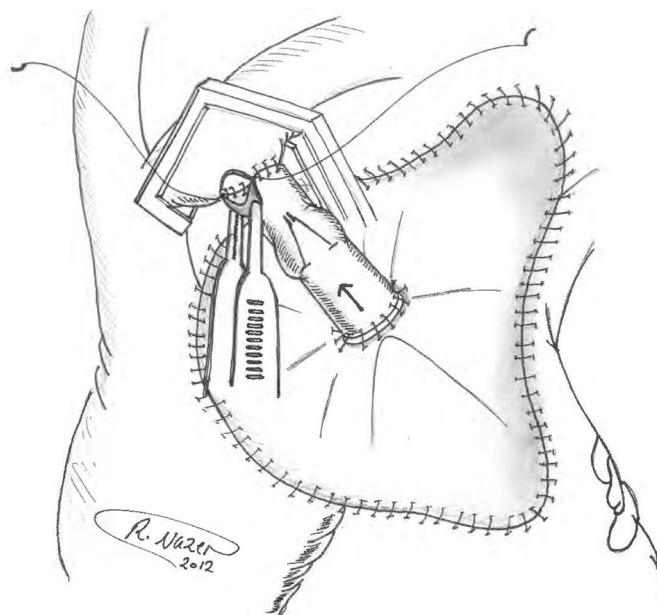
We look forward to submissions from our readers on interesting techniques that they have developed or applied in either open or endovascular procedures.

[Comment on this Article or Ask a Question](#)





**Figure 1.** A pericardial patch being sewn in place over the composite graft repair site (reproduced with permission from [1]).



**Figure 2.** The pericardial patch has been sewn in place. The inflow end of the Contegra valved graft has been anastomosed to the top, center of the pericardial patch. The outflow end of the Contegra graft is being anastomosed to the innominate vein under side-biting control (reproduced with permission from [1]).

## Reference

1. Elefteriades JA, Youssef S, Rousou L, Nazer R. Novel valved graft modification of cabrol fistula for bleeding after aortic root surgery. *Ann Thorac Surg.* 2012;94(5):1741–1743. 10.1016/j.athoracsur.2012.05.114

**Cite this article as:** Elefteriades JA. Mechanism to Valve a Cabrol Fistula for Bleeding Control. *Aorta* 2013;1(1): 65–66. DOI: <http://dx.doi.org/10.12945/j.aorta.2013.13.012>