

Ascending Aortic Repair and Simultaneous Femoro-Femoral Crossover Bypass for Acute DeBakey Type I Dissection with Leg Ischemia

Christian Olsson, MD, PhD*

Department of Molecular Medicine and Surgery, Cardiovascular Surgery Unit, The Karolinska Institute and Karolinska University Hospital, Stockholm, Sweden

Abstract

A 61-year-old man was admitted with acute Type A aortic dissection DeBakey Type I with clinical and radiographic signs of left iliac artery occlusion and leg ischemia. He underwent simultaneous ascending aortic repair and surgical femoro-femoral crossover bypass with immediate restoration of leg perfusion as assessed with peripheral near-infrared spectroscopy. The postoperative course was uneventful. Follow-up computed tomography demonstrated occlusion of the left external iliac artery and patent crossover bypass.

Copyright © 2014 Science International Corp.

Key Words

Aortic dissection · Subclavian artery · Ischemia

Introduction

End-organ malperfusion and ischemia is not uncommon in acute DeBakey Type I dissection. Traditionally, proximal aortic repair has been undertaken first, and remaining end-organ ischemia, if any, has been managed postoperatively. However, if arterial obstruction is judged static, rather than dynamic, and unresolving ischemia is anticipated, it may be justified to address ischemia without delay, i.e., intraoperatively, to mitigate its effects.

Case Presentation

The patient, a previously healthy 61-year-old man, was admitted to another hospital with sudden chest pain and left leg ischemia: pain, numbness, pulselessness and loss of motor control. A computed tomography (CT) scan demonstrated acute aortic dissection Stanford Type A/DeBakey Type I with subtotal occlusion of the right carotid artery (Fig. 1) and left external iliac artery (Fig. 2). Clinically, the dissection was classified as Penn Ab [1]. Suspecting static occlusion, due to local false lumen thrombosis, rather than dynamic occlusion, due to mobile dissection flap, it was decided to address the malperfusion of the left leg directly. At operation, simultaneously with sternotomy and cannulation, a femoro-femoral crossover bypass using an 8-mm Dacron graft was performed (Fig. 3), with immediate restoration of peripheral regional tissue saturation as monitored by near-infrared spectroscopy (INVOSTM, Covidien, Boulder, CO, USA). In addition, a prophylactic three-compartment fasciotomy of the lower leg was carried out. Arterial cannulation was performed in the only nondissected peripheral vessel, the left subclavian artery (Fig. 1), using an 18 French Fem-Flex II (Edwards Lifesciences LLC, Irvine, CA, USA) cannula introduced by modified Seldinger technique [2]. The ascending aortic repair was carried out in a standard fashion, using a supracoronary straight 28-mm tube-graft with a side-arm, a hemiarch



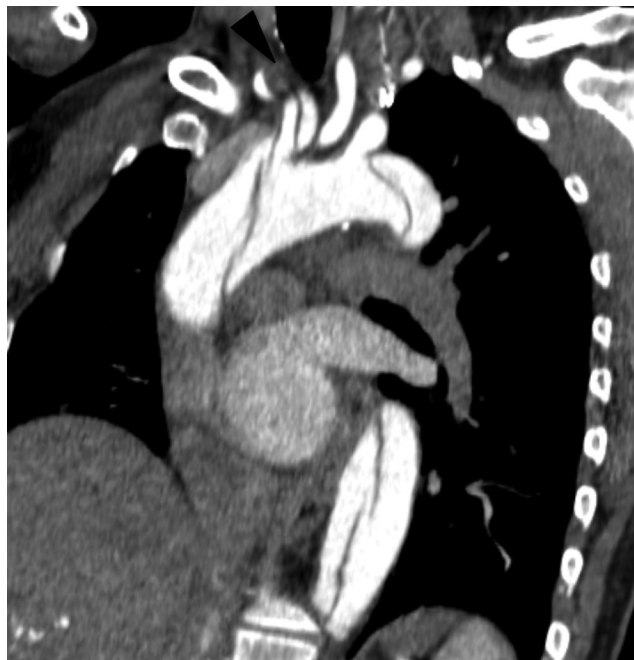

Figure 1. Preoperative computed tomography scan of the aortic arch with intravenous contrast, reformatted image, highlighting subtotal occlusion of right carotid artery compressed by the false lumen (black **arrowhead**). Note left subclavian artery take-off from true lumen.

distal anastomosis during deep hypothermia (18°C), and circulatory arrest followed by side-arm recannulation, reperfusion, and rewarming. Apart from implantation of a permanent pacemaker due to intermittent AV-block, the postoperative course was uneventful. At radiological follow-up three months postoperatively, the ascending aortic repair is satisfactory, the right carotid artery is patent with less false lumen thrombosis, the left external iliac artery remains subtotally occluded (Fig. 4), and the crossover bypass is widely patent with a right-to-left flow verified by duplex sonography.

Discussion

The treatment of leg malperfusion and ischemia at presentation has regularly been postponed until after the ascending aortic repair [3]. In cases of dynamic obstruction, it is reasonable to assume that dissection repair and reestablishment of preferential true lumen blood flow is sufficient to restore leg perfusion, and ischemia can resolve. However, if the obstruction is static (or combined), delaying intervention until after aortic repair may only propagate further ischemic damage, contributing to

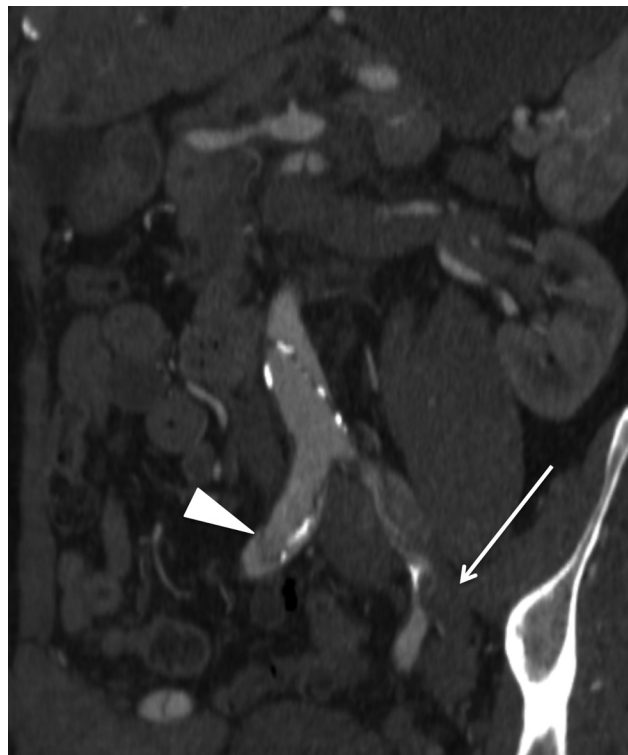


Figure 2. Preoperative computed tomography scan of the aortic bifurcation with intravenous contrast, reformatted image, highlighting occlusion of left external iliac artery with false lumen thrombosis (white **arrow**). Note patent but dissected right common iliac artery (white **arrowhead**).

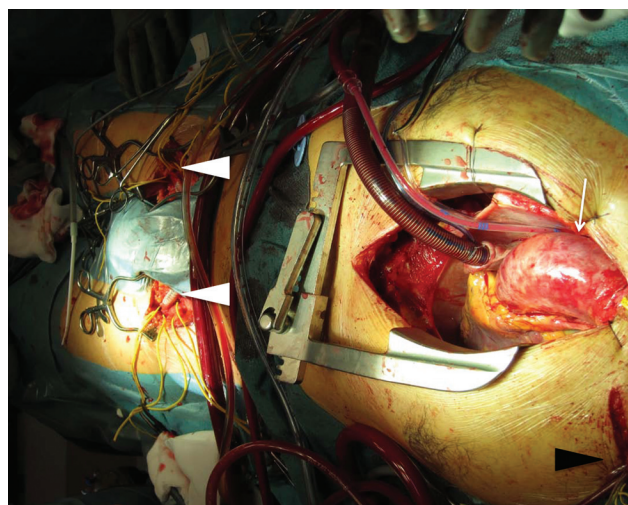


Figure 3. Intraoperative photograph demonstrating the finished femoro-femoral crossover bypass (white **arrowheads**), the exposed heart and dissected ascending aorta (white **arrow**), and the left subclavian artery cannulated from a separate incision (black **arrowhead**).

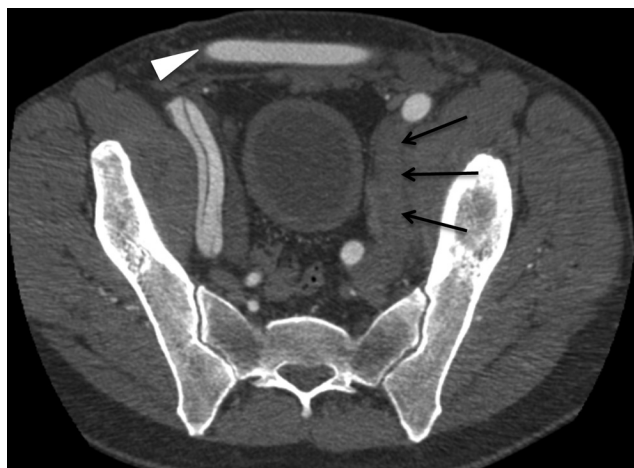


Figure 4. Postoperative computed tomography scan of the pelvic region with intravenous contrast, reformatted image, demonstrating persisting left external iliac artery occlusion (black **arrows**) and patent femoro-femoral crossover bypass graft (white **arrowhead**).

the increased mortality and morbidity associated with end-organ ischemia [1,4]. Performing a simultaneous crossover bypass is a quick and simple solution with high success rate. The only modification of the dissection

operation is refraining from femoral arterial cannulation. The described strategy of selective leg perfusion [5] adds no further benefit in a similar situation, still mandating a revascularization of the affected leg in a postponed or secondary procedure. Endovascular treatment using bare metal stent or stent-graft would either delay the aortic repair (if performed preoperatively), delay leg reperfusion (if performed postoperatively), or demand a hybrid operating suite for the two procedures to be performed simultaneously, along with the cost of the device(s), the need for antithrombotic medication, and the risk of future secondary intervention.

Although outside of manufacturer instructions for use, peripheral INVOSTM tissue saturation monitoring is quick, simple, and probably satisfactory in assessing immediate revascularization outcome and limb reperfusion [6].

Conflict of Interest

The author has no conflict of interest relevant to this publication.

[Comment on this Article or Ask a Question](#)

References

1. Augoustides JG, Geirsson A, Szeto WY, Walsh EK, Cornelius B, Pochettino A, et al. Observational study of mortality risk stratification by ischemic presentation in patients with acute type A aortic dissection: the Penn classification. *Nat Clin Pract Cardiovasc Med.* 2009;6:140–146. [10.1038/ncpcardio1417](https://doi.org/10.1038/ncpcardio1417)
2. Olsson C, Thelin S. Antegrade cerebral perfusion with a simplified technique: unilateral versus bilateral perfusion. *Ann Thorac Surg.* 2006;81:868–874. [10.1016/j.athoracsur.2005.08.079](https://doi.org/10.1016/j.athoracsur.2005.08.079)
3. Charlton-Ouw KM, Sritharan K, Leake SS, Sandhu HK, Miller CC, Azizzadeh A, et al. Management of limb ischemia in acute proximal aortic dissection. *J Vasc Surg.* 2013;57:1023–1029. [10.1016/j.jvs.2012.10.079](https://doi.org/10.1016/j.jvs.2012.10.079)
4. Olsson C, Franco-Cereceda A. Impact of organ failure and major complications on outcome in acute Type A aortic dissection. *Scand Cardiovasc J.* 2013;47:352–358. [10.3109/14017431.2013.845307](https://doi.org/10.3109/14017431.2013.845307)
5. Sunazawa T, Takahara Y, Sudo Y. [Acute type A aortic dissection with leg ischemia]. *Jpn J Thorac Cardiovasc Surg.* 1998;46:1004–1008. [10.1007/BF03217863](https://doi.org/10.1007/BF03217863)
6. Wakimoto MM, Kadosaki M, Nagata H, Suzuki KS. The usefulness of near-infrared spectroscopy in the anesthetic management of endovascular aortic aneurysm repair. *J Anesth.* 2012;26:932–935. [10.1007/s00540-012-1435-1](https://doi.org/10.1007/s00540-012-1435-1)

Cite this article as: Olsson C. Ascending Aortic Repair and Simultaneous Femoro-Femoral Crossover Bypass for Acute DeBakey Type I Dissection with Leg Ischemia. *Aorta* 2014;2(6):286–288. DOI: <http://dx.doi.org/10.12945/j.aorta.2014.14-027>

EDITOR'S COMMENTS

Like many surgical teams, we usually treat the ascending dissection and then find, through nature's miracle, that all malperfused organs are now well supplied with blood. However, although common, this reperfusion is not always universally accomplished by the ascending repair. In this case report, Olsson and colleagues take a very aggressive approach to leg

ischemia at presentation—performing a crossover femoral graft and three-compartment fasciotomy. This aggressive approach bears fruit, with resolution of leg ischemia. This approach of concomitant crossover femoral graft deserves consideration in such cases, representing a creative and aggressive approach that does not interfere with or significantly delay the primary job at hand—correcting the Type A dissection.