

# Somatosensory evoked potentials in clinical practice: a review

## Potenciais evocados somatossensitivos na prática clínica: uma revisão

Otto Jesus Hernández FUSTES<sup>1</sup>, Cláudia Suemi Kamoi KAY<sup>1</sup>, Paulo José LORENZONI<sup>1</sup>, Renata Dal-Prá DUCCI<sup>1</sup>, Lineu Cesar WERNECK<sup>1</sup>, Rosana Herminia SCOLA<sup>1</sup>

### ABSTRACT

The authors present a review of the current use of somatosensory evoked potentials (SSEPs) in neurological practice as a non-invasive neurophysiological technique. For this purpose we have reviewed articles published in English or Portuguese in the PubMed and LILACS databases. In this review, we address the role of SSEPs in neurological diseases that affect the central nervous system and the peripheral nervous system, especially in demyelinating diseases, for monitoring coma, trauma and the functioning of sensory pathways during surgical procedures. The latter, along with new areas of research, has become one of the most important applications of SSEPs.

**Keywords:** Evoked Potentials, Somatosensory; Neurology; Multiple Sclerosis; Coma; Intraoperative Neurophysiological Monitoring.

### RESUMO

Os autores apresentam uma revisão do uso atual do potencial evocado somatossensitivo (PESS) na prática neurológica como uma técnica neurofisiológica não invasiva. Revisamos artigos publicados em Inglês ou Português nas bases de dados PubMed e LILACS. Nesta revisão abordamos o papel do PESS nas doenças neurológicas que atingem o sistema nervoso central e o sistema nervoso periférico, especialmente, nas doenças desmielinizantes, no monitoramento do coma, do trauma e da função das vias sensitivas durante os procedimentos cirúrgicos, que se tornou uma de suas aplicações mais importantes, assim como novas áreas de pesquisa.

**Palavras-chave:** Potenciais Somatossensoriais Evocados; Neurologia; Esclerose Múltipla; Coma; Monitorização Neurofisiológica Intraoperatória.

### INTRODUCTION

In the last fifty years, with the development of informatics and computing, use of evoked potentials (EPs) has evolved from research laboratories to application in clinical neurology. EPs are the electrical signals generated by the nervous system in response to sensory stimuli, whether auditory, visual or somatosensory. These stimuli are commonly used for clinical studies on EPs<sup>1</sup>.

EPs provide noninvasive methods of assessing the neural activity of the nervous system. Given the anatomical characteristics of the sensory and motor pathways and their proximity to areas linked to vegetative, conscious and cognitive processes,

EPs can represent an important resource for detecting and locating neurological disorders. They can reveal nervous system disorders that are not detected through conventional methods<sup>2</sup>.

The somatosensory system consists of two major parts: the dorsal column–lemniscal system and the spinothalamic system. The dorsal column–lemniscal system is the anatomical-functional substrate evaluated through somatosensory evoked potentials (SSEPs). This subserves mechanoreception (tactile object recognition, localization of skin contact, detection of vibration and texture) and proprioception (joint position, movement and force)<sup>3</sup>.

The dorsal column–lemniscal system can be divided into four neuronal populations. The somata of the first-order neuron

<sup>1</sup>Universidade Federal do Paraná, Complexo Hospital de Clínicas, Departamento de Clínica Médica, Serviço de Neurologia, Serviço de Doenças Neuromusculares e Desmielinizantes, Curitiba PR, Brazil.

OJHF  <https://orcid.org/0000-0003-0778-5376>; CSKK  <https://orcid.org/0000-0003-0173-0809>; PJL  <https://orcid.org/0000-0002-4457-7771>; RDPD  <https://orcid.org/0000-0002-1673-5074>; LCW  <https://orcid.org/0000-0003-1921-1038>; RHS  <https://orcid.org/0000-0002-3957-5317>

**Correspondence:** Otto J. H. Fustes; Email: otto.fustes@hc.ufpr.br.

**Conflict of interest:** There is no conflict of interest to declare.

**Authors' contributions:** OJHF: conceptualization, data curation, investigation, methodology, formal analysis, project administration, roles/writing original draft; CSKK: conceptualization, data curation, formal analysis, investigation, methodology, validation, visualization, project administration, roles/writing; PJL, RDD: conceptualization, data curation, formal analysis, investigation, methodology, roles/writing; LCW: conceptualization, validation, visualization, supervision, writing review & edit; rhs: conceptualization, validation, visualization, formal analysis, project administration, supervision, writing review & edit.

Received on September 04, 2020; Received in its final form on December 13, 2020; Accepted on December 28, 2020.

are situated in the dorsal root ganglia, trigeminal ganglion, midbrain trigeminal nucleus and vagal ganglion nodosum. The second-order neuron lies in the dorsal column nuclei, and axons of the second neuron cross the midline. Both systems project to the ventroposterior nuclei of the thalamus (third-order neuron) and from there into the network of somatosensory cortex areas (fourth-order neurons)<sup>3</sup>.

Clinical applications of EPs take into account the interindividual variability between normal people. It is important to carry out standardization studies to obtain reference intervals in each laboratory, or to use normative values that take into account the characteristics of the population to be evaluated. The latencies have Gaussian distribution, and normality in these studies is defined as the mean value plus two or three standard deviations. As with any other examination, the interpretation must take into account the clinical context<sup>2</sup>.

EPs, as a complement to neurological examinations, have clinical utility based on their ability to demonstrate abnormal conduction of the sensory system. This is seen particularly in situations of ambiguity of the history and/or physical examination, thereby revealing subclinical involvement of a sensory system, and especially when demyelination is suggested by symptoms and/or signs in another area of the central nervous system. This helps to define the anatomical distribution and provides an insight into the pathophysiology of a pathological process. It also enables monitoring of changes to the patient's neurological status<sup>4</sup>.

In 1982, Guerreiro and Ehrenberg presented a review with three cases on SSEPs. This was the first Brazilian paper on the subject. They presented the new neurophysiological method and its role in neurology<sup>5</sup> and described the technique of SSEP stimulating the nerve of the upper limb. They mentioned that a technique for stimulating the peroneal nerve would be promising: SSEP for stimulating the tibial nerve has now become a reality. They pointed out that SSEP following nerve stimulation is a unique noninvasive, clinical test for evaluating the somatosensory pathways. It has been shown to be a reliable and useful clinical test, particularly among multiple sclerosis and comatose patients<sup>5</sup>.

Forty years on, we present a historical review of the role of SSEP.

## METHODS

For this review, a web-based search of the literature in the English or Portuguese languages was conducted in two databases: PubMed (<https://www.ncbi.nlm.nih.gov/pubmed/>) and LILACS (<https://lilacs.bvsalud.org/>). The search terms used included "somatosensory evoked potentials"; "somatosensory evoked potentials in neurology"; and "somatosensory evoked potentials AND Brazil". Where available, reviews or brief statements from national or international neurological societies

were taken into account. We incorporated studies that were made available online up to July 1, 2020.

## Somatosensory evoked potential - review

Unlike conventional sensory nerve conduction techniques, which are used mainly to assess the distal segment of the peripheral nerve, SSEP studies assess the entire length of the afferent pathways. Electrical, mechanical, thermal or air-jet stimuli can generate detectable responses. In the clinical setting, electrical stimuli are used, as they generate synchronous and easily controlled action potentials<sup>2</sup>, and post-synaptic potentials.

The stimulus is usually constituted by transcutaneous application of a brief electric shock, with a beginning and an abrupt end. The electrical stimuli used to generate these responses are square-wave pulses, which are delivered to the peripheral nerve with the cathode proximal to the anode. Regarding the intensity of the pulses, the central evoked responses reach their maximum amplitude when the intensity of the stimulus is between three and four times the sensory threshold, which is equivalent to a value slightly above the motor threshold<sup>2,6</sup>.

This type of stimulus causes stimulation of the thick fibers that make up the peripheral nerves. There are no retrograde motor volley effects in the motor nerves, on central projections of the sensory fibers. When the activity triggered in these fibers enters the central nervous system, it goes to local interneurons in the medullary gray substance, at the level of the fiber entrance. Thereafter, through the main extent of these fibers, it goes up through the posterior cords following the medial lemniscal pathway: posterior cord nuclei and lemniscomedial, ventroposterolateral or medial nuclei and, thence, via thalamocortical radiation to the primary areas of the cerebral cortex<sup>2,3</sup>.

These responses are made up of several components, each related to some point of the path described. In clinical neurology, the nerves that are stimulated are usually the median (Figure 1) and tibial nerves in the upper and lower limbs, respectively, although other nerves may possibly be studied<sup>6,7</sup>.

The sites used for placement of recording electrodes for studying nerves in the upper extremities generally include Erb's point in the supraclavicular fossa (a negative peak with

SSEP Upper limb stim. Mediano Right

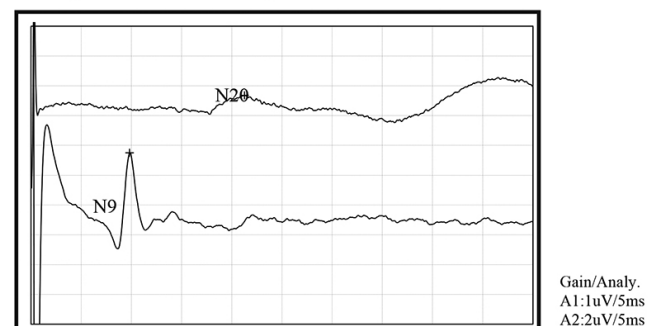


Figure 1. Somatosensory evoked potential (SSEP) in normal young men.

a latency of about 9 msec, designated N9), the cervical spine (a negative peak at about 13 msec, designated N13) and the contralateral scalp overlying the area of the primary sensory cortex, corresponding to C3 or C4 of the International 10-20 System (a negative peak at about 20 msec, designated N20). Also, a reference electrode is placed on the forehead (Fz) and a ground electrode is placed proximally to the stimulation site.

The sources of these responses remain a matter of debate, although N9 may be generated by fibers in the brachial plexus. N13 is thought to be generated by the dorsal column nuclei and N20 by thalamocortical radiations and possibly the primary sensory cortex and motor cortex. Occasionally, a negative peak of latency of approximately 11 msec (N11) precedes the N13 response: this is believed to reflect activity in the posterior columns and the dorsal root entry zone of the spinal cord.

To record SSEPs from nerves situated in the lower extremities, recording electrodes are generally placed on the lumbar spine over the L3 spinous process, on the lower thoracic spine at T12 and on the scalp over the primary sensory cortex (Cz).

Like the median nerve in the upper extremities, the tibial nerve provides a characteristic SSEP of the lower extremities. When the tibial nerve is stimulated at the ankle, the responses expected include the following: a negative peak with a latency of approximately 19 msec recorded at L3 (designated L3S); a negative peak at about 21 msec at T11 (designated T11S); and a positive peak at approximately 37 to 40 msec at the scalp (designated P37 or P40), followed by a negative peak with a latency of about 45 msec (designated N40 or N45).

The L3S response reflects the activity in the nerve roots of the cauda equina, whereas the T11S response is believed to be generated by the dorsal fibers of the spinal cord and the scalp potentials are considered to be reflexes of the thalamocortical activity. Peak latencies between N13-N20 or N21-P37/N40 waves function as a measure of the conduction time along the central and spinal somatosensory pathways. Conduction through the central nervous system is referred to as central conduction time and is measured from N13 to N20 in the upper extremities and from L3S to P40 in the lower extremities<sup>6,7,8</sup>.

SSEPs are interpreted clinically from the anatomofunctional point of view of the generators of the different waves or components. Absence of an expected component suggests that the path is compromised in the anterior segment or at the level of its generator. On the other hand, presence of an expected component, but with prolonged latency, suggests the existence of myelin impairment of the pathway<sup>2</sup>. The criteria for abnormality include absence of any obligate waves and prolongation of interpeak intervals. For example, absence of N13, N20 or a prolonged N13-N20 interval suggests that there is a lesion between the medulla and sensory cortex.

The criteria that need to be met to establish a causal relationship between activity on a neural structure and potential recorded on the scalp are based on the origins of the SSEP. Potentials measured externally to a source structure can be classified into near and far-field types. Near-field potentials

are voltages recorded in the vicinity of the generator. The near-field signal is maximum at the points closest to the generator.

Peripheral nerve stimulation originates a time-limited sequence of action potentials and stationary postsynaptic potentials along the dorsal somatosensory pathway. Spatial summing and volume conduction enable SSEP surface recording.

The displacement latencies of the SSEP increase with increasing distance at which the stimulus is recorded, and stationary SSEP latencies increase with the generation of stimulus distance from the structure.

In this regard, according to Emerson & Pedley, there must be some synchronism between the neural event and the surface potential. There is evidence that the neural event generates a signal that can be registered beyond the original structure and that no other simultaneous neural activity could explain the signal recorded on the scalp<sup>8</sup>.

### Clinical applications

SSEPs are used to evaluate both the central and the peripheral nervous systems (Table 1). The findings may be helpful in showing that a lesion is present in the somatosensory pathways, thus helping to localize it and providing a prognostic guide<sup>3</sup>. Electrical stimulation, as currently used, allows assessment of pathways related to thick peripheral fibers, while electrophysiological assessment of peripheral nerves, plexuses and roots is performed in a more appropriate and informative way through electroneuromyographic studies<sup>3,4</sup>.

To establish a valid neurological diagnosis of lesions of the somatosensory system, confirmatory laboratory tests are often necessary, in addition to the clinical features<sup>9</sup>. In caring for a patient with a clinical history and clinical sensory tests suggestive of involvement of large-fiber neuropathy and the dorsal column, clinical neurophysiological tests like recordings of nerve action potentials and SSEPs are standard procedures that add objective evidence to a diagnosis.

According to Baumgärtner et al., assessment of the functioning of small fibers and the spinothalamic tract should be of equal clinical relevance. This would contribute to investigating the functioning of the nociceptive system in painful situations. Small-fiber function can be assessed using a variety of methods, including analysis on nociceptive reflexes and functional testing of the sympathetic system, which typically conveys its efferent signals through thinly or unmyelinated nerve fibers<sup>9</sup>.

However, in some situations in which the impairment is severe, SSEPs may prove useful. In spinal cord dysfunctions, SSEPs are sensitive to involvement of the posterior cord pathways, thus allowing detection of subclinical involvement, with assessment of doubtful clinical situations and objective documentation of the involvement of the pathway. In situations of involvement of other spinal pathways, with preservation of the posterior cord pathways, the responses are normal. However, one exception to this is the involvement of the gray matter at the entrance of fibers relating to the stimulated nerve and, in

**Table 1.** Indications for SSEPs in Neurology.

Indications	Diseases	References
Peripheral nervous system disorders	Neuropathies: nerve entrapment, diabetic neuropathy, hereditary neuropathy	7,37,38,39,53
	Proximal mononeuropathy	35,36
	Isolated radiculopathy	7,40,41,54
	Proximal involvement in Guillain-Barré syndrome	34
	Chronic inflammatory Demyelinating polyradiculoneuropathy	32,33
Central nervous system disorders	Ataxia	21
	Multiple sclerosis	3,7,15,16
	Neuromyelitis optica	18
	Epilepsies	12,13,14
	Lesions in the brainstem, diencephalon or cerebral hemispheres	3,7,12,
	Coma and brain death	11,12,24,27
	Myelopathy	19,20,42,43
	Spinal cord tumors	7
	Chronic spinal cord injury	43
	Schizophrenia	44,45,46,47
	Psychoses	48
	Amyotrophic lateral sclerosis	29
	Hereditary spastic paraplegia	22
Neurophysiological intraoperative monitoring	Intracranial vascular surgery	49,50,51
	Epilepsy surgery	
	Posterior fossa surgery	
	Spinal surgery	

this case, the N13 component relating to the median nerve (or N22 relating to the lower limbs), which is generated by segmental interneurons, may be absent<sup>6</sup>.

In dysfunctions involving the brain stem, SSEPs are useful and sensitive if the lemniscal pathway is affected. In lesions involving the thalamus, all waves are normal, with the exception of waves of cortical origin, which are reduced or absent, or have prolonged latencies. This is the same pattern of responses found in cortical involvement concerning area 3b<sup>10,11</sup>.

In cases in which cortical myoclonus occurs, cortical potentials with markedly high amplitudes are frequently recorded. These are known as giant potentials, which can sometimes be observed in EEGs, depending on the equipment sensitivity. In these situations, the findings are of clinical use because they reflect increased cortical excitability. Giant potentials have been reported in patients with progressive myoclonic epilepsy or late childhood ceroid lipofuscinosis, and in some patients with photosensitive epilepsy<sup>12</sup>. These potentials can still be seen in some forms of mitochondrial diseases and in some cases of benign childhood epilepsies with evoked parietal tips. Giant SSEPs are recognized as an expression of hyperexcitability of the cerebral cortex. Although the pathophysiology is still not clear, it may reflect abnormal cortical function with repercussions in a distant area. Thus, hyperexcitability of the somatosensory

cortex could induce pyramidal tract neurons in motor cortex to generate myoclonic seizures<sup>13,14</sup>.

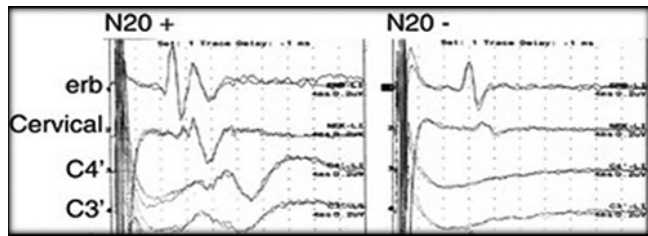
In diseases involving the myelin sheath, SSEPs can be useful. In multiple sclerosis with cerebral or spinal cord involvement, SSEP abnormalities are present in 90% of the patients with a definitive diagnosis and in approximately 50% of the patients with sensory signs or symptoms. Specifically, abnormalities of tibial nerve SSEPs are more frequently evident (Figure 2). Abnormalities of EPs appear to better correlate with disability in MS than do conventional measurements of MRI lesion load. Ramanathan et al. demonstrated that prolongation of tibial nerve cortical responses (P37) was also a robust neurophysiological biomarker of disability in MS<sup>15</sup>. Moreover, EPs can be used to evaluate brainstem function in order to predict disease progression in people with clinically isolated syndrome<sup>16</sup>.

The potentials obtained from the lower limbs are more sensitive due to the greater distances covered by the salvo of potentials in the central nervous system<sup>17</sup>.

SSEPs of the lower limbs are good indicators for disability status at times of relapses and may be a good tool for reflecting the frequency of relapses in cases of neuromyelitis optica<sup>18</sup>.

Abnormalities have also been described in adrenoleukodystrophy, adrenomyeloneuropathy and metachromatic leukodystrophy. In degenerative diseases that present impairments of these pathways, abnormalities can be detected, as in cases of





**Figure 2.** Median nerve somatosensory evoked potential (SSEP), with N20 cortical responses present (left) and absent (right).

Friedreich's ataxia, hereditary cerebellar ataxias and hereditary spastic paraparesis<sup>3,4,7</sup>.

However, multifocal involvement of central white matter either clinically or electrophysiologically is not specific to multiple sclerosis. It may also occur in patients with human immunodeficiency virus infection<sup>19</sup>, vitamin B12 or vitamin E deficiency<sup>20</sup>, neurosyphilis, hereditary ataxic syndromes<sup>21</sup> or hereditary spastic paraplegia<sup>22</sup>.

EPs of short latency are, in general, useful for evaluating patients in a coma, given that they do not change according to the metabolic and pharmacological state<sup>11,23</sup>. Absence of cortical responses (N20) bilaterally is a reliable sign of a poor prognosis. Patients who present unilateral preservation of these responses may show functional recovery. Meta-analyses on the bilateral absence of cortical N20 responses, recorded after 72 hours, can predict death or a persistent vegetative state with a specificity of 99% in situations of anoxic-ischemic brain injury and around 95% in traumatic coma<sup>24,25</sup>.

Use of evoked cortical potentials for prognosis and monitoring of patients with traumatic brain and spinal cord injuries forms an important neurophysiological tool<sup>26</sup>. The type that is most applied in the neurocritical care setting is median nerve somatosensory evoked potentials, which assess the intact connectivity of peripheral sensory nerves to cortical projections<sup>27</sup>.

SSEPs are assessed as normal, abnormal (increased latency or reduced amplitude) or absent on each side. When bilaterally absent or alternatively normal following trauma, SSEPs may help detect patients with poor or good prognosis. For example, normal SSEPs after trauma are associated with a 57% chance of good recovery, whereas bilaterally absent SSEPs are associated with only a 1% chance of functional recovery. In addition, repeated SSEP measurements may also help detect patients with brainstem herniation due to interruption of these functional connections, or with cerebral ischemia correlating with jugular bulb evidence of reduced oxygen content. Changes to the median SSEP may precede a rise in intracranial pressure in 30% of the cases<sup>27,28</sup>.

These SSEP findings are even more robust when they fail to improve with time. In general, evoked potentials are less influenced by sedation or hypothermia than are EEGs<sup>29</sup>.

Investigation of changes in sensory pathways in motor neuron diseases has become a new indication for SSEPs. According to Iglesias et al., the peripheral conduction time was normal with N9 latency, but based on N20 latency, the central conduction

time (between spinal cord and parietal cortex) was found to be slower ( $p < 0.05$ ). Altered SSEPs were also correlated with the disease duration ( $p < 0.05$ ). Taken together, spinal imaging and electrophysiology helped to identify 85% of their patients with subclinical sensory defect while these methods revealed abnormal values in ~60% when used separately<sup>30</sup>.

SSEPs can provide an objective and reproducible assessment of the neuraxis from the peripheral nerve to the cortex. This complements the information obtained from clinical and neuroradiological examinations and, as such, is useful in pediatric neurology. SSEPs are useful in monitoring coma and surgical procedures, for detecting preclinical abnormalities, particularly patterns of abnormalities, and for localizing lesions within this sensory system<sup>31</sup>.

SSEPs have also been shown to be useful in diagnosing diseases that affect mainly the peripheral nervous system, such as chronic inflammatory demyelinating polyneuropathy<sup>32,33</sup>, Guillain-Barré syndrome<sup>34</sup>, mononeuropathy<sup>35,36</sup>, Charcot-Marie-Tooth disease<sup>37</sup>, diabetic neuropathy<sup>38</sup> and polyneuropathy<sup>39</sup>. SSEPs complement sensory nerve conduction tests in general, and assessment of proximal sensory fibers in particular, and they are especially helpful in demonstrating proximal neuropathic involvement.

SSEPs are also important complementary diagnostic methods for electrophysiological evaluation of radiculopathies and myelopathies<sup>40-43</sup>. Use of SSEPs for diagnosing radiculopathy has been controversial: this has limited value because abnormalities in a single involved root would be "overshadowed" by contributions from uninvolved roots that supply that nerve. Dermatome SSEPs have generally been found to improve diagnostic yield; however, EMG testing remains the most sensitive electrodiagnostic evaluation for radiculopathy. It complements spinal imaging and often raises other diagnostic possibilities, in addition to confirming clinical suspicions.

SSEPs may provide prognostic information indicative of recovering ambulation, hand function and bladder function after spinal cord injury, or may act as a supplement to clinical testing for predicting functional outcomes. SSEPs are frequently abnormal in patients with myelopathy, and they may be abnormal in the presence of normal EMG evaluation results. Serial examinations have been found to be useful in determining the extent of spinal cord trauma and may help in determining the prognosis for recovery.

SSEPs may provide diagnostic information beyond conventional electrodiagnostic methods. Moreover, lumbar-recorded SSEPs may have an advantage over scalp-recorded ones and sensory nerve stimulated SSEPs over mixed nerve stimulated ones<sup>40</sup>.

One indication little used in Brazil is in psychiatric disorders, such as schizophrenia and psychosis. SSEPs have been found to demonstrate aberrant processing of somatosensory activation in mental illness<sup>44-47</sup>. According to Hagenmuller et al., the deficits in early somatosensory processing in individuals at risk of developing psychosis may not represent a marker

for a genetic risk for psychosis but, rather, may reflect state-dependent factors such as negative symptoms. On the other hand, the transition to psychosis seems to represent an inter-stage between reduced sensory registration from the at-risk state and gating deficits in the chronic state<sup>48</sup>.

Last, but not least, use of SSEPs for monitoring sensory pathway function during surgical procedures has progressively become one of its most important applications. While most frequently used in spinal procedures<sup>49,50</sup> like scoliosis correction, SSEPs have proven to be useful for warning surgeons of impending brain damage consequent to aneurysm clipping and other neurovascular interventions, or to posterior fossa tumor surgery and cardiac or aortic surgery with circulatory arrest<sup>51</sup>.

Over recent years, new techniques have been added to this SSEP universe, such as laser heat stimulators, pain-related evoked potentials (Figure 3) and contact heat evoked potentials (CHEPs). CHEPs have become an acknowledged research tool for assessing the integrity of the nociceptive system and have gained importance in the diagnostic work-up for patients with suspected small fiber-neuropathy. Not only do CHEPs potentially have high diagnostic yield in length-dependent polyneuropathies, but also they have this in patients with non-length dependent patterns of sensory abnormalities<sup>52</sup>. Laser heat stimulators have been extensively used to study time-locked nociception responses, given that they provide a near-ideal method for selectively activating cutaneous A $\delta$ -fiber and C-fiber nociceptors<sup>53,54</sup>.

Our goal here was not to exhaust this topic, but to draw attention to this noninvasive complementary neurophysiological examination, which can add evidence to the clinical diagnosis.

In conclusion, EPs should be seen as a complementary mechanism for a well-conducted neurological examination,

### PREP in Hand Right

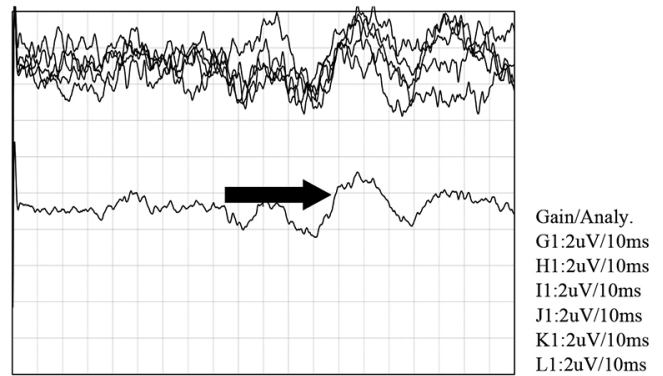


Figure 3. Normal pain-related evoked potential (PREP) in 59-year-old woman.

since they can corroborate doubtful aspects of these examinations or highlight deviations from normal physiology that are undetectable through conventional semiology. EPs can, for example, assist in making the diagnoses of patients with cervical myelopathy who, despite being asymptomatic from a clinical point of view, show evident changes in visual EPs. This would be an unambiguous indication of the presence of at least two distinct lesions in the CNS<sup>55</sup>.

SSEP studies have made steady progress since Dawson's original description<sup>56-58</sup>. The introduction of information technology has enabled digital analysis and thus led to a rapid escalation in the use of SSEP and other EP studies in the clinical domain. However, important questions still remain to be addressed. These include the need to clearly delineate the practical scope of EPs and their proper use. Such uses include standardization of techniques and nomenclature, precise location of neural generators, elucidation of various factors that affect determinations and establishment of normative values.

## REFERENCES

- Poornima S, Ali SS, Balaji PA, Shankar V, Kutty K. Median nerve somatosensory evoked potentials in medical students: normative data. *Adv Biomed Res.* 2013 Jul 30;2:56. <https://doi.org/10.4103/2277-9175.115797>
- Manzano GM, Nader Mangini N, Pereira Giuliano LM. Potenciais evocados cerebrais. In: Nóbrega JAM, Manzano GM, editors. *Manual de eletroneuromiografia e potenciais evocados cerebrais para a prática clínica.* São Paulo (SP): Atheneu; 2007. p. 51-65.
- Cruccu G, Aminoff MJ, Curio G, Guerit JM, Kakigi R, Mauguire F, et al. Recommendations for the clinical use of somatosensory-evoked potentials. *Clin Neurophysiol.* 2008 Aug;119(8):1705-19. <https://doi.org/10.1016/j.clinph.2008.03.016>
- Walsh P, Kane N, Butler S. The clinical role of evoked potentials. *J Neurol Neurosurg Psychiatry.* 2005 Jun;76(2 Suppl 2):ii16-22. <https://doi.org/10.1136/jnnp.2005.068130>
- Guerreiro CAM, Ehrenberg BL. Somatosensory evoked response: application in neurology. *Arq Neuropsiquiatr.* 1982 Mar;40(1):29-38. <https://doi.org/10.1590/S0004-282X1982000100004>
- American Electroencephalographic Society. Guidelines for clinical evoked potentials studies. *J Clin Neurophysiol.* 1984 Jan;1(1):3-53.
- Kraft GH, Aminoff MJ, Baran EM, Litchy WJ, Stolov WC. Somatosensory evoked potentials: clinical uses. AAEM somatosensory evoked potentials subcommittee. American association of electrodiagnostic medicine. *Muscle Nerve.* 1998 Feb;21(2):252-8. [https://doi.org/10.1002/\(SICI\)1097-4598\(199802\)21:2<252::AID-MUS17>3.0.CO;2-3](https://doi.org/10.1002/(SICI)1097-4598(199802)21:2<252::AID-MUS17>3.0.CO;2-3)
- Emerson RG, Pedley TA. Generator sources of median somatosensory evoked potentials. *J Clin Neurophysiol.* 1984 Apr;1(2):203-18. <https://doi.org/10.1097/00004691-198404000-00004>
- Baumgärtner U, Greffrath W, Treede R-D. Contact heat and cold, mechanical, electrical and chemical stimuli to elicit small fiber-evoked potentials: merits and limitations for basic science and clinical use. *Neurophysiol Clin.* 2012 Oct;42(5):267-80. <https://doi.org/10.1016/j.neucli.2012.06.002>
- Mauguiere F, Challet ME, Brechler MT. Cervical somatosensory evoked potentials in the healthy subject: analysis of the effect of the location of the reference electrode on aspects of the responses. *Rev Electroencephalogr Neurophysiol Clin.* 1983 Dec;13(3):259-72. [https://doi.org/10.1016/S0370-4475\(83\)80037-9](https://doi.org/10.1016/S0370-4475(83)80037-9)
- Logi F, Fischer C, Murri L, Mauguire F. The prognostic value of

- evoked responses from primary somatosensory and auditory cortex in comatose patients. *Clin Neurophysiol.* 2003 Sep;114(9):1615-27. [https://doi.org/10.1016/S1388-2457\(03\)00086-5](https://doi.org/10.1016/S1388-2457(03)00086-5)
12. Martín MMB, Fernández LG, Abreu IC, González LA, Araujo F. Potenciales evocados gigantes. *Rev Neurol.* 2001 Dec 16-31;33(12):1120-5.
  13. Berkovic SF, Cochius J, Andermann E, Andermann F. Progressive myoclonus epilepsies: clinical and genetic aspects. *Epilepsia.* 1993;34 Suppl 3:S19-30. <https://doi.org/10.1111/j.1528-1167.1993.tb06256.x>
  14. Vidal-Dourado M, Nunes KF, Guaranha MSB, Giuliano LMP, Yacubian EMT, Manzano GM. Expression of praxis induction on cortical excitability in juvenile myoclonic epilepsy. *Clin Neurophysiol.* 2016 Jul;127(7):2551-60. <https://doi.org/10.1016/j.clinph.2016.03.028>
  15. Ramanathan S, Lenton K, Burke T, Gomes L, Storchenegger K, Yiannikas C, et al. The utility of multimodal evoked potentials in multiple sclerosis prognostication. *J Clin Neurosci.* 2013 Nov 1;20(11):1576-81. <https://doi.org/10.1016/j.jocn.2013.01.020>
  16. Crnošija L, Gabelić T, Barun B, Adamec I, Skorić MK, Habek M. Evoked potentials can predict future disability in people with clinically isolated syndrome. *Eur J Neurol.* 2020 Mar;27(3):437-44. <https://doi.org/10.1111/ene.14100>
  17. Sand T, Bu Kvaløy M, Wader T, Hovdal H. Evoked potential tests in clinical diagnosis. *Tidsskr Nor Laegeforen.* 2013 May 7;133(9):960-5. <https://doi.org/10.4045/tidsskr.12.1176>
  18. Tsao W-C, Lyu R-K, Ro L-S, Lao M-F, Chen C-M, Wu Y-R, et al. Clinical correlations of motor and somatosensory evoked potentials in neuromyelitis optica. *PLoS One.* 2014 Nov 25;9(11):e113631. <https://doi.org/10.1371/journal.pone.0113631>
  19. Tagliati M, Di Rocco A, Danisi F, Simpson DM. The role of somatosensory evoked potentials in the diagnosis of AIDS-associated myelopathy. *Neurology.* 2000 Apr 11;54(7):1477-82. <https://doi.org/10.1212/WNL.54.7.1477>
  20. Misra UK, Kalita J, Das A. Vitamin B12 deficiency neurological syndromes: a clinical, MRI and electrodiagnostic study. *Electromyogr Clin Neurophysiol.* 2003 Jan-Feb;43(1):57-64.
  21. Nuwer MR, Perlman SL, Packwood JW, Kark RAP. Evoked potential abnormalities in the various inherited ataxias. *Ann Neurol.* 1983 Jan;13(1):20-7. <https://doi.org/10.1002/ana.410130106>
  22. Thomas PK, Jefferys JG, Smith IS, Loulakakis D. Spinal somatosensory evoked potentials in hereditary spastic paraplegia. *J Neurol Neurosurg Psychiatry.* 1981 Mar;44(3):243-6. <https://doi.org/10.1136/jnnp.44.3.243>
  23. Machado C. An early approach to brain death diagnosis using multimodality evoked potentials and electroretinography. *Minerva Anestesiol.* 1994 Oct;60(10):573-7.
  24. Luccas FJC, Lopes JÁ, Plastino FRT, Knobel E. Avaliação neurofisiológica por potenciais evocados sensoriais multimodais em pacientes em coma. *Arq Neuropsiquiatr.* 1990 Sep;48(3):320-8. <https://doi.org/10.1590/S0004-282X1990000300009>
  25. Young GB, Wang JT, Connolly JF. Prognostic determination in anoxic-ischemic and traumatic encephalopathies. *J Clin Neurophysiol.* 2004 Sep-Oct;21(5):379-90.
  26. Carter BG, Butt W. Review of the use of somatosensory evoked potentials in the prediction of outcome after severe brain injury. *Crit Care Med.* 2001 Jan;29(1):178-86. <https://doi.org/10.1097/00003246-200101000-00036>
  27. Robinson LR, Micklesen PJ, Tirschwell DL, Lew HL. Predictive value of somatosensory evoked potentials for awakening from coma. *Crit Care Med.* 2003 Mar;31(3):960-7. <https://doi.org/10.1097/01.CCM.0000053643.21751.3B>
  28. Amantini A, Fossi S, Grippo A, Innocenti P, Amadori A, Bucciardini L, et al. Continuous EEG-SSEP monitoring in severe brain injury. *Neurophysiol Clin.* 2009 Apr;39(2):85-93. <https://doi.org/10.1016/j.neucli.2009.01.006>
  29. Rosenthal ES. The utility of EEG, SSEP, and other neurophysiologic tools to guide neurocritical care. *Neurotherapeutics.* 2012 Jan;9(1):24-36. <https://doi.org/10.1007/s13311-011-0101-x>
  30. Iglesias C, Sangari S, El Mendili M-M, Benali H, Marchand-Pauvert V, Pradat P-F. Electrophysiological and spinal imaging evidences for sensory dysfunction in amyotrophic lateral sclerosis. *BMJ Open.* 2015 Feb 24;5(2):e007659. <https://doi.org/10.1136/bmjopen-2015-007659>
  31. Fagan ER, Taylor MJ, Logan WJ. Somatosensory evoked potentials: part II. A review of the clinical applications in pediatric neurology. *Pediatr Neurol.* 1987 Sep-Oct;3(5):P249-55. [https://doi.org/10.1016/0887-8994\(87\)90063-4](https://doi.org/10.1016/0887-8994(87)90063-4)
  32. Salhi H, Corcia P, Remer S, Praline J. Somatosensory evoked potentials in chronic inflammatory demyelinating polyradiculoneuropathy. *J Clin Neurophysiol.* 2014 Jun;31(3):241-5. <https://doi.org/10.1097/WNP.0000000000000050>
  33. Dziadkowiak E, Ejma M, Wieczorek M, Pec P, Slotwiński K, Budrewicz S, et al. Abnormality of multimodal evoked potentials in chronic inflammatory demyelinating polyradiculoneuropathy (CIDP). *Neurol Sci.* 2020 Sep;41(9):2495-2501. <https://doi.org/10.1007/s10072-020-04351-3>
  34. Brown WF, Feasby TE. Sensory evoked potentials in Guillain-Barre polyneuropathy. *J Neurol Neurosurg Psychiatry.* 1984 Mar;47(3):288-91. <https://doi.org/10.1136/jnnp.47.3.288>
  35. Soares Dias RJ, de Souza L, de Moraes WF, Carneiro AP. SEP-diagnosing neuropathy of the lateral cutaneous branch of the Iliohypogastric nerve. *Arq Neuropsiquiatr.* 2004 Sep;62(3B):895-8. <https://doi.org/10.1590/S0004-282X2004000500032>
  36. Triplett JD, Robertson A, Yiannikas C. Compressive lateral femoral cutaneous neuropathy secondary to sartorius muscle fibrosis. *JAMA Neurol.* 2019 Jan 1;76(1):109-10. <https://doi.org/10.1001/jamaneurol.2018.2955>
  37. Cosi V, Lombardi M, Zandrini C, Gerosa E, Callieco R. Somatosensory evoked potentials in Charcot-Marie-Tooth disease. *Neurophysiol Clin.* 1989 Nov;19(5):359-65. [https://doi.org/10.1016/S0987-7053\(89\)80088-7](https://doi.org/10.1016/S0987-7053(89)80088-7)
  38. Palma V, Serra LL, Armentano V, Serra FP, Nolfi G. Somatosensory evoked potentials in non-insulin-dependent diabetics with different degrees of neuropathy. *Diabetes Res Clin Pract.* 1994 Sep;25(2):P91-6. [https://doi.org/10.1016/0168-8227\(94\)90033-7](https://doi.org/10.1016/0168-8227(94)90033-7)
  39. Synek VM. Role of somatosensory evoked potentials in the diagnosis of peripheral nerve lesions: recent advances. *J Clin Neurophysiol.* 1987 Jan;4(1):55-73. <https://doi.org/10.1097/00004691-198701000-00004>
  40. Beyaz EA, Akyüz G, Us O. The role of somatosensory evoked potentials in the diagnosis of lumbosacral radiculopathies. *Electromyogr Clin Neurophysiol.* 2009 May-Jun;49(4):131-42.
  41. Yue Q, Hale T, Knecht A. A comparison of interside asymmetries of lower extremity somatosensory evoked potentials in anesthetized patients with unilateral lumbosacral radiculopathy. *Asian Spine J.* 2017 Feb 17;11(1):99-104. <https://doi.org/10.4184/asj.2017.11.1.99>
  42. Cruz MW, Corrêa RB, Puccioni-Sohler M, Novis SA. Eletroencefalografia e potenciais evocados somatossensitivos na mielopatia pelo HTLV-I. *Arq Neuropsiquiatr.* 1998 Dec;56(4):756-62. <https://doi.org/10.1590/S0004-282X1998000500009>
  43. Cristante AF, Barros-Filho TEP, Tatsui N, Mendrone A, Caldas JG, Camargo A, et al. Stem cells in the treatment of chronic spinal cord injury: evaluation of somatosensitive evoked potentials in 39 patients. *Spinal Cord.* 2009 Oct;47(10):733-8. <https://doi.org/10.1038/sc.2009.24>
  44. Furlong P, Barczak P, Hayes G, Harding G. Somatosensory evoked potentials in schizophrenia. A lateralisation study. *Br J Psychiatry.* 1990 Dec;157:881-7. <https://doi.org/10.1192/bjp.157.6.881>
  45. Lehtonen J. Somatosensory evoked potentials and the psychology of chronic schizophrenia. An integrative view. *J Nerv Ment Dis.* 1981 Apr;169(4):256-8.

46. Waberski TD, Norra C, Kawohl W, Thyerlei D, Hock D, Klostermann F, et al. Electrophysiological evidence for altered early cerebral somatosensory signal processing in schizophrenia. *Psychophysiology*. 2004 May;41(3):361–6. <https://doi.org/10.1111/1469-8986.2004.00163.x>
47. Daskalakis AA, Zomorodi R, Blumberger DM, Rajji TK. Evidence for prefrontal cortex hypofunctioning in schizophrenia through somatosensory evoked potentials. *Schizophr Res*. 2020 Jan;215:197–203. <https://doi.org/10.1016/j.schres.2019.10.030>
48. Hagenmuller F, Heekeren K, Theodoridou A, Walitza S, Haker H, Rössler W, et al. Early somatosensory processing in individuals at risk for developing psychoses. *Front Behav Neurosci*. 2014 Sep 11;8:308. <https://doi.org/10.3389/fnbeh.2014.00308>
49. Fotakopoulos G, Alexiou GA, Karagiorgiadis D, Voulgaris S. Somatosensory evoked potentials monitoring in cervical spine surgery. *Neurol India*. 2010 Nov-Dec;58(6):980. <https://doi.org/10.4103/0028-3886.73759>
50. Nuwer MR, Schrader LM. Spinal cord monitoring. *Handb Clin Neurol*. 2019;160:329–44. <https://doi.org/10.1016/B978-0-444-64032-1.00021-7>
51. MacDonald DB, Dong C, Quatralo R, Sala F, Skinner S, Soto F, et al. Recommendations of the international society of intraoperative neurophysiology for intraoperative somatosensory evoked potentials. *Clin Neurophysiol*. 2019 Jan;130(1):161–79. <https://doi.org/10.1016/j.clinph.2018.10.008>
52. Rosner J, Hostettler P, Scheuren PS, Sirucek L, Rinert J, Curt A, et al. Normative data of contact heat evoked potentials from the lower extremities. *Sci Rep*. 2018 Jul 20;8(1):11003. <https://doi.org/10.1038/s41598-018-29145-8>
53. Di Stefano G, La Cesa S, Leone C, Pepe A, Galosi E, Fiorelli M, et al. Diagnostic accuracy of laser-evoked potentials in diabetic neuropathy. *Pain*. 2017 Jun;158(6):1100–7. <https://doi.org/10.1097/j.pain.0000000000000889>
54. Hüllemann P, von der Brélie C, Manthey G, Düsterhöft J, Helmers AK, Synowitz M, et al. Laser-evoked potentials in painful radiculopathy. *Clin Neurophysiol*. 2017 Nov;128(11):2292–9. <https://doi.org/10.1016/j.clinph.2017.09.100>
55. Brasil-Neto JP. Reavaliação crítica da utilidade dos potenciais evocados em neurologia clínica. *Arq Neuropsiquiatr*. 1992 Jun;50(2):141–6. <https://doi.org/10.1590/S0004-282X1992000200001>
56. Dawson GD. Cerebral responses to electrical stimulation of peripheral nerve in man. *J Neurol Neurosurg Psychiatry*. 1947 Aug;10(3):134–40. <https://doi.org/10.1136/jnnp.10.3.134>
57. Dawson GD. Investigations on a patient subject to myoclonic seizures after sensory stimulation. *J Neurol Neurosurg Psychiatry*. 1947 Nov;10(4):141–62. <https://doi.org/10.1136/jnnp.10.4.141>
58. Dawson GD, Elithorn A. A two channel chronograph. *J Physiol*. 1954 Feb 26;123(2):16–8.