

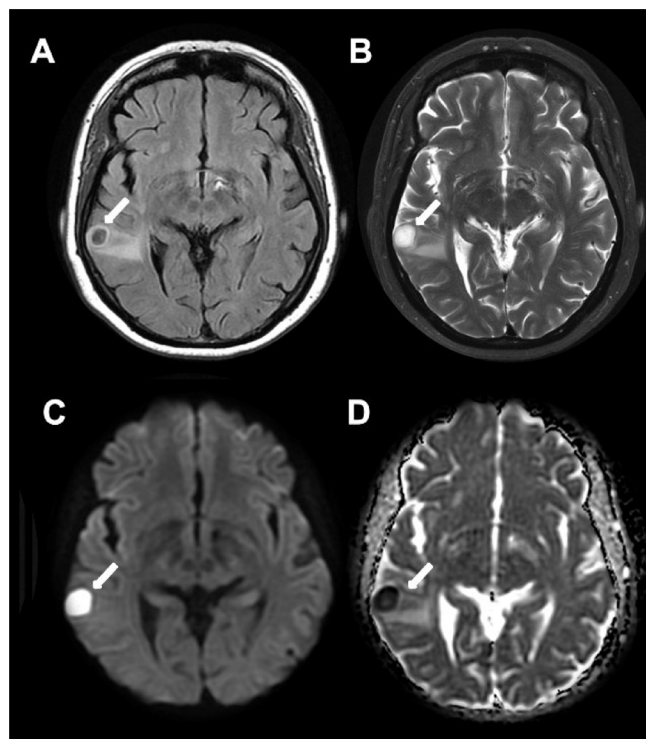
# Brain abscess and hereditary hemorrhagic telangiectasia

## Abscesso cerebral e telangiectasia hemorrágica hereditária

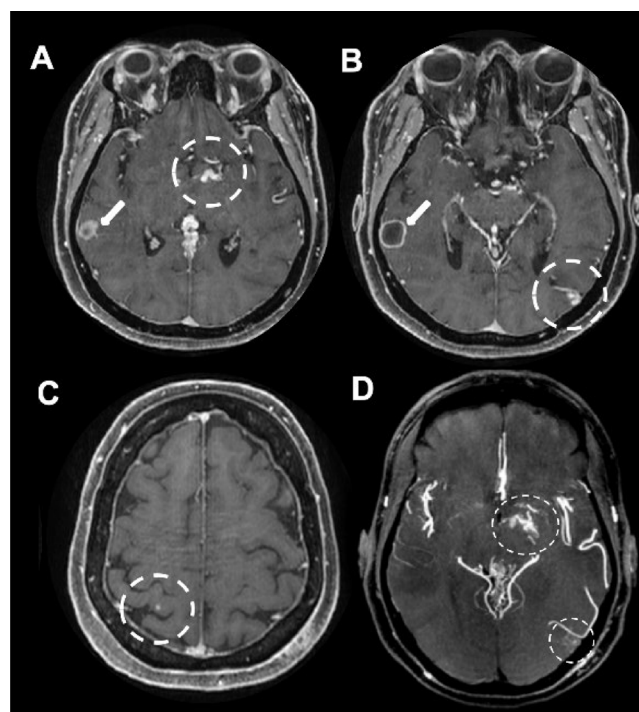
Leonardo Furtado FREITAS<sup>1</sup>, Márcio Luís DUARTE<sup>2</sup>, Eduardo Carvalho MIRANDA<sup>3</sup>

A 58-year-old woman presented speech impairment, mental confusion, and left hemiparesis after being found unconscious. Brain magnetic resonance imaging (MRI) showed pyogenic abscess and multiple vascular malformations in the cerebral hemispheres (Figures 1 and 2), resulting

in suspicion of Rendu-Osler-Weber disease, i.e., hereditary hemorrhagic telangiectasia (HHT). Chest computed tomography (CT) revealed pulmonary arteriovenous malformation. Ectoscopy detected multiple telangiectasia in the lips,



**Figure 1.** Brain MRI in axial FLAIR (A), T2-weighted (B), B1000 diffusion (C), and ADC map (D). A pyogenic abscess surrounded by vasogenic edema (arrows) in the right superior temporal gyrus is detected.



**Figure 2.** Brain MRI in axial, post-gadolinium volumetric T1 (A to C) and MIP (D) sequences. A pyogenic abscess surrounded by vasogenic edema (arrows) in the right superior temporal gyrus is detected (arrows in A and B). Dashed circles of images A to D highlight multiple tiny vascular malformations in both cerebral hemispheres (capillary malformations and microAVs), more conspicuous in the MIP sequence.

<sup>1</sup>Universidade Federal de São Paulo, Departamento de Radiologia, São Paulo SP, Brazil.

<sup>2</sup>Universidade Federal de São Paulo, Departamento de Saúde Baseada em Evidências, São Paulo SP, Brazil.

<sup>3</sup>Rede MaterDei de Saúde, Departamento de Neurorradiologia, Belo Horizonte MG, Brazil.

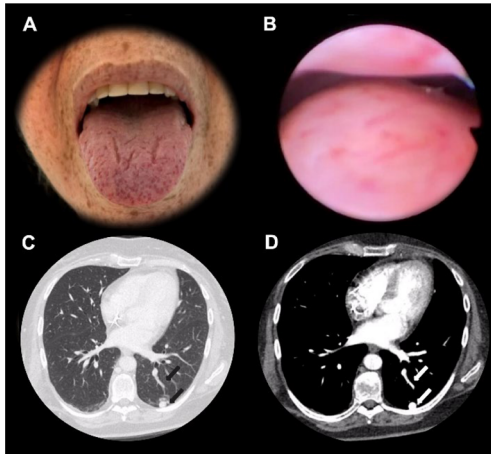
LFL: <https://orcid.org/0000-0001-6944-4978>; MLD: <https://orcid.org/0000-0002-7874-9332>; ECM: <https://orcid.org/0000-0002-9807-7529>

**Correspondence:** Leonardo Furtado Freitas; Email: [drleonardofurtado@gmail.com](mailto:drleonardofurtado@gmail.com).

**Conflict of interest:** There is no conflict of interest to declare.

**Authors' contributions:** LFF, MLD: manuscript composition; ECM: manuscript review.

Received on September 19, 2021; Received in its final form on October 20, 2021; Received in its final form on October 21, 2021.



**Figure 3.** Face ectoscopy (A) and rhinoscopy exam (B); CT of the chest in the lung (C) and soft tissue (D) windows. Other systemic changes in the spectrum of the syndrome: multiple tiny cutaneous telangiectasia on the face, tongue, and labial mucosa (A), as well as on the nasal mucosa (B) and pulmonary vascular malformation compatible with arteriovenous malformation (AVM) (arrows on C and D).

tongue, face, and nasosinus mucosa (Figure 3). HHT is a rare systemic fibrovascular dysplasia (prevalence rate: 1:50000–100000)<sup>1</sup>, and brain abscess is an acute and easily forgotten complication that occurs in 1% of patients with considerable mortality, i.e., death rate of 40%<sup>2</sup>.

## References

1. Fuchizaki U, Miyamori H, Kitagawa S, Kaneko S, Kobayashi K. Hereditary haemorrhagic telangiectasia (Rendu-Osler-Weber disease). *Lancet*. 2003 Nov;362(9394):1490-4. [https://doi.org/10.1016/S0140-6736\(03\)14696-X](https://doi.org/10.1016/S0140-6736(03)14696-X)
2. Dong SL, Reynolds SF, Steiner IP. Brain abscess in patients with hereditary hemorrhagic telangiectasia: case report and literature review. *J Emerg Med*. 2001 Apr;20(3):247-51. [https://doi.org/10.1016/S0140-6736\(03\)14696-X](https://doi.org/10.1016/S0140-6736(03)14696-X)