

Proton spectroscopy: a simple and useful tool in the investigation of mitochondrial disease

Espectroscopia de prótons: uma ferramenta simples e útil na investigação de doença mitocondrial

Daniel Venturino NASSIF¹, Luiz Felipe Rocha VASCONCELLOS¹

A 38-year-old woman presented to the emergency department with right hemiparesis. Brain computed tomography (CT) and magnetic resonance imaging (MRI) were recommended (Figures 1 and 2). Genetic study confirmed the presence of a point mutation m.3243 A>G of mtDNA, confirming the diagnosis of Mitochondrial myopathy, Encephalopathy, Lactic Acidosis, and Stroke-like episodes (MELAS).

MELAS is a rare mitochondrial disorder that can be manifested by stroke-like episodes, epilepsy, hyperlactatemia, myopathy, headaches, deafness, diabetes, and short stature¹. Although not pathognomonic, the lactate peak observed in spectroscopy can be an indication for MELAS diagnosis, which is found to be correlated with the severity of clinical manifestations². Genetic testing confirms the diagnosis³.

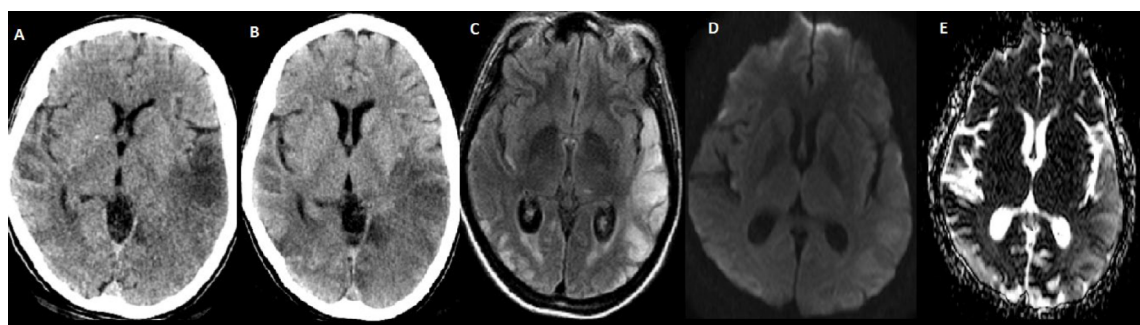


Figure 1. Brain computed tomography during hospital admission (A), 72 hours later (B), and fluid attenuated inversion recovery imaging (C) demonstrating bilateral lesions that do not respect arterial vascular territories. Diffusion-weighted imaging and apparent diffusion coefficient (D–E) demonstrating T2 shine through effect, representing vasogenic rather than cytotoxic edema.

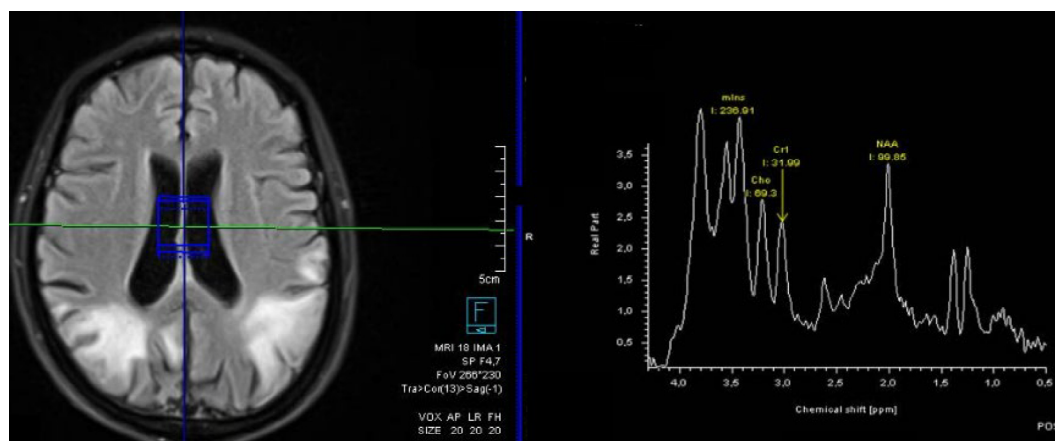


Figure 2. Magnetic resonance imaging spectroscopy demonstrates elevated lactate peak in cerebrospinal fluid.

¹Hospital Federal dos Servidores do Estado, Serviço de Neurologia, Rio de Janeiro, RJ, Brazil.

DVN <https://orcid.org/0000-0003-4203-5765>; LFRV <https://orcid.org/0000-0001-9080-7833>

Correspondence: Daniel Venturino Nassif; Email: danielvnassif@hotmail.com.

Conflict of interest: There is no conflict of interest to declare.

Authors' contributions: DVN, LFRV: design or conceptualization of the study, analysis or interpretation of the data, and drafting or revising the manuscript for intellectual content.

Received on October 16, 2021; Received in its final form on November 23, 2021; Accepted on November 28, 2021.

References

1. El-Hattab AW, Adesina AM, Jones J, Scaglia F. MELAS syndrome: Clinical manifestations, pathogenesis, and treatment options. *Mol Genet Metab*. 2015 Sep-Oct;116(1-2):4-12. <https://doi.org/10.1016/j.ymgme.2015.06.004>
2. Kaufmann P, Shungu DC, Sano MC, Jhung S, Engelstad K, Mitsis E, et al. Cerebral lactic acidosis correlates with neurological impairment in MELAS. *Neurology*. 2004 Apr;62(8):1297-302. <https://doi.org/10.1212/01.wnl.0000120557.83907.a8>
3. Lorenzoni PJ, Werneck LC, Kay CSK, Silvado CES, Scola RH. When should MELAS (Mitochondrial myopathy, Encephalopathy, Lactic Acidosis, and Stroke-like episodes) be the diagnosis? *Arq Neuro-Psiquiatr*. 2015 Nov;73(11):959-67. <https://doi.org/10.1590/0004-282X20150154>