

Lumbago and alopecia in a patient with leukodystrophy: think on CARASIL

Lombalgia e alopecia em um paciente com leucodistrofia: pensar em CARASIL

Paulo Victor Sgobbi de Souza, Wladimir Bocca Vieira de Rezende Pinto, Acary Souza Bulle Oliveira

A 50-year-old Portuguese man presented with a 4-year-history of slurred speech, behavioral changes and tetraparesis with sphincter disturbances. Medical history was positive for chronic lumbar pain with spondylosis and two stroke-like episodes. Family history disclosed consanguineous parents. Examination showed alopecia, spastic tetraparesis, dysarthria and emotional instability. Neuroimaging revealed

diffuse leukoencephalopathy (Figure), compatible with cerebral autosomal recessive arteriopathy with subcortical infarcts and leukoencephalopathy (CARASIL). CARASIL is a hereditary small vessel disease caused by mutations in *HTRA1* gene (10q26.13) and characterized by recurrent strokes, progressive dementia and key systemic features such as lumbago, alopecia, arthropathy, spondylosis and disc herniation^{1,2}.

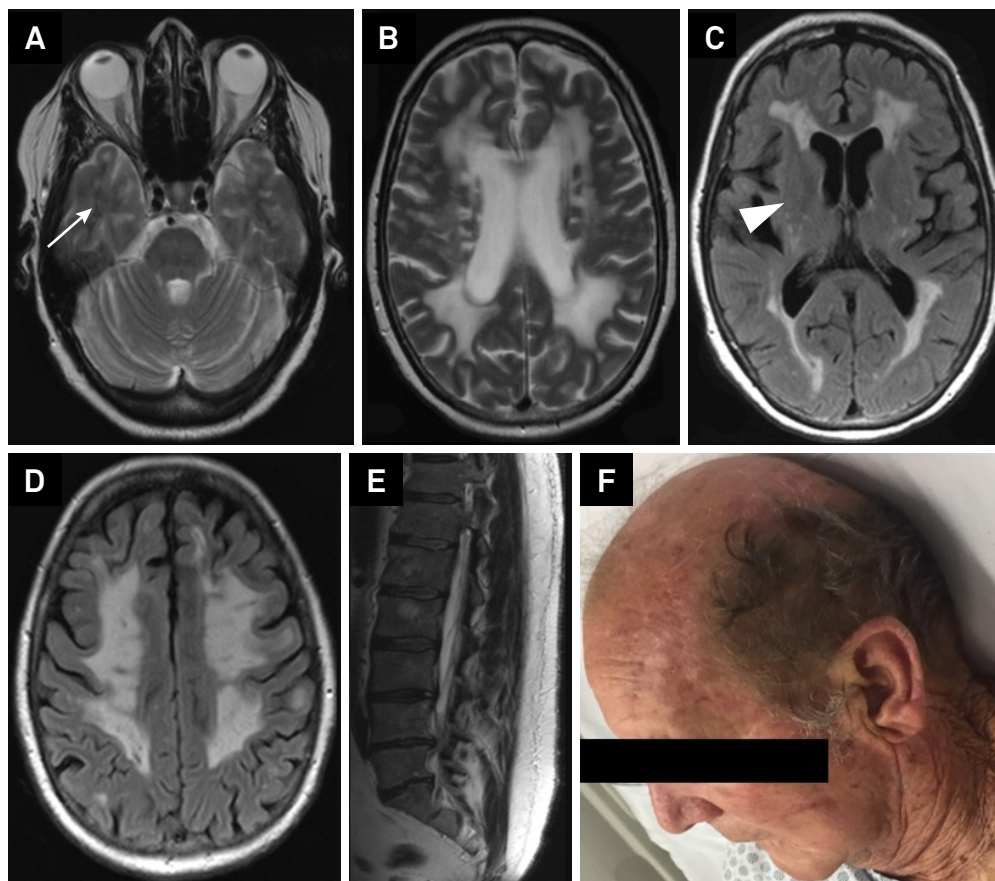


Figure. Typical clinical and neuroimaging features of CARASIL. Axial brain MRI disclosing marked diffuse leukoencephalopathy on T2-weighted (A,B) and FLAIR images (C,D) affecting mainly the periventricular and deep white matter. Only mild hyperintensity is seen in right temporal lobe (white arrow) and absence of marked signal changes are depicted in the external capsules (white arrow-head), differentiating it from the classic neuroimaging pattern described in CADASIL. (E) Lumbar spine MRI showing mild degenerative vertebral spondylosis on T2-weighted image. (F) The patient's marked baldness.

Universidade Federal de São Paulo, Departamento de Neurologia e Neurocirurgia, Divisão de Doenças Neuromusculares, São Paulo SP, Brasil.

Correspondence: Dr. Wladimir Bocca Vieira de Rezende Pinto, Departamento de Neurologia e Neurocirurgia, Universidade Federal de São Paulo (UNIFESP); Rua Estado de Israel, 899; 04022-002 São Paulo SP, Brasil; E-mail: wladimirbvrpinto@gmail.com

Conflict of interest: There is no conflict of interest to declare.

Received 25 Oct 2015; Received in final form 11 Mar 2016; Accepted 18 Apr 2016.

References

1. Fukutake T. Cerebral autosomal recessive arteriopathy with subcortical infarcts and leukoencephalopathy (CARASIL): from discovery to gene identification. *J Stroke Cerebrovasc Dis.* 2011;20(2):85-93. doi:10.1016/j.jstrokecerebrovasdis.2010.11.008
2. Federico A, Di Donato F, Bianchi S, Di Palma C, Taglia I, Dotti MT. Hereditary cerebral small vessel diseases: a review. *J Neurol Sci.* 2012;322:25-30. doi:10.1016/j.jns.2012.07.041