

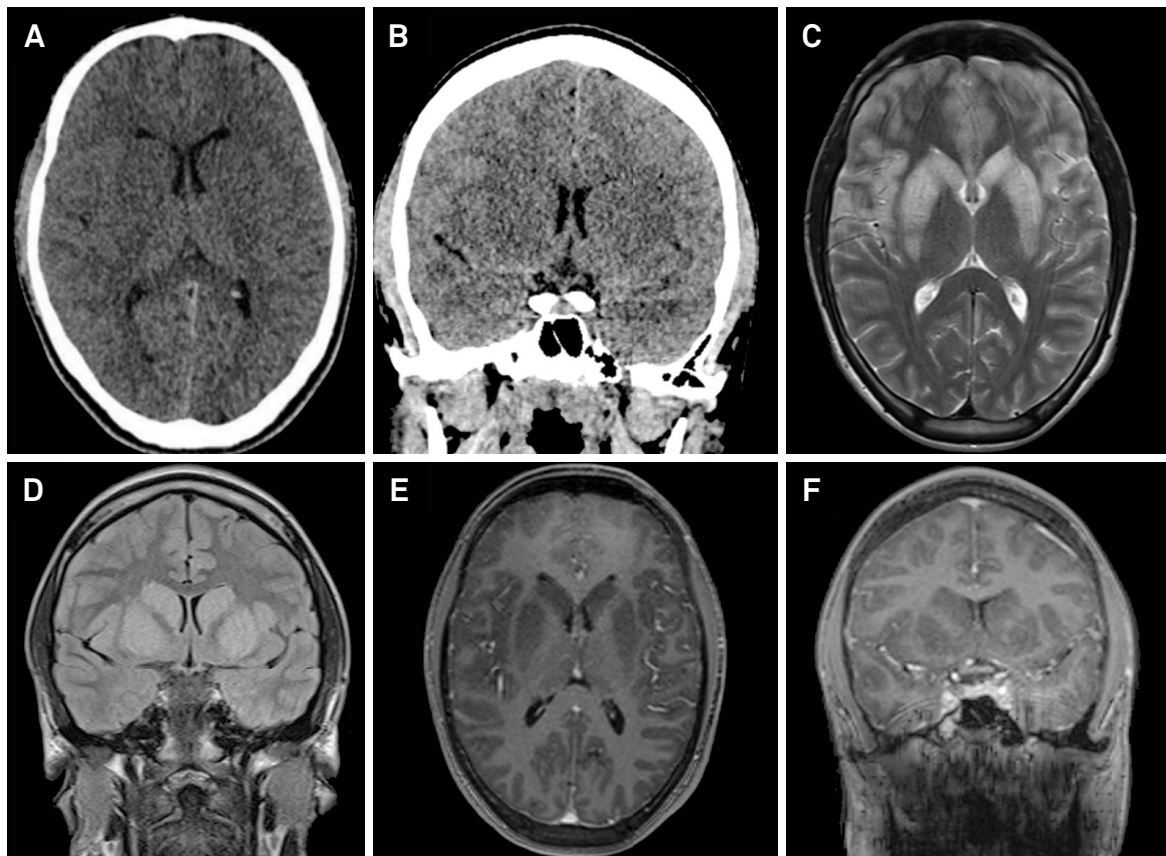
# Acute Epstein-Barr virus encephalitis in an immunocompetent adolescent patient

Encefalite aguda por virus Epstein-Barr em um paciente adolescente imunocompetente

Rodolfo Mendes Queiroz<sup>1</sup>, Lara Zupelli Lauar<sup>2</sup>, Cecília Hissae Miyake<sup>1,2</sup>, Lucas Giansante Abud<sup>1,2</sup>, Rafael Gouvêa Gomes de Oliveira<sup>1</sup>

A previously-healthy 16-year-old male presented with fever, headache, lethargy and seizures for a day. A hemogram showed mild lymphocytosis. Spinal fluid analysis revealed 75 leukocytes/mm<sup>3</sup> (62% neutrophils, 35% lymphocytes, 3% monocytes) and no growth of micro-organisms in culture. Cerebral imaging studies showed an abnormal bilateral symmetrical appearance of

the basal ganglia, which, together with positive IgG and IgM serology for the Epstein-Barr virus, suggested acute encephalitis by this agent (Figure). Some of the differential diagnoses were: hypoglycemia, hypoxia, intoxication (methanol, carbon monoxide, cyanide), herpes simplex infection, infantile bilateral striatal necrosis and central extrapontine myelinolysis<sup>1,2,3,4,5</sup>.



**Figure.** A and B. Computed tomography without administration of intravenous contrast showing the basal ganglia bilaterally ill-defined and discreetly hypodense compared to the cerebral cortex. Figures C, D, E and F. Magnetic resonance imaging of the brain show hyperintense basal ganglia bilaterally on T2-weighted sequence (C) and FLAIR (D), hypointense on T1 and without enhancement after administration of intravenous paramagnetic agent (E and F).

<sup>1</sup>Hospital São Lucas, MED - Medicina Diagnóstica, Radiologia e Diagnóstico por Imagem, Ribeirão Preto SP, Brasil;

<sup>2</sup>Universidade de São Paulo; Faculdade de Medicina de Ribeirão Preto; Hospital das Clínicas, Radiologia e Diagnóstico por Imagem, Ribeirão Preto SP, Brasil.

**Correspondence:** Rodolfo Mendes Queiroz; Rua Bernardino de Campos, 1426; 14015-130 Ribeirão Preto SP, Brasil; E-mail: rod\_queiroz@hotmail.com

**Conflict of interest:** There is no conflict of interest to declare.

Received 21 September 2016; Received in final form 24 March 2017; Accepted 15 April 2017.

## References

---

1. Bekiesinska-Figatowska M, Mierzevska H, Jurkiewicz E. Basal ganglia lesions in children and adults. *Eur J Radiol.* 2013;82(5):837-49. <https://doi.org/10.1016/j.ejrad.2012.12.006>
2. Bolis V, Karadedos C, Chiotis I, Chaliasos N, Tsabouri S. Atypical manifestations of Epstein-Barr virus in children: a diagnostic challenge. *J Pediatr (Rio J).* 2016;92(2):113-21. <https://doi.org/10.1016/j.jped.2015.06.007>
3. Saraiva M, Santos EC, Saraceni V, Rocha LLS, Monte RL, Albuquerque BC et al. Epidemiology of infectious meningitis in the State of Amazonas, Brazil. *Rev Soc Bras Med Trop.* 2015;48(1):79-86. <https://doi.org/10.1590/0037-8682-0116-2014>
4. Vidal LR, Almeida SM, Messias-Reason IJ, Nogueira MB, Debur MC, Pessa LFC et al. Enterovirus and herpesviridae family as etiologic agents of lymphomonocytary meningitis, Southern Brazil. *Arq Neuropsiquiatr.* 2011;69(3):475-81. <https://doi.org/10.1590/S0004-282X2011000400013>
5. Teive HAG, Zavala JAA, Iwamoto FM, Bertucci-Filho D, Werneck LC. Acute cerebellitis caused by Epstein-Barr virus: case report. *Arq Neuropsiquiatr.* 2001;59(3A):616-8. <https://doi.org/10.1590/S0004-282X2001000400027>