

Hereditary spastic paraplegia from 1880 to 2017: an historical review

Paraplegia espástica hereditária de 1880 a 2017: uma revisão histórica

Ingrid Faber¹, Eduardo Rafael Pereira², Alberto R. M. Martinez¹, Marcondes França Jr¹, Hélio Afonso Ghizoni Teive²

ABSTRACT

The authors have constructed a brief timeline of major clinical research related to hereditary spastic paraplegia (HSP). This timeline summarizes the evolution of HSP research, from the first clinical descriptions by Adolf von Strümpell in 1880 to the present day, with the transformation of these diseases into a rapidly-growing and heterogeneous group of neurogenetic diseases.

Keywords: hereditary spastic paraplegia; timeline; review.

RESUMO

Os autores constroem uma breve linha do tempo com as principais pesquisas clínicas relacionadas as paraplegias espásticas hereditárias. Desde a descrição clínica inicial em 1880, feita por Adolf von Strümpell, até os dias atuais com a transformação dessas doenças em um grupo de doenças neurogenéticas com grande variabilidade na apresentação fenotípica e genotípica.

Palavras-chave: paraplegia espástica hereditária; linha do tempo; revisão.

Hereditary spastic paraplegia (HSP) is a group of neurodegenerative monogenic disorders characterized by dysfunction of the longer tracts of the spinal cord: the corticospinal tract and, to a lesser extent, the posterior columns^{1,2,3,4}. This culminates in the key clinical aspects of HSP: spasticity of the lower limbs, followed by a – usually less severe – weakness, urinary urgency and decreased vibration sense^{1,2,3,4}. The HSP may segregate as autosomal dominant (AD-HSP), autosomal recessive (AR-HSP), X-linked or mitochondrial traits^{1,2,3,4}. On clinical grounds, one may present with a pure form of the disease, which is more frequent in families with an autosomal dominant inheritance pattern. On the other hand, a complex or complicated clinical picture, characterized by the presence of other neurological or non-neurological dysfunctions, is more frequently found in AR-HSP or X-linked HSP^{1,2,3,4}. These features encompass, for example, ataxia, parkinsonism, peripheral neuropathy, cognitive dysfunction, cataracts, and ichthyosis^{1,2,3,4,5,6,7}.

The diagnosis of an inherited spastic paraplegia is based essentially on the clinical picture, together with the investigation of other, potentially affected, members of the kindred. Exclusion of acquired myelopathies is fundamental in the absence of family history. Some conditions that can mimic

HSP are: human T-lymphotropic virus-related myelopathy, primary progressive multiple sclerosis, vitamin B12 deficiency, copper deficiency, spinal cord tumors or malformations and degenerative disorders of the spine^{4,5,6,7}. The presence of a family history or consanguinity strengthens the possibility of a hereditary condition; its absence, on the contrary, should not dissuade the clinician from the diagnosis^{1,2,3,4,5,6,7}. An apparently isolated case can be related to the occurrence of mildly affected family members, incomplete penetrance, false paternity or *de novo* mutations, for example.

In the last three decades, advances in molecular genetics have revealed that HSPs constitute a large and heterogeneous group of diseases^{4,5}. The knowledge of the key historical marks of HSPs may assist neurologists in understanding why a common ground of spasticity and weakness of the lower limbs has evolved into more than 80 different genetic subtypes. These frequently overlap clinically and/or genetically with other degenerative disorders such as ataxias, leukodystrophies, spinal muscular atrophy, amyotrophic lateral sclerosis (ALS) and peripheral neuropathies⁷. Historically, the differentiation between HSPs and inherited ataxias has been the most challenging. The most common ataxia worldwide, SCA3, as well as other autosomal dominant

¹Universidade Estadual de Campinas, Faculdade de Ciências Médicas, Departamento de Neurologia, Campinas SP, Brasil;

²Universidade Federal do Paraná, Hospital de Clínicas, Departamento de Medicina Interna, Serviço de Neurologia, Setor de Distúrbios do Movimento, Curitiba PR, Brasil.

Correspondence: Ingrid Faber; Rua Tessália Vieira de Camargo, 126; 13083-887 Campinas SP, Brasil; E-mail: ingridfaber81@gmail.com

Conflict of interest: There is no conflict of interest to declare.

Received 03 July 2017; Received in final form 21 August 2017; Accepted 24 August 2017.



ataxias (examples: SCA1, SCA2, SCA6, SCA7), are frequently accompanied by pyramidal signs, and spastic paraparesis can be the inaugural symptom^{8, 9, 10}. In regard to the AR group, absent reflexes are a hallmark of its most frequent subtype, Friedreich's ataxia. The late form of Friedreich's ataxia, beginning at age 25 or older, is alternatively associated with retained reflexes, and may present initially as spastic paraparesis^{11, 12}. The key to differentiating complicated HSP from ataxias with associated corticospinal tract dysfunction is to focus on the patient's main disabilities. As a rule, individuals with HSP are overtly spastic and have mild or no complaints relating to the upper limbs. Whereas, in the ataxia group, there is no pronounced dissociation between upper and lower limbs. Although useful on clinical grounds, more recently-discovered genes are increasingly challenging the neurologist's abilities to differentiate these conditions. An ever-growing number of genetic subtypes can present either with pure ataxia or pure spastic paraparesis, and a discordant phenotype can occur within the same family. Some examples of this overlap are: HSP-SPG7, autosomal recessive spastic ataxia of Charlevoix-Saguenay, HSP-SPG35, HSP-SPG46, cerebrotendinous xanthomatosis, Alexander's disease and spastic ataxias (SPAX 1 to 5)^{13, 14, 15, 16}.

Considering the complexity associated with the study of HSP, the present article is devoted to taking the reader through the most important discoveries in the field, from its original description in 1880, through to the challenges faced today. We have focused on the outstanding works regarding clinical, neuropathology, neuroimaging, neurophysiology, and genetics of these rare motor neuron disorders.

Hereditary spastic paraplegia – first descriptions

In 1880, the Baltic-German (region known today as Estonia and Latvia) neurologist Ernst Adolf Gustav Gottfried von Strümpell (Figure 1) published the first case series of patients with HSP. Strümpell reported on two siblings with a probable AD-HSP whose symptoms manifested at 37 and 56 years of age. Clinically, these patients showed a pure form of spastic paraplegia. After the death of one of the siblings, neuropathology showed degeneration of the lateral corticospinal tract, fasciculus gracilis and spinocerebellar tract^{17, 18}. Wilhelm Erb was probably the first to describe a condition dominated by limb spasticity. Although controversy persists, most authors today consider Erb's works to be the first description of primary lateral sclerosis. A case description by Otto Adolph Seeligmüller, in 1876, has long been disputed as the first description of HSP. Nevertheless, a critical analysis of Seeligmüller's publication highlighted that the patient studied had a clinical picture dominated by muscular atrophy and bulbar paralysis, features not suggestive of HSP itself. In 1888, Maurice Lorrain, a French neurologist, published a more detailed contribution to the anatomical and clinical study of HSPs; hence HSP also being known as Strümpell-Lorrain disease^{19, 20}.



(Extracted from <http://www.200.uk-erlangen.de/de/geschichte/20-koepfer-erlangeruniversitaetsmedizin/struempell/>, April 08th, 2017).

Figure 1. Ernst Adolf Gustav Gottfried von Strümpell (1853-1925).

Clinical phenotype

Rhein²¹ was the first, in 1916, to draw attention to the exquisite clinical heterogeneity some families with HSP displayed. His observations were accompanied by many case series describing pleomorphic clinical pictures encompassing: retinal degeneration^{22, 23}, dementia²⁴, extrapyramidal symptoms²⁵, mental handicap²⁶, hand amyotrophy²⁷ and other features. The term *Strümpell's familial spastic paraplegia* was reserved for families that displayed only spastic paraparesis, a condition that was thought to be much rarer²⁸. Currently, it is recognized that pure forms are more prevalent than complicated ones, their relatively benign clinical course, not affecting life expectancy, greatly contributed to their underdiagnosis at that time. Most epidemiological studies were based on postmortem or hospitalization records²⁹.

Anita Harding, a professor of neurology at the University of London, was an important pioneer in the field of molecular neurogenetics. In the 1980s, she published a series of groundbreaking works addressing HSP. In 1981, she presented what was, at the time, the largest investigation into pure HSP, with 22 families studied³⁰. Eighteen presented with AD-HSP, three were AR-HSP and, in the remaining kindred, the inheritance was uncertain due to the paucity of individuals affected. This work has consolidated the knowledge that pure subtypes of the disease are almost always dominantly inherited³⁰. Harding also shed light on the importance of examining first degree

relatives who considered themselves asymptomatic, as that practice unraveled AD-HSP in five of the 22 kindreds in this work³⁰. She also reinforced the knowledge that spasticity, and not weakness, is the main source of disability in this scenario, an aspect that remains useful in differentiating HSP from other myelopathies^{5,31}. Harding's major contribution to the field of HSP was published in *The Lancet* journal in 1983³². Entitled "Classification of the hereditary ataxias and paraplegias", this paper established an accurate differentiation between ataxias and HSP, providing a workable base for the etiological investigations that would come³². The now current clinical classification of HSP into pure and complicated forms was proposed. Harding defined that, besides the spastic paraparesis, additional mild signs such as vibration and segmental position sense deficits, slight distal amyotrophy and sphincter dysfunction were also conceivably present in the pure phenotype. Before this work, the literature had been confusing with regard to this topic. Pure HSP was subdivided into two groups according to age of onset, before or after 35 years of age. The complicated forms were recognized to be rarer and genetically heterogeneous. This work also provided refinement of the HSP phenotype, emphasizing the variability of disease progression, even within the same family. Sadly, Harding's outstanding career ended prematurely at the age 42 when she succumbed to a cancer³³. Professor Victor Dubowitz wrote, on the occasion of her obituary: "the neuromuscular world and, indeed, world neurology has lost one of its most colorful, most productive, and best-loved characters"³³.

In 2006, the German Network for Hereditary Spastic Paraplegia presented the spastic paraplegia rating scale, developed to quantify the disease progression clinically. Validated measures of disease severity are essential to understanding the disease's natural history. Additionally, by their ability to measure treatment impact, they are decisive in the development of future clinical trials³⁴.

Structural characterization: neuropathology and neuroimaging

While the clinical descriptions of HSP flourished during the 1980s, the pathological comprehension of the disease saw flourishing moments 100 years before. We return to Adolf von Strümpell, the first to identify the disease clinically, who was also the first to describe its pathological hallmarks six years later, in 1886³⁵. An unrelated case was also documented by him in 1904³⁶. Both pathological specimens showed degeneration of the corticospinal tract in the spinal cord with a distal-proximal gradient. Since then, the disease has been understood as a distal axonopathy of the longest large myelinated fibers of the spinal tract. In 1952, Schwarz³⁷ gave an extensive review of the pathologic literature, highlighting the contributions of Newmark (1904, 1906, 1911)³⁸, Jakob³⁹ and Kahlstorff⁴⁰, that culminated with the differentiation of Strümpell's disease from other conditions such as cerebellar ataxias and motor neuron disorders, establishing that, at first, lesions are restricted

to the spinal cord and affecting the corticospinal and posterior tracts⁴¹. In 2004, DeLuca and colleagues quantitatively examined the neuronal population of six HSP patients, the largest pathological report of the disease⁴². Marked symmetrical reduction in area and axonal density of the corticospinal tract in the lower regions of the spinal cord was found. On the other hand, sensory tracts demonstrated a significant reduction in area and axonal density only in the upper regions of the spinal cord. This supported the concept that the extent of axonal loss in HSP is tract-specific⁴².

In the past decade, neuroimaging techniques have emerged as powerful tools to investigate structural abnormalities in a wide variety of neurological disorders *in vivo*. In this field, Agosta et al.⁴³, were able to investigate a larger cohort. They demonstrated that microstructural brain abnormalities are rather diffuse and not restricted to motor pathways, when one analyzes multiple subtypes of HSP. Lindig⁴⁴ and Rezende⁴⁵, both in 2015, made substantial contributions to the delineation of the extent of neurodegeneration specifically associated with HSP-SPG4. Both authors showed correlations between white matter tract disruption and disease severity, indicating that diffusion tensor imaging measures could be used as biomarkers. Rezende and colleagues also demonstrated the absence of cortical thinning as a hallmark of this pure subtype of HSP^{44,45}. Regarding HSP-SPG11, both França et al.⁴⁶ and Pan et al.⁴⁷ revealed widespread white matter microstructural disruption. Pan et al. also demonstrated a distal-proximal gradient, whereas França et al. identified major deep grey matter volumetric loss^{46,47}.

Neurophysiology

At the same time that Anita Harding made her contributions to the HSP classification, Schady and colleagues⁴⁸ published their neurophysiological findings of central motorconduction studies by transcranial magnetic stimulation in HSP. The abnormalities found were worse in the lower than in the upper limbs, confirming neurological examination findings and strengthening the hypothesis made from observing pathological specimens in a length-dependent dysfunction⁴⁸.

Advances in genetics

After the accurate clinical classification developed by Harding³², the research involving HSP evolved from anecdotal case descriptions to the systematic study of families alike. Numerous HSP genetic studies have been published since the 1980s. Several genetic subtypes of HSP have been described and numbered sequentially, based on the order of the gene discovery (SPG1, SPG2, SPG3, etc.)¹.

In 1994, Jouet et al.⁴⁹, reported that three disorders; X-linked spastic paraplegia, MASA syndrome (mental retardation, aphasia, shuffling gait and adducted thumbs) and X-linked hydrocephalus were, in fact, allelic conditions, all resulting from mutations in the gene for neural cell adhesion molecule (*LICAM* or *SPG1*)⁴⁹. This was the first gene discovered that caused HSP; *LICAM* codes for an axonal

glycoprotein involved in neuronal migration and differentiation. Also in 1994, Hazan et al., identified the locus implicated in the majority of cases of dominantly inherited HSP. The *SPAST* or *SPG4* gene was cloned in 1999 by the same group and responds to up to 60% of AD-HSP⁵⁰. This gene encodes spastin, an AAA protein family member related to microtubule severing and endoplasmic reticulum morphogenesis, key factors in the process of intra-axonal transport⁵⁰.

In 1998, Griffiths and colleagues were the firsts to create an animal model of HSP⁵¹. They developed a mouse knockdown of proteolipoprotein (causing HSP-SPG2), unraveling the proteins critical role in maintaining the integrity of myelinated axons. Affected mice developed a clear spastic gait, related to fiber swelling and impaired axonal transport⁵¹. This model opened up a new window of understanding of the mechanisms through which corticospinal axons degenerate in HSP. During the same year, the first gene for autosomal recessive HSP was identified⁵², when the HSP-SPG7 gene was cloned. Paraplegin, encoded by the *SPG7* gene, localizes to the mitochondria, and ragged red muscle fibers (a typical finding in mitochondrial disease), and was readily detected in this work. Key findings suggestive of this phenotype encompass ataxia, ptosis, progressive external ophthalmoplegia and optic atrophy. The latter can also occur in isolation as an autosomal dominant trait⁵².

In 2007, *SPG11* was identified as the gene most commonly related to spastic paraplegia with mental impairment and thin corpus callosum. Stevanin, led by Brice and other colleagues, identified loss of function mutations affecting this gene in 11 families⁵³. Since then, HSP-SPG11 has been recognized as the most common AR-HSP. Surprisingly, *SPG11* mutations can also primarily present with other phenotypes, such as parkinsonism or ALS⁵⁴.

The next-generation sequencing techniques, encompassing gene panels, whole exome sequencing and whole genome sequencing have initiated a new era of knowledge in the field. The possibility of sequencing dozens, or hundreds, of genes simultaneously, has enormously increased the number of genes known and has expanded both the phenotype and genotype of HSP^{54,55}.

A brilliant example of the new possibilities opened up by this technology is the work done by Gaia Novarino et al., an Italian physician devoted to unraveling the molecular pathways of many neurological disorders⁵⁵. Novarino's work, published in *Science* in 2014, presented the discovery, and functional validation of, as many as 18 new HSP-related genes. Her investigations have also contributed to linking HSP-related genes to other degenerative disorders, especially ALS, Alzheimer's and Parkinson's diseases. Today, more than 80 different loci related to hereditary spastic paraplegias are recognized, with more than 50 genes already identified⁵⁶.

Brazilian contributions

Brazilian researchers have made substantial contributions to the field of HSP. Clinically, Teive et al.⁵⁷ described the first cases of HSP with thin corpus callosum in Brazil in 2001, at a time when very few families worldwide had been identified, other than in Japan⁵⁷. In 2007, a multinational group of researchers, including the Brazilian biologist Zatz, identified mutations causing HSP-SPG8⁵⁸. In 2014, França et al.⁵⁹ addressed the *SPG4* molecular epidemiology, confirming it as the most common HSP in Brazil⁵⁹. In 2015, Melo et al.⁶⁰ described the over-expression of the *KLC2* gene as the cause of spastic paraplegia with optic atrophy and neuropathy. This discovery was unique in the field, as it was the first HSP-related mutation to be documented in an untranslated region⁶⁰.

Final remarks

This article presents a comprehensive historical timeline of the scientific discoveries related to HSP (Figure 2). Ground zero was the first description of HSP made by Adolf von Strümpell in 1880, which outlined the clinical picture, the inheritance pattern and, later, the neuropathological findings of "pure" HSP¹⁷. DeLuca later reinforced the pathological discoveries of the 19th century in the largest pathological series of HSP ever reported⁴². The period from the early 20th century to the late 1970s was characterized almost exclusively by case descriptions of single individuals or families with spastic paraplegia as a common ground. It was only

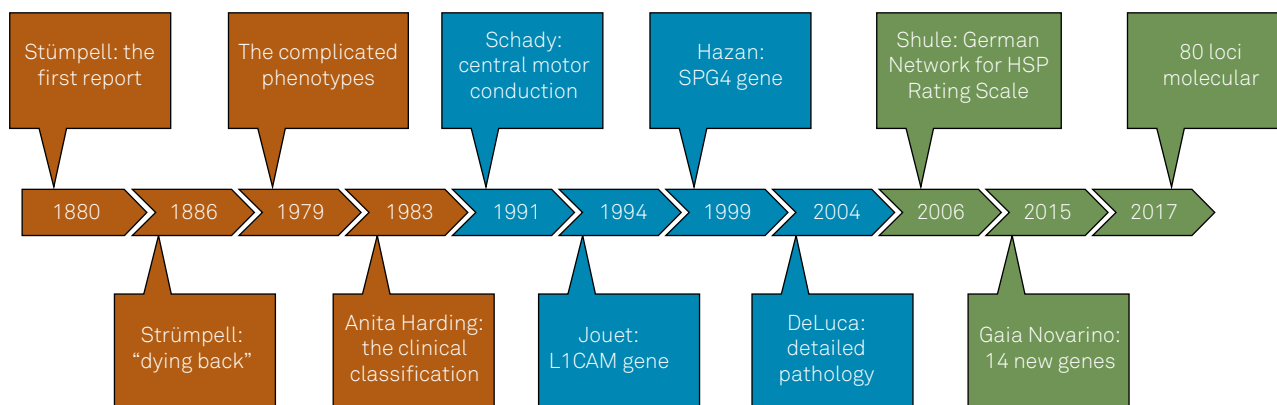


Figure 2. A brief timeline of clinical research related to HSP.

after Harding's studies in 1981 and 1983, that HSP acquired a more accurate clinical case definition and a classification based on clinical presentation and inheritance pattern^{30,32}. This classification, still useful today, heralded a period of systematic study of HSP. In 1991, Schady et al. were the firsts to report abnormal neurophysiological findings in patients with HSP⁴⁸. Jouet et al., in 1996, inaugurated the molecular era with his discovery of the first HSP gene⁴⁹. Griffiths et al., in 1998,⁵¹ developed the first animal model of the disease, unfolding a new technique of studying HSP biological pathways. As many as 50 leading world scientists have identified

HSP-related genes to -date, with most of them having been discovered in the last five years, since the advent of the next-generation sequencing techniques. Functional studies of the proteins encoded by these genes are now opening possibilities in the understanding of the biological processes, not only of HSP, but also of other degenerative disorders, such as ALS, peripheral neuropathies and spinal muscular atrophy^{55, 56}. The understanding of the molecular pathways of HSP, together with the establishment of disease biomarkers, will hopefully lead to a better, and more personalized, treatment for HSP patients.

References

- Fink JK. Hereditary spastic paraplegia: clinical principles and genetic advances. *Semin Neurol.* 2014;34(3):293-305. <https://doi.org/10.1055/s-0034-1386767>
- Klebe S, Stevanin G, Depienne C. Clinical and genetic heterogeneity in hereditary spastic paraplegias: from SPG1 to SPG72 and still counting. *Rev Neurol(Paris).* 2015;171 (6-7):505-30. <https://doi.org/10.1016/j.neuro.2015.02.017>
- Tesson C, Koht J, Stevanin G. Delving into the complexity of hereditary spastic paraplegias: how unexpected phenotypes and inheritance modes are revolutionizing their nosology. *Hum Genet.* 2015;134(6):511-38. <https://doi.org/10.1007/s00439-015-1536-7>
- Lo Giudice T, Lombardi F, Santorelli FM, Kawarai T, Orlacchio A. Hereditary spastic paraplegia: clinical-genetic characteristics and evolving molecular mechanisms. *Exp Neurol.* 2014;261:518-39. <https://doi.org/10.1016/j.expneurol.2014.06.011>
- Faber I, Servelhere KR, Martinez ARM, D'Abreu A, Lopes-Cendes I, França MC Jr. Clinical features and management of hereditary spastic paraplegia. *ArqNeuropsiquiatr.* 2014;72(3):219-26. <https://doi.org/10.1590/S0004-282X20130248>
- Souza PV, de Rezende Pinto WB, de Rezende Batistella GN, Bortholin T, Oliveira AS. Hereditary spastic paraplegia: Clinical and genetic hallmarks. *Cerebellum* 2017;16 (2):525-51. <https://doi.org/10.1007/s12311-016-0803-z>
- Müller vom Hagen J, Karle KN, Schüle R, Krägeloh-Mann I, Schöls L. Leukodystrophies underlying cryptic spastic paraparesis: frequency and phenotype in 76 patients. *Eur J Neurol.* 2014;21(7):983-8. <https://doi.org/10.1111/ene.12423>
- Teive HA, Iwamoto FM, Camargo CH, Lopes-Cendes I, Werneck LC. Machado-Joseph disease versus hereditary spastic paraplegia: case report. *ArqNeuropsiquiatr.* 2001;59(3B):809-11. <https://doi.org/10.1590/S0004-282X2001000500030>
- Pedroso JL, Souza PV, Pinto WB, Braga-Neto P, Albuquerque MV, Saraiva-Pereira ML et al. SCA1 patients may present as hereditary spastic paraplegia and must be included in spastic-ataxias group. *Parkinsonism RelatDisord.* 2015;21(10):1243-6. <https://doi.org/10.1016/j.parkreldis.2015.07.015>
- Synofzik M, Schüle R. Overcoming the divide between ataxias and spastic paraplegias: shared phenotypes, genes, and pathways. *MovDisord.* 2017;32(3):332-45. <https://doi.org/10.1002/mds.26944>
- Martinez AR, Moro A, Abrahao A, Faber I, Borges CR, Rezende TJ et al. Non neurological involvement in late-onset Friedreich ataxia (LOFA): exploring the phenotypes. *Cerebellum.* 2017;16 (1):253-56. <https://doi.org/10.1007/s12311-015-0755-8>
- Abrahão A, Pedroso JL, Braga-Neto P, Bor SengShu E, Carvalho PA, Barsottini OG. Milestones in Friedreich ataxia: more than a century and still learning. *Neurogenetics.* 2015;16:151-60. <https://doi.org/10.1007/s10048-015-0439-z>
- Bot ST, Willemsen MA, Vermeer S, Kremer HP, Warrenburg BP. Reviewing the genetic causes of spastic-ataxias. *Neurology.* 2012;79(14):1507-14. <https://doi.org/10.1212/WNL.0b013e31826d5fb0>
- Pedroso JL, Raskin S, Barsottini OGP, Oliveira ASB. Adult onset Alexander disease presenting with progressive spastic paraplegia. *Parkinsonism RelatDisord.* 2013;20(2):241-2. <https://doi.org/10.1016/j.parkreldis.2013.10.014>
- Rezende SA, Fernandes M, Munhoz RP, Raskin S, Schelp AO, Knaap MS et al. Cerebellar ataxia as the first manifestation of Alexander's disease. *ArqNeuropsiquiatr.* 2012;70(4):309-10. <https://doi.org/10.1590/S0004-282X2012000400018>
- Saute JA, Giugliani R, Merckens LS, Chiang JP, DeBarber AE, Souza CF. Look carefully to the heels! A potentially treatable cause of spastic paraplegia. *J Inherit Metab Dis.* 2015;38(2):363-4. <https://doi.org/10.1007/s10545-014-9745-0>
- Strümpell A. Beitrage zur Pathologie des Rückenmarks. *Arch PsychiatrNervenkr.* 1880;10(3):676-717. <https://doi.org/10.1007/BF02224539>
- Kolle K, editor. GroßeNervena"rzte, vol 3. Stuttgart: Thieme; 1963. Adolf Strümpell (1853–1925), p. 184–190.
- Seeligmüller AS. Sklerose der Seintenstränge des Rückenmarks bei vier Kindern derselben Familie. *Dtsch MedWochenschr.* 1876;2:185-6.
- Engmann B, Wagner A, Steinberg H. Adolf von Strümpell: a key neglected protagonist of neurology. *J Neurol.* 2012;259(10):2211-20. <https://doi.org/10.1007/s00415-012-6486-6>
- Rhein, JHW. Family spastic paralysis. *J NervMent Dis.* 1916;44(2):115-44,224-42.
- Jequier M, Streiff EB. Paraplégie, dystrophiesquelettique et dégénérescencetapéto-rétiniennefamiliales. *Archiv Julius Klaus-Stift ungVererbungsforschSozialanthropolRassenhyg.* 1947;22(3-4):129-67.
- Kjellin K. Familial spastic paraplegia with amyotrophy, oligophrenia and central retinal degeneration. *Arch Neurol.* 1959;1(2):133-40. <https://doi.org/10.1001/archneur.1959.03840020007002>
- Van Bogaert L. Studies on familial spastic paraplegia: classical forms with massive optic atrophy in certain members of the family of van L. and genetic considerations on spastic familial paraplegia. *ActaNeurolPsychiatr Belg.* 1952;52(12):795-807. French.
- Dick AP, Stevenson CJ. Hereditary spastic paraplegia: report of a family with associated extrapyramidal signs. *Lancet.* 1953;1(6767):921-3. [https://doi.org/10.1016/S0140-6736\(53\)92061-3](https://doi.org/10.1016/S0140-6736(53)92061-3)
- Johnston, AW, McKusick VA. A sex-linked recessive form of spastic paraplegia. *Am J Hum Genet.* 1962;14:83-94.
- Silver, JR. Familial spastic paraplegia with amyotrophy of the hands. *J NeurolNeurosurg Psychiatry.* 1966;29(2):135-44.

28. Behan WM, Maia M Strümpell's familial spastic paraplegia: genetics and neuropathology. *J NeurolNeurosurg Psychiatry*. 1974;37(1):8-20. <https://doi.org/10.1136/jnnp.37.1.8>
29. Bell J. On hereditary ataxia and spastic paraplegia. In: Lewis T, Bulloch W. *Treasury of human inheritance*. London: Cambridge University Press; 1939. Vol. 4, p. 141-281.
30. Harding AE. Hereditary "pure" spastic paraplegia: a clinical and genetic study of 22 families. *J NeurolNeurosurg Psychiatry*. 1981;44(10):871-83. <https://doi.org/10.1136/jnnp.44.10.871>
31. Salinas S, Proukakis C, Crosby A, Warner TT. Hereditary spastic paraplegia: clinical features and pathogenetic mechanisms. *Lancet Neurol*. 2008;7(12):1127-38. [https://doi.org/10.1016/S1474-4422\(08\)70258-8](https://doi.org/10.1016/S1474-4422(08)70258-8)
32. Harding AE. Classification of the hereditary ataxias and paraplegias. *Lancet* 1983;1(8334):1151-5. [https://doi.org/10.1016/S0140-6736\(83\)92879-9](https://doi.org/10.1016/S0140-6736(83)92879-9)
33. Dubowitz V. Anita Harding obituary. *NeuromuscDisord*. 1995;5(6):519-20. [https://doi.org/10.1016/0960-8966\(95\)90017-9](https://doi.org/10.1016/0960-8966(95)90017-9)
34. Schüle R, Holland-Letz T, Klimpe S, Kassubek J, Klopstock T, Mall V et al. The Spastic Paraplegia Rating Scale (SPRS): a reliable and valid measure of disease severity. *Neurology*. 2006;67(3):430-4. <https://doi.org/10.1212/01.wnl.0000228242.53336.90>
35. Strümpell A. Uebereinebestimmte Form der primären kombinierten Systemerkrankung des Rückenmarks. *Arch PsychiatrNervenkr*. 1886;17(1):227-38. <https://doi.org/10.1007/BF02172796>
36. Strümpell A. Die primäre Seitenstrangsklerose (spastische Spinalparalyse). *Deutsche ZtschrNerven*. 1904;27(3-4):291-339. <https://doi.org/10.1007/BF01667115>
37. Schwarz GA. Hereditary (familial) spastic paraplegia. *Arch Neurol Psychiatry*. 1952;68(5):655-62. <https://doi.org/10.1001/archneurpsyc.1952.02320230081010>
38. Newmark L. Klinischer Bericht über den siebenten Fall von spastischer Paraplegie in einer Familie und Ergebnis der dritten Autopsie aus derselben Familie. *Deutsche ZtschrNerven*. 1911;42(5-6):419-31. <https://doi.org/10.1007/BF01629416>
39. Jakob C. Sobre un caso de paraplegia espasmódica familiar progresiva con examen histopatológico completo. *Rev Soc Med Arg*. 1909;17:665-703.
40. Kahlstorf A. Klinischer und histopathologischer Beitrag zur hereditären spastischen Spinalparalyse. *Z Gesamte Neurol Psychiatr*. 1937;159(1):774-80. <https://doi.org/10.1007/BF02870699>
41. Fink JK. Advances in the hereditary spastic paraplegias. *Exp Neurol*. 2003;184 (suppl 1):S106-10. <https://doi.org/10.1016/j.jexpneurol.2003.08.005>
42. Deluca GC, Ebers GC, Esiri MM. The extent of axonal loss in the long tracts in hereditary spastic paraplegia. *Neuropathol Appl Neurobiol*. 2004;30(6):576-84. <https://doi.org/10.1111/j.1365-2990.2004.00587.x>
43. Agosta F, Scarlato M, Spinelli EG, Canu E, Benedetti S, Bassi MT et al. Hereditary spastic paraplegia: beyond clinical phenotypes toward a unified pattern of central nervous system damage. *Radiology*. 2015;276(1):207-18. <https://doi.org/10.1148/radiol.14141715>
44. Lindig T, Bender B, Hauser TK, Mang S, Schweikardt D, Klöse U et al. Gray and white matter alterations in hereditary spastic paraplegia type SPG4 and clinical correlations. *J Neurol*. 2015;262(8):1961-71. <https://doi.org/10.1007/s00415-015-7791-7>
45. Rezende TJ, de Albuquerque M, Lamas GM, Martinez AR, Campos BM, Casseb RF et al. Multimodal MRI-based study in patients with SPG4 mutations. *PLoS One*. 2015;10(2):e0117666. <https://doi.org/10.1371/journal.pone.0117666>
46. França MC Jr, Yasuda CL, Pereira FR, D'Abreu A, Lopes-Ramos CM, Rosa MV et al. White and grey matter abnormalities in patients with SPG11 mutations. *J NeurolNeurosurg Psychiatry*. 2012;83(8):828-33. <https://doi.org/10.1136/jnnp-2011-300129>
47. Pan MK, Huang SC, Lo YC, Yang CC, Cheng TW, Yang CC et al. Microstructural integrity of cerebral fiber tracts in hereditary spastic paraparesis with SPG11 mutation. *AJNR Am J Neuroradiol*. 2013;34(5):990-6. <https://doi.org/10.3174/ajnr.A3330>
48. Schady W, Dick JPR, Crampton SA. Central motor conduction studies in hereditary spastic paraplegia. *J NeurolNeurosurg Psych*. 1991;54(9):775-9. <https://doi.org/10.1136/jnnp.54.9.775>
49. Jouet M, Rosenthal A, Armstrong G, MacFarlane J, Stevenson R, Paterson J et al. X-linked spastic paraplegia (SPG1), MASA syndrome and X-linked hydrocephalus result from mutations in the L1 gene. *Nat Genet*. 1994;7(3):402-7. <https://doi.org/10.1038/ng0794-402>
50. Hazan J, Fonknechten N, Mavel D, Paternotte C, Samson D, Artiguenave F et al. Spastin, a new AAA protein, is altered in the most frequent form of autosomal dominant spastic paraplegia. *Nat Genet*. 1999;23(3):296-303. <https://doi.org/10.1038/15472>
51. Griffiths I, Klugmann M, Anderson T, Yool D, Thomson C, Schwab MH et al. Axonal swellings and degeneration in mice lacking the major proteolipid of myelin. *Science*. 1998;280(5369):1610-3. <https://doi.org/10.1126/science.280.5369.1610>
52. Casari G, De Fusco M, Ciarmatori S, Zeviani M, Mora M, Fernandez P et al. Spastic paraplegia and OXPHOS impairment caused by mutations in paraplegin, a nuclear-encoded mitochondrial metalloprotease. *Cell*. 1998;93(6):973-83. [https://doi.org/10.1016/S0092-8674\(00\)81203-9](https://doi.org/10.1016/S0092-8674(00)81203-9)
53. Stevanin G, Santorelli FM, Azzedine H, Coutinho P, Chomilier J, Denora PS et al. Mutations in SPG11, encoding spatacsin, are a major cause of spastic paraplegia with thin corpus callosum. *Nat Genet*. 2007;39(3):366-72. <https://doi.org/10.1038/ng1980>
54. Kara E, Tucci A, Manzoni C, Lynch DS, Eldidorou M, Bettencourt C et al. Genetic and phenotypic characterization of complex hereditary spastic paraplegia. *Brain*. 2016;139(7):1904-18. <https://doi.org/10.1093/brain/aww111>
55. Novarino G, Fenstermaker AG, Zaki MS, Hofree M, Silhavy JL, Heiberg AD et al. Exome sequencing links corticospinal motor neuron disease to common neurodegenerative disorders. *Science*. 2014;343(6170):506-11. <https://doi.org/10.1126/science.1247363>
56. Schüle R, Wiethoff S, Martus P, Karle KN, Otto S, Klebe S et al. Hereditary spastic paraplegia: clinicogenetic lessons from 608 patients. *Ann Neurol*. 2016;79(4):646-58. <https://doi.org/10.1002/ana.24611>
57. Teive HA, Iwamoto FM, Della Coletta MV, Camargo CH, Bezerra RD, Mingueti G et al. Hereditary spastic paraplegia associated with thin corpus callosum. *Arq Neuropsiquiatr*. 2001;59(3B):790-2. <https://doi.org/10.1590/S0004-282X2001000500025>
58. Valdmanis PN, Meijer IA, Reynolds A, Lei A, MacLeod P, Schlesinger D et al. Mutations in the KIAA0196 gene at the SPG8 locus cause hereditary spastic paraplegia. *Am J Hum Genet*. 2007;80(1):152-61. <https://doi.org/10.1086/510782>
59. França MC Jr, Dogini DB, D'Abreu A, Teive HA, Munhoz RP, Raskin S et al. SPG4-related hereditary spastic paraplegia: frequency and mutation spectrum in Brazil. *Clin Genet*. 2014;86(2):194-6. <https://doi.org/10.1111/cge.12252>
60. Melo US, Macedo-Souza LI, Figueiredo T, Muotri AR, Gleeson JG, Coux G et al. Overexpression of KLC2 due to a homozygous deletion in the non-coding region causes SPOAN syndrome. *Hum Mol Genet*. 2015;24(24):6877-85. <https://doi.org/10.1093/hmg/ddv388>