

How can neurophysiological studies help with movement disorders characterization in clinical practice? A review

Como os exames neurofisiológicos podem ajudar na caracterização dos transtornos do movimento na prática clínica? Uma revisão

Talyta GRIPPE^{1,2}, Natalia Spinola Costa da CUNHA³, Pedro Renato de Paula BRANDÃO⁴, Rubens Nelson Morato FERNANDEZ², Francisco Eduardo Costa CARDOSO⁵

ABSTRACT

Background: Neurophysiological studies are ancillary tools to better understand the features and nature of movement disorders. Electromyography (EMG), together with electroencephalography (EEG) and accelerometer, can be used to evaluate a hypo and hyperkinetic spectrum of movements. Specific techniques can be applied to better characterize the phenomenology, help distinguish functional from organic origin and assess the most probable site of the movement generator in the nervous system. **Objective:** We intend to provide an update for clinicians on helpful neurophysiological tools to assess movement disorders in clinical practice. **Methods:** Non-systematic review of the literature published up to June 2019. **Results:** A diversity of protocols was found and described. These include EMG analyses to define dystonia, myoclonus, myokymia, myorhythmia, and painful legs moving toes pattern; EMG in combination with accelerometer to study tremor; and EEG-EMG to study myoclonus. Also, indirect measures of cortical and brainstem excitability help to describe and diagnose abnormal physiology in Parkinson's disease, atypical parkinsonism, dystonia, and myoclonus. **Conclusion:** These studies can be helpful for the diagnosis and are usually underutilized in neurological practice.

Keywords: Movement Disorders; Neurophysiology; Dystonia; Tremor; Myoclonus.

RESUMO

Introdução: Os estudos neurofisiológicos são métodos auxiliares para compreender melhor as características e a natureza dos distúrbios do movimento. A eletromiografia (EMG), em associação com o eletroencefalograma (EEG) e o acelerômetro, podem ser utilizados para avaliar um espectro de movimentos hipo e hiperkinéticos. Técnicas específicas podem ser aplicadas para melhor caracterizar a fenomenologia, ajudar a distinguir a origem psicogênica da orgânica e avaliar o local mais provável de geração do movimento no sistema nervoso. **Objetivo:** Pretendemos fornecer ao clínico uma atualização sobre ferramentas neurofisiológicas úteis para avaliar distúrbios do movimento na prática clínica. **Métodos:** Revisão não sistemática da literatura publicada até junho de 2019. **Resultados:** Uma diversidade de protocolos foi encontrada e descrita. Dentre eles, inclui-se o uso de EMG para a definição do padrão de distonia, mioclonia, mioquímia, miorrítmia e *painfull legs moving toes*, além do uso de EMG em associação ao acelerômetro para avaliar tremor e, em associação ao EEG para avaliar mioclonia. Ademais, técnicas para medida indireta de excitabilidade cortical e do tronco encefálico ajudam a descrever e diagnosticar a fisiologia anormal da doença de Parkinson, parkinsonismo atípico, distonia e mioclonia. **Conclusão:** Esses estudos podem ser úteis para o diagnóstico e geralmente são subutilizados na prática neurológica.

Palavras-chave: Transtornos dos Movimentos; Neurofisiologia; Distonia; Tremor; Mioclonia.

¹Centro Universitário de Brasília, Faculdade de Medicina, Brasília DF, Brazil.



²Hospital de Base do Distrito Federal, Departamento de Neurologia, Brasília DF, Brazil.

³Hospital da Criança de Brasília, Departamento de Neuropediatria, Brasília DF, Brazil.

⁴Universidade de Brasília, Laboratório de Neurociência e Comportamento, Brasília DF, Brazil.

⁵Universidade Federal de Minas Gerais, Departamento de Clínica Médica, Unidade de Distúrbios do Movimento, Belo Horizonte MG, Brazil.

Talyta GRIPPE  <https://orcid.org/0000-0003-3126-8002>; Natalia Spinola Costa da CUNHA  <https://orcid.org/0000-0001-8829-8857>;

Pedro Renato de Paula BRANDÃO  <https://orcid.org/0000-0002-1191-2078>; Rubens Nelson Morato FERNANDEZ  <https://orcid.org/0000-0003-2978-0269>;

Francisco Eduardo Costa CARDOSO  <https://orcid.org/0000-000300808-0116>

Correspondence: Talyta Grippe; E-mail: talytagrippe@gmail.com

Conflict of interest: There is no conflict of interest to declare.

Received on September 09, 2019; Received in its final form on November 03, 2019; Accepted on November 18, 2019.

Since the 1970s, neurophysiological studies have emerged as complementary tools to better understand the features and the nature of movement disorders¹. Moreover, neurophysiological tests became useful to explore pathophysiological basis of neurological diseases², including different indirect measures of the brainstem and cortical excitability in Parkinsonism, dystonia, and myoclonus^{3,4}. They are also potential tools to clarify the origin of abnormal movements and to differentiate between organic and functional disorders, previously also referred as psychogenic disorders. Diverse techniques, such as *bereitschaftspotential*, back-averaging electroencephalogram-electromyography (EEG-EMG), and special studies using different paradigms for tremor can be applied for this function^{5,6,7,8}.

The definition of the type or origin of the movement is most of the times a critical necessity for the clinician, as it can guide treatment efforts through different pathways. The application of neurophysiological studies in clinical practice is currently below its potential capacity; the more commonly assessed conditions are painful legs moving toes, orthostatic tremor, and myoclonus, which have neurophysiological criteria included in diagnostic standards^{9,10,11}. A more widespread application in clinical practice would contribute to a better understanding of other conditions, including tremor, dystonia, and Parkinsonism, and possibly also play a role in refining the diagnosis, adding specific information about phenomenology. This review aims to draw a guide to clinicians to critically assess potentially helpful neurophysiological studies in the diagnosis of movement disorders.

TREMOR

Tremor is the most prevalent phenomenon in movement disorders clinics¹². The latest MDS consensus classifies tremor into two different axes, considering clinical features (axis 1) and etiology (axis 2). The clinical characteristics (axis 1) are crucial. An expert clinician should evaluate body distribution, activation context, and tremor frequency. These features help to classify the tremor into one of the commonly recognizable syndromes¹³. Electromyography (EMG) with surface electrodes can be placed on antagonist muscles, such as extensor carpi radialis (ECR) and flexor carpi ulnaris (FCU), together with an accelerometer, in order to evaluate tremor frequency, synchronous or alternating activity of antagonist muscles, burst duration, and frequency/amplitude variations induced by weight-bearing or posture change⁶.

To ascertain the clinical utility of electrophysiological evaluation of tremor, a study recruited 525 patients and compared neurophysiologically characterized tremors to specialists' clinical evaluations as the gold standard. The study used surface electrodes in antagonist muscles and measured the pattern, frequency, amplitude, and burst duration of contractions during tremor occurrence. To assure the stability of the measured features, patients were reevaluated three times in

one year. The results showed relevant reproducibility of the data through follow-up¹⁴. The electrophysiological features of tremors are represented in Table 1.

Another interesting study by Schwingenschuh and collaborators proposed an alternative criterion for functional tremor based on the combination of surface EMG and accelerometer recordings⁸. This criterion, as compared to clinical evaluation — the gold standard — showed high accuracy (specificity: 95.9%; sensitivity: 89.5%). With this technique, tremor analysis is performed while bearing weight, during distracting tasks (ballistic movements and finger tapping), and compared to the contralateral side. A final score higher than three correlates with functional tremor diagnosis (Table 2). A retrospective study with 210 patients used similar criteria and showed high specificity in distinguishing between functional, physiological, or essential tremor¹⁵.

Orthostatic tremor is a particular type of tremor usually explored with EMG. It is described as occurring only when standing and in a high frequency of 13-18 Hz¹³, with a muscular-muscular coherence, representing the one common central generator¹⁶. The neurophysiological study is indispensable for distinguishing orthostatic tremor from orthostatic myoclonus, which can be clinically very difficult to

Table 1. Neurophysiological features of common tremor syndromes¹⁴.

Tremor type	Pattern	Frequency (Hz)	Amplitude (mV)	Burst duration (ms)
Parkinsonian	Alternating	5-8	>0.1	50-150
Essential tremor	Synchronous/ Alternating	5-8	>0.1	50-150
Functional	Alternating	5-8	>0.1	50-150
Rubral	Alternating	<5	>0.1	>150

Table 2. Functional tremor criteria.

Feature	Points
Inability to maintain the finger tapping maneuver for 30 s in the less affected hand guided by a metronome in 1 (0.5-1.5) Hz	1
Inability to maintain the finger tapping maneuver for 30 s. in the less affected hand guided by a metronome in 3 (2.5-3.5) Hz	1
Inability to maintain the finger tapping maneuver for 30 s in the less affected hand guided by a metronome in 5 (4.5-5.5) Hz	1
Entrainment, suppression or pathologic shift of the tremor frequency during the finger tapping task	1
Interruption or reduction of greater than 50% of the tremor amplitude during the ballistic maneuver	1
Tonic coactivation of antagonist muscles 300 ms before tremor initiation	1
Bilateral coherence of the tremor	1
Increase in amplitude with weight	1

differentiate¹⁶. The orthostatic myoclonus has a median frequency range from 3–7 Hz, with usually burst duration of less than 50 ms. The most affected muscle is the tibial anterior with a synchronous activation of the homologous muscle¹⁷.

EMG could also help to distinguish tremor secondary to idiopathic PD from tremor secondary to drug-induced Parkinsonism. A study compared tremor characteristics from patients with drug-induced Parkinsonism caused by dopamine blockers, flunarizine, or valproate to patients with idiopathic PD. The latter showed an alternating tremor pattern, whereas drug-induced more commonly exhibited synchronous pattern, with longer burst duration, higher frequency, and smaller amplitude, as recorded with either surface or needle electrodes¹⁸.

PARKINSON'S DISEASE AND OTHER PARKINSONISMS

Many features other than tremor can be explored using neurophysiology in PD and related disorders. The blink reflex, for example, has been widely explored in this context. This measurement consists of stimuli in supraorbital nerves with ipsi and contralateral recording of orbicularis oculi muscle activity. Blink reflex demonstrates two responses: an early response, referred to as R1 (unilateral and oligosynaptic) and a late response, referred to as R2 (bilateral and polysynaptic). When paired supraorbital nerve stimulation is executed, the second R2 response is usually inhibited¹⁹. The degree of inhibition is more prominent with shorter interstimulus intervals. The ratio between the recovery cycle of the second and first response is a measure of inhibition within the internal brainstem networks, the basal ganglia, and the cortex, and is referred as the *R2 recovery cycle*. PD patients usually exhibit early R2 recovery with an interstimulus interval of about 125 ms, in comparison to control individuals that display an R2 recovery starting in the interval between 250 and 300 ms²⁴. This lack of inhibition, known as *enhanced R2 recovery cycle*, as shown in PD, is credited to the impaired function of interneurons and is indicative of a hyperexcitable brainstem². A recent study correlated the degree of enhancement with increased lateral flexion (Pisa syndrome) in PD²⁰.

Other brainstem neurophysiological tests can also help to differentiate PD from atypical Parkinsonism. It includes

trigeminal-cervical, *startle*, and palmomentary reflex^{4,21,22}. The trigeminal-cervical reflex is a short-latency EMG response from the sternocleidomastoid muscle evoked by trigeminal branches (supraorbital, infraorbital, and mentoneal) electrical stimulation²³. The recorded response has lower amplitude and higher latency (or is even absent) in patients with progressive supranuclear palsy (PSP) or PD and exhibits normal behavior in patients with multiple system atrophy (MSA)^{24,25,26}. No studies including corticobasal syndrome (CBS) were found. This lack of response suggests that there is a degeneration in the brainstem neural circuitries, mainly the reticulospinal pathways, that modulates this multisynaptic neck muscle withdrawal reflex in PD and PSP²⁴.

The startle reflex, by its turn, is a surface EMG response, integrated into the brainstem, and recorded after a sensory stimulation (auditory, electrical, or visual) in a sequence of selected muscles²⁷. The reflex starts at the sternocleidomastoid (SCM) level, propagates rostrocaudally, and it can be evidenced after that in orbicularis oculi, masseter, biceps brachii, abductor pollicis brevis, rectus femoris, tibialis anterior, and soleus depending on the established protocol²⁸. Of note, the first orbicularis oculi contraction before the SCM is part of the blink response and does not habituate²⁷. The response to auditory stimuli reveals shortened latency and higher amplitude in MSA, a reduced amplitude in PSP, and a prolonged latency in PD²⁸. The reduced amplitude found in PSP seems to be secondary to the loss of neurons in the lower pontine reticular formation. The delayed onset in PD may also be related to the withdrawal of facilitatory input to the brainstem from the basal ganglia²⁹.

The palmomentary reflex is a response recorded in mentalis and orbicularis oculi muscles after electrical stimulation of the median nerve²². Its behavior was studied in PD and atypical Parkinsonism, and a lack of response of ocular muscles was identified in PSP²². This specific alteration regarding PSP can be explained by the different pathways linking the limbs with the facial muscles, the first connect limbs to the lower facial motoneurons, and is composed by the corticonuclear tract, preserved in PSP. The second pathway connects to the upper facial motoneurons, including orbicularis oculi innervation, and is mediated by circuits of the interneurons in the brainstem reticular formation, which is affected in PSP patients³⁰. Table 3 shows a summary of the brainstem reflexes responses in each of these conditions.

Table 3. Brainstem reflexes response in PD and atypical Parkinsonism.

Condition vs. Reflex pattern	Blink reflex-paired stimuli	Startle reflex	Trigeminal-cervical reflex	Palmomentary reflex
PD	PR	A – Delayed	Reduced or absent	Mentalis/Orbicular
CBS	Normal	Not tested	Not tested	Mentalis/Orbicular
PSP	PR	A/SS – Reduced or absent	Reduced or absent	Mentalis
MSA	PR	A – Enhanced SS – Normal	Normal	Mentalis/Orbicular

MSA: multiple system atrophy; PSP: progressive supranuclear palsy; CBS: corticobasal syndrome; PR: precocious R2 recovery; A: auditory; SS: somatosensory.

Evoked potentials are another possible neurophysiological evaluation in PD. The visual evoked potential consists of recording the pathway of the vision from the retina until the occipital cortex using a visual stimuli and surface EEG electrodes. The auditory evoked potential consists of recording specific landmarks of the auditory pathway through ear, brainstem, and auditory cortex also using surface EEG. Moreover, the somatosensory potential consists of recording the electrical stimuli propagation through the nerve, spinal cord, brainstem, and parietal cortex with surface EEG electrodes³¹. In PD pattern, reversal visual and auditory evoked potential show prolonged latencies in some of its components (N75, P100, N145 in visual; III and IV in auditory) when compared to controls. This result highlights the impairment of these sensory systems in PD, corroborating a possible non-motor symptoms mechanism. The pathophysiological explanation seems to relate to brainstem damage but it is yet not clarified³². The somatosensory evoked potential shows a reduced N30 component in PD compared to controls, which might be partially restored with levodopa, apomorphine, or deep brain stimulation³³. The N30 component may represent a dopamine-dependent physiological marker of basal ganglia modulation of the cortical structures involved in central sensory processing³⁴.

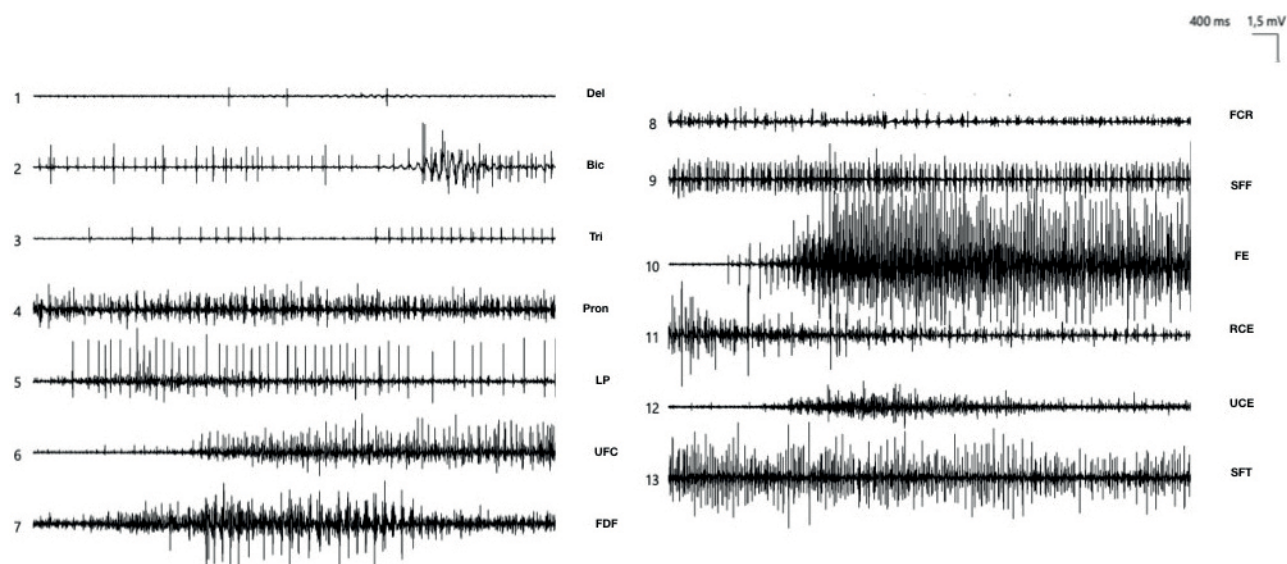
DYSTONIA

The dystonia phenomenology is diversified: contractions can be sustained, fixed, or intermittent, and can also be mixed with tremor. This tremor can be irregular, sometimes

presenting as jerks³⁵. The possibility of evaluating dystonia by applying neurophysiological techniques can complement clinical evaluation in many ways³⁵. EMG evaluation is useful in distinguishing dystonia from other types of tremor and myoclonus, detecting coactivation of antagonist muscles, and identifying the involved muscles and the effective disease topography³⁶. Moreover, this evaluation can include other measures, such as silent period, blink reflex, or H-reflex. These measures indirectly estimate cortical excitability or quantify a lack of inhibition in particular brain and spinal cord pathways in dystonic patients^{19,37,38}.

Among easily performed bedside neurophysiological tests for the evaluation of dystonia, one could describe the muscle contraction patterns with needle or surface EMG electrodes. Electrodes are placed in agonist and antagonist muscles involved in the abnormal posture, and tonic contraction activity is recorded simultaneously on both muscles. A muscle is considered dystonic if the following criteria are satisfied: 1) EMG displays consistent tonic or phasic patterns of discharge; 2) discharge amplitude is $>50\%$ of the amplitude during maximum voluntary activation; and 3) EMG discharge occurs in the presence of the patient's abnormal posture, as shown in Figure 1³⁹. Moreover, EMG can also be used to map the muscles more importantly involved during posture and to guide treatment with botulinum toxin^{36,39}.

The other possible techniques include the blink reflex, the cutaneous electromyographic silent period (CuSP), and the H-reflex, all of which show evidence of hyperexcitability. In cranial, focal, and generalized dystonia, there is a disinhibition of the paired blink reflex, a phenomenon also known as *enhanced R2 recovery cycle*⁴⁰. Thus, there is a modification



Source: author's archive. 1 – Deltoid; 2 – Biceps brachii; 3 – Triceps; 4 – Pronator Teres; 5 – Palmaris Longus; 6 – Flexor carpi ulnaris; 7 – Flexor digitorum profundus; 8 – Flexor carpi radialis; 9 – Flexor digitorum superficialis; 10 – Extensor digitorum communis; 11 – Extensor carpi radialis; 12 – Extensor carpi ulnaris; 13 – Flexor pollicis brevis.

Figure 1. Scale: 1500 microvolts/0.4 s. Patient with a complex right arm dystonia — Dystonic contraction was seen in an EMG concentric needle study more prominently in the pronator round, ulnar flexor of the carpus, superficial flexor of the fingers and short flexor of the thumb.

of the amplitude of early R1 and late R2 EMG components, which are enhanced. The duration of the R2 component is prolonged, with a shortened recovery cycle¹⁹. This abnormality is not reversed by botulinum toxin injections⁴¹, suggesting that the mechanism involved in the hyperexcitability is predominantly central.

The CuSP consists of a relative or absolute reduction of EMG activity after cutaneous stimulation of one nerve territory during the voluntary contraction of a muscle innervated by the same nerve. It can be evoked with a variety of external stimuli, e.g., mechanical, stretching of the muscle tendon, or electrical, stimulation of cutaneous or mixed nerves located in the same or a neighboring dermatome. This finding is due to numerous mechanisms involving sensory-motor integration at various CNS levels, including postsynaptic inhibition of spinal motoneurons; pre- or postsynaptic inhibition of spinal interneurons that relay corticospinal impulses and presynaptic inhibition of the corticospinal tract⁴². In patients with dystonia, both CuSP duration and latency are prolonged when electrical stimulation is applied in the ulnar and median nerves, reflecting a dysfunction of the basal ganglia timing influences over spinal circuitry⁴³.

Several techniques using forearm flexor muscles or the soleus H-reflex can be performed to study underlying pathophysiological mechanisms related to dystonia. The ratio of the maximal H-reflex to direct muscle potential (H/M ratio) is calculated after performing the H-reflex using a suprathreshold stimulus in order to obtain the maximal amplitude for the M and H waves. The vibratory inhibition is calculated by the ratio of an H-reflex performed during vibratory stimulus on the tendon and the maximal amplitude H-reflex without stimulus. And, the H-reflex recovery curves of dual stimuli is acquired by delivering double stimuli of equal intensity and 12 different randomly assigned inter-stimulus⁴⁴. There are, although, controversial findings on this subject, with the H/M ratio being unaltered comparing dystonic and controls on the majority of the studies performed⁴⁴. However, the vibration inhibition ratio was higher when comparing general dystonia

patients to focal dystonia and controls⁴⁵. And, regarding the H-reflex recovery curve, an increase in the late facilitatory component was found in lower limb, upper limb, and cervical dystonia patients, but not in hemidystonic patients^{44,45}.

Other studies to evaluate cortical excitability in dystonia can be performed using transcranial magnetic stimulation, but are outside the scope of this article. This issue is reviewed elsewhere⁴⁶.

MYOCLONUS

A myoclonus is a sudden and brief contraction (positive), or sudden and brief cessation of tonic muscle activity (negative)⁴⁷. It can have different origins from the cortex to the peripheral nerve, presenting different neurophysiologic and clinical characteristics. Neurophysiological studies are, once again, a critical tool for accurate diagnosis^{48,49,50}. The main features of the commonest myoclonus are summarized in Table 4.

Cortical myoclonus is found in a broad spectrum of metabolic disorders (such as uremic or hepatic encephalopathy), in Alzheimer's disease, and also in epilepsy. The movement is "shock-like," sensitive to stimulus, and usually descends through the body^{47,51}. EMG shows bursts with <50 ms of duration, that can have simultaneous or multifocal generators, with cranial-caudal progression, and a frequency varying from 8–20 Hz^{10,47}. It can be characterized neurophysiologically using features identified with jerk-locked back averaging, the C reflex, and somatosensory evoked potential, as detailed below^{47,52}.

The C reflex is a long loop-reflex, in which an electrical stimulus elicits a transcortical reflex, also called cortical myoclonus reflex⁵³. This reflex is composed by the afferent signal that propagates through the lemniscal pathway to the somatosensory cortex, which in turn activates the primary motor cortex thus generating a muscular contraction⁴⁸. Its execution requires the stimulation of the peripheral nerve,

Table 4. Neurophysiology patterns for distinct myoclonus generators.

Myoclonic location	Burst duration	Spreading pattern	Stimulus-sensitive	EEG	Reflex response
Peripheral	<50 ms	In one or more myotome segments	No	No changes	None
Spinal (Segmental)	>100 ms	In one or two contiguous spinal segments	No	No changes	None
Spinal (Propriospinal)	<1000 ms	Rostral and caudal spread	Yes	No changes	None
Subcortical (Reticular)	20–70 ms	Ascending to the brainstem and descending to the spinal cord	No	No changes	None
Subcortical (Exaggerated startle response)	>75 ms	Rostral and caudal spread	Yes	No changes	None
Cortical	<50–100 ms	From rostral to caudal segments	Yes	20 ms before cortical activity	Presence of C reflex

whereas its long latency abnormal response is captured on the corresponding muscle, that co-occurs with an electrically evoked myoclonic jerk⁴⁸. It can be registered at the thenar muscle by stimulating the median nerve at the wrist, with an expected latency of 45 to 55 ms. Alternatively, it can be recorded in the plantar foot muscles after stimulating the posterior tibial nerve, with a medium latency of 103 ms⁵⁴. In a retrospective study evaluating patients with myoclonus, it was present in 72% of patients with cortical myoclonus induced by mixed etiologies⁵². The presence of these reflex in cortical myoclonus is believed to be due to cortical hyperexcitability⁴⁷.

The BP represents an early cortical activation preceding voluntary movements⁵. To assess this activity, one should process preceding movement EEG trace in a software program that averages the prior segment for at least 40 trials. BP can be divided into subcomponents according to the scalp region that correspond to the supplementary motor area and starts about two seconds before EMG-registered movement⁵. This method helps distinguishing voluntary or functional from involuntary or organic movements, such as jerks. If the cortical activation is present immediately before the movement-related EMG signal, the presence of the BP is marked and it characterizes the movement as a mimicked or functional jerk. This pre-activation reflects preparatory activities arising from the supplementary motor area, characterizing the movement as voluntary^{47,55}. A cross-sectional case series study ratified this possible use, revealing that the presence of this element was significantly more frequent before the functional jerks and not registered in any of the patients with organic etiologies⁵⁶, justifying the practical use of this tool as previously explained.

There is also a possible EEG discharge element before the muscle contraction corresponding to an organic cortical myoclonic jerk⁴⁸. However, the latency of the cortical myoclonus is much shorter (10–25 ms) than that described in the BP (1.7–2 s)⁷. Moreover, it can be a practical tool to help locate the myoclonic generator, which is not restricted to the central areas as in BP. It can also include parietal and frontal zones⁵⁷. Also referred as *jerk-locked back averaging*, the electrophysiological signature of cortical myoclonus is a short-latency cortical positivity preceding myoclonus onset⁵⁸. This exam is used to differentiate between cortical and non-cortical myoclonus, in the context of an already proved organic origin.

The somatosensory evoked potentials (SSEPs) was first recorded in myoclonus in 1946, when Dawson found that electrical shocks delivered to the peripheral nerve in a patient with myoclonic epilepsy generated a response on the EEG with an enlarged amplitude⁵⁹. From that point on, SSEPs started to be used routinely for the study of myoclonus, mainly for stimulus-sensitive myoclonus¹⁰. SSEPs are classically recorded using median nerve stimulation for the upper limbs and posterior tibial nerve stimulation for the lower limbs. Cortical waves, produced by median nerve stimulation

and sent through contralateral centroparietal electrodes, constitute a negative wave at 20 ms (N20), a positive wave at 25 ms (P25), and another negative wave at 33 ms (N33). A significant enlargement of the P25–N33 deflection, usually ten times above normative value, is defined as a giant SSEP⁶⁰. In a retrospective study, giant SSEPs was encountered in 61% of patients with cortical myoclonus, showing that they are a supportive criterion for this type of myoclonus⁵². Giant SSEP corresponds to enhanced excitability of the somatosensory cortex and supports a cortical origin for the myoclonus⁴⁷.

Subcortical myoclonus may be generated in the basal ganglia, brainstem, or cerebellum^{48,51}. Reticular myoclonus is a specific type of brainstem myoclonus. It has a distinctive muscle activation order, ascending in the brainstem and descending in the spinal cord⁶. Its burst has a duration of 20–70 ms and happens on rest, spontaneously, and propagates in high speed (approximately 40 m/s). Its fast propagation reflects stimuli conduction through the reticulospinal tract^{6,47,61}. The main etiology is post-hypoxic (Lance-Adams syndrome)⁶².

Other subcortical myoclonus are found in other conditions such as hyperekplexia, myoclonus-dystonia, essential myoclonus, and periodic myoclonus^{47,51}. Hyperekplexia is an exacerbated *startle* response, with a burst duration of >75 ms, slow propagation speed, and bidirectional spreading. It is mostly evoked by sudden noise or light⁶. In essential myoclonus, the myoclonus is the most prominent or only clinical finding⁶³. It can be idiopathic or genetic, the sporadic cases are very heterogeneous with regard to distribution and other examination findings, with segmental or multifocal distribution and usually irregular nature^{10,63}. The essential myoclonus genetic syndrome has also been found to have features of dystonia and classified as myoclonus-dystonia, most of the times secondary to a mutation in chromosome 7, also known as DYT-11^{64,65}, in the epsilon-sarcoglycan (SGCE) gene. The myoclonus present in myoclonus-dystonia is mostly action-activated, not responsive to somesthetic stimuli, isolated or arrhythmic, with a mean duration of 100 ms and a negative C reflex^{65,66}. Periodic myoclonus is seen typically in patients with Creutzfeldt-Jakob disease or subacute sclerosing panencephalitis, usually in association with periodic synchronous discharges (PSDs) on electroencephalogram, with periodic discharges on EMG^{10,47}.

The spinal myoclonus denomination includes propriospinal and segmental spinal myoclonus⁶³. The propriospinal myoclonus consists of arrhythmic brief jerks of the trunk, hips, and knees in a fixed pattern⁶⁷. It includes activity over extensive lengths of the spinal cord, rostral and caudal spread with a relatively slow speed (approximately 10 m/s), consistent with the spread within the propriospinal tract^{51,67}. Movements get worst with the lying position and are preceded by a premonitory sensation⁶⁸. EMG shows synchronous activation of agonist and antagonist muscles with a burst duration of less than 1000 ms and no facial involvement⁶⁷.

The propriospinal myoclonus is a functional movement disorder in most cases. The use of the BP described in detail earlier, may help to define the etiology of this myoclonus⁵⁶. The segmental myoclonus is indicative of a focal structural lesion; jerks are usually rhythmic (2 Hz), unilateral or bilateral, involve a few contiguous segments of the spinal cord, are not stimulus-sensitive and tend to persist during sleep⁶. The bursts are approximately 100 ms in length⁶³.

Peripheral myoclonus is associated with nerve or plexus injury. A jerky repetitive movement disorder may arise, that is either highly specific to the muscles corresponding to the damaged nerve, unilaterally, bilaterally, or more widespread within the innervated myotome⁴⁷. EMG shows a burst duration of <50 ms and can also show signs of denervation, fasciculation, or giant motor unit action potentials (MUAPs)^{49,50}. Although the burst duration is similar to cortical myoclonus, the recording of agonist and antagonist muscles suggests a cortical generator, with a synchronous involvement of them not seen in peripheral myoclonus¹⁰. Another myoclonus presentation that can also have a peripheral generator is minipoly-myoclonus, a frequent and independent contraction of multiple small muscles of distal limbs¹⁰. It is defined by an irregular 1-20 Hz activity with muscle synchronous bursts of 25–50 ms in duration and can also have a central generator, which can be differentiated from the peripheral by the presence of EEG elements and muscle denervation, respectively^{64,69}.

Hemifacial spasm (HFS) is a typical example of peripheral myoclonus⁶³ that is marked by spontaneous, unilateral synchronous, and intermittent twitching of one side of the face, which also happens during sleep^{70,71}. It is due to an irritative lesion induced in the facial nerve at its root zone in the posterior fossa, by a neighboring structure, typically a blood vessel^{70,72}. EMG usually shows a paroxysmal abnormal contraction, consisting of rapid, irregular clonic bursts of activity, involving the lower and upper facial muscles simultaneously⁷³. The responses in blink reflex reinforce the hypothesis of hyperexcitability of the nerve or brainstem and help to distinguish HFS from an involuntary mass contraction after a post paralytic facial syndrome. This syndrome presents myokymic discharges with a lower frequency and more irregularity in EMG — Figure 2^{70,73}. Supraorbital stimulation ipsi or contralateral to the affected side provokes a larger R2 response compared to the other side in HFS, whereas the post paralytic facial syndrome patients have a decreased R2 response ipsilateral to the facial paralysis⁷⁰. Moreover, the paired stimulus technique shows an *enhanced R2 recovery cycle* in HFS, similar to that which was previously described in PD and dystonia³.

MYOKYMIA

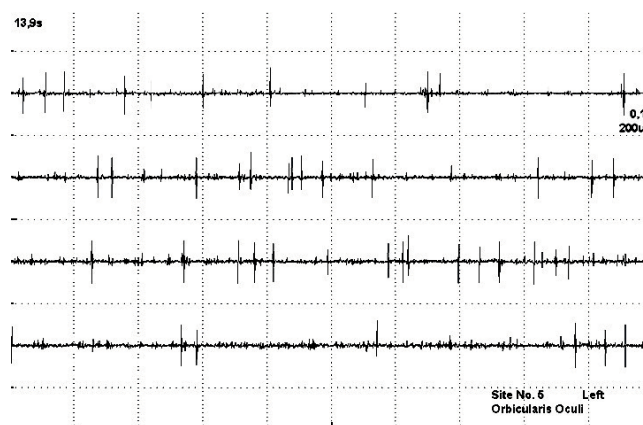
Myokymia consists of an undulating muscle movement that resembles tiny snakes wriggling beneath the skin. It may

be clinically challenging to distinguish them from fasciculations⁷⁴. Myokymia is characterized by spontaneous discharges of a single motor unit potentials firing at rates of 5-150 Hz, which might appear as doublets, triplets, or multiplets. After the burst, there are short periods of silence, followed by the repetition of the same burst with regular or irregular intervals (Figure 2)⁷⁵. Neuromyotonic discharges are analogous, with higher frequencies, often with abrupt initiation and ending. They are considered as having the same underlying mechanism as myokymia⁷⁵ and are differentiated from fasciculations, which are random single motor units with no tetanic bursts or rhythmic quality, with a mean duration of 1-5 ms and usually a triphasic morphology⁷⁶.

Myokymic discharges are not necessarily associated with overt clinical movements. They are believed to reflect hyperexcitability coming from the anterior horn or axon cells membrane⁷⁷. Myokymia can be found in individuals with peripheral nerves hyperexcitability syndromes such as Isaacs, cramp-fasciculation, and Morvan⁷⁴. Other possible etiologies are radiotherapy, multiple sclerosis, episodic ataxias, motor neuron disease, facial nerve paralysis, and Guillain-Barré syndrome, and it can even be induced by exercise in a healthy individual^{73,75}.

MYORHYTHMIA

Myorhythmia is a hyperkinetic movement characterized by slow (1-4 Hz), repetitive, jerky, and rhythmic movements. It usually affects cranial or limb muscles and disappears during sleep^{78,79}. There are numerous etiologies, compromising mainly the brainstem. However, the definition of this entity is one of the problems that impedes its correct identification of this movement. The etiologies include not only Whipple's disease, with the well-characterized



Source: author's archive.

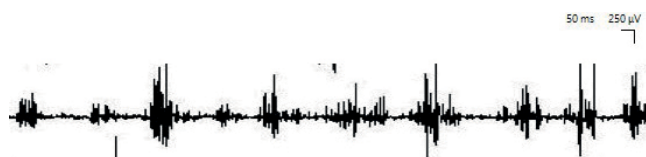Figure 2. Scale: 200 microvolts/0.1 sec. Patient with post paralytic facial syndrome presenting myokymic discharges with a lower frequency and more irregularity in EMG of the left orbicularis oculi muscle.

oculomastigatory myorhythmia, but also autoimmune encephalitis, stroke, paraneoplastic syndromes, head trauma, multiple sclerosis, drugs, Lubag disease, or alcoholic cerebellar degeneration^{78,80}.

EMG shows alternating or synchronous contractions of antagonist muscles, with a burst duration of approximately 200 ms and an inter-burst frequency of 1-4 Hz, occurring mainly at rest or during posture maintenance (Figure 3). When occurring in multiple body parts, the synchronicity reveals a unique pacemaker. If the pattern is asynchronous, the movement is presumably produced by distinct supraspinal pacemakers⁷⁸. This abnormal movement may resemble Holmes tremor, but the Holmes tremor has a rest and kinetic component, while myorhythmia presents mainly at rest⁸¹.

PAINFUL LEG MOVING TOES

Painful legs moving toes is characterized by a deep aching and pulling pain in the feet or lower leg with spontaneous and purposeless movements of the toes, which can be stopped by the patient only for a few seconds¹. In neurophysiologic studies, this is a syndrome with extensive variation, reflecting clinical practice. On EMG registers, movements are described as random and irregular, with either continuous, semi-continuous, or intermittent contractions that can change in response to movement and posture, including suppression while standing. EMG captures



Source: Author's archive.

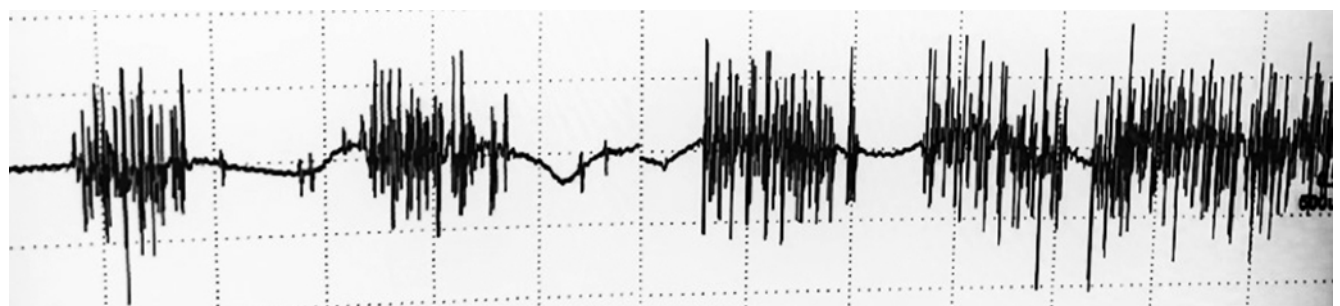
Figure 3. Scale: 250 microvolts/0.05 s. Myorhythmia with 3–3.5 Hz rhythmic bursts, lasting approximately 200 ms, with activity corresponding to muscle contractions in the right masseter while the patient was at rest.

bursts lasting from 80 to 2000 ms, with a frequency ranging from 1-2 Hz^{9,82}. Some brief parts of the movement register are described as semi-rhythmic movements of 0.5-1 Hz^{9,83}. Another important finding is the co-contraction, sometimes erratic, occurring in antagonist muscles that are of shorter duration (10-80 ms), lower amplitude, and higher frequency (4-6 Hz) (Figure 4)⁹.

Needle EMG usually reveals a reduced recruitment pattern, together with neurogenic motor unit potentials when lesions from the anterior horn to the peripheral nerve are the primary cause⁸³. Moreover, in addition to the reduced recruitment pattern found on EMG electrode, the conduction studies in some cases also reveal abnormalities on sensory nerve action potentials (SNAP) and compound muscle action potentials (CMAP). The most prevalent findings are prolonged action potential's latency and duration, lower amplitude, and conduction velocity, highlighting the possibility of a concomitant sensory-motor neuropathy. Lastly, a continuous myokymia pattern may occur in association with hypertrophic neuritis of the tibial nerve^{9,84}.

CONCLUSIONS

The neurophysiology laboratory provides useful tools to complement the clinical examination and allow better exploration of the phenomenology of different types of movement disorders. The first contribution of neurophysiological studies is to help better define the phenomenology of the growing spectrum of movement disorders. Clinical neurophysiology also helps to define the anatomical origin of the movement disorder. This is particularly relevant in myoclonus. However, it is important to stress that these techniques are not always completely reliable, as they are complementary tools and false negative results are a possibility that clinicians should keep in mind. Finally, neurophysiological studies have a growing role in distinguishing functional from "organic" movement disorders. More studies are needed in order to establish clear-cut parameters and develop international guidelines.



Source: Author's archive.

Figure 4. Scale: 500 microvolts/ 0.2s. Irregular bursts with a variable duration of 200–600ms, and an irregular frequency of 0.5–2 Hz, recorded at the extensor digitorum brevis muscle. Patient has a diagnosis of painful legs moving toes.

References

1. Spillane JD, Nathan PW, Kelly RE, Marsden CD, Square Q. Painful legs and moving toes. *Brain*. 1971;94(3):541-56. <https://doi.org/10.1093/brain/94.3.541>
2. Kimura J. Disorder of Interneurons in Parkinsonism. *Brain*. 1973;96(1):87-96.
3. Valls-Solé J, Tolosa ES. Blink reflex excitability cycle in hemifacial spasm. *Neurology*. 1989 Aug;39(8):1061-6. <https://doi.org/10.1212/wnl.39.8.1061>
4. Valls-Solé J. Neurophysiological characterization of parkinsonian syndromes. *Neurophysiol Clin*. 2000 Dec;30(6):352-67. [https://doi.org/10.1016/s0987-7053\(00\)00236-7](https://doi.org/10.1016/s0987-7053(00)00236-7)
5. Shibasaki H, Hallett M. What is the Bereitschaftspotential? *Clin Neurophysiol*. 2006 Nov;117(11):2341-56. <https://doi.org/10.1016/j.clinph.2006.04.025>
6. Park H-D, Kim H-T. Electrophysiologic assessments of involuntary movements: tremor and myoclonus. *J Mov Disord*. 2009;2(1):14-7. <https://doi.org/10.14802/jmd.09004>
7. Hallett M. Neurophysiological studies of functional neurologic disorders. 1 *Handb Clin Neurol*. 2016;139:61-71. <https://doi.org/10.1016/B978-0-12-801772-2.00006-0>
8. Schwingsenschuh P, Saifee TA, Katschnig-Winter P, Macerollo A, Koegl-Wallner M, Culea V, et al. Validation of "laboratory-supported" criteria for functional (psychogenic) tremor. *Mov Disord*. 2016 Apr;31(4):555-62. <https://doi.org/10.1002/mds.26525>
9. Reich SG. Painful legs and moving toes. *Handb Clin Neurol*. 2011;100:375-83. <https://doi.org/10.1016/B978-0-444-52014-2.00029-X>
10. Shibasaki H, Hallett M. Electrophysiological studies of myoclonus. *Muscle Nerve*. 2005 Feb;31(2):157-74. <https://doi.org/10.1002/mus.20234>
11. Rigby HB, Rigby MH, Caviness JN, Clinic M. Articles orthostatic tremor: a spectrum of fast and slow frequencies or distinct entities? *Tremor Other Hyperkinet Mov (N Y)*. 2015 Aug;5:324. <https://doi.org/10.7916/D8S75FHK>
12. Louis ED, Ferreira JJ. How common is the most common adult movement disorder? Update on the worldwide prevalence of essential tremor. *Mov Disord*. 2010 Apr;25(5):534-41. <https://doi.org/10.1002/mds.22838>
13. Bhatia KP, Bain P, Bajaj N, Elble RJ, Hallett M, Louis ED, et al. Consensus Statement on the classification of tremors. from the task force on tremor of the International Parkinson and Movement Disorder Society. *Mov Disord*. 2018 Jan;33(1):75-87. <https://doi.org/10.1002/mds.27121>
14. Milanov I. Electromyographic differentiation of tremors. *Clin Neurophysiol*. 2001 Sep;112(9):1626-32. [https://doi.org/10.1016/s1388-2457\(01\)00629-0](https://doi.org/10.1016/s1388-2457(01)00629-0)
15. van der Stouwe AMM, Elting JW, van der Hoeven JH, van Laar T, Leenders KL, Maurits NM, et al. How typical are 'typical' tremor characteristics? Sensitivity and specificity of five tremor phenomena. *Parkinsonism Relat Disord*. 2016 Sep;30:23-8. <https://doi.org/10.1016/j.parkreldis.2016.06.008>
16. Hassan A, van Gerpen JA. Orthostatic Tremor and orthostatic myoclonus: weight-bearing hyperkinetic disorders: a systematic review, new insights, and unresolved questions. *Tremor Other Hyperkinet Mov (N Y)*. 2016;6:417. <https://doi.org/10.7916/D84X584K>
17. van Gerpen JA. A Retrospective study of the clinical and electrophysiological characteristics of 32 patients with orthostatic myoclonus. *Parkinsonism Relat Disord*. 2014 Aug;20(8):889-93. <https://doi.org/10.1016/j.parkreldis.2014.05.006>
18. Nisticò R, Fratto A, Vescio B, Arabia G, Sciacca G, Morelli M, et al. Tremor pattern differentiates drug-induced resting tremor from Parkinson disease. *Parkinsonism Relat Disord*. 2016;25:100-3. <https://doi.org/10.1016/j.parkreldis.2016.02.002>
19. Berardelli A, Rothwell JC, Day BL, Marsden CD. Pathophysiology of blepharospasm and oromandibular dystonia. *Brain*. 1985 Sep;108(Pt 3):593-608. <https://doi.org/10.1093/brain/108.3.593>
20. Sugiyama T, Mochizuki H, Hara Y, Miyamoto M, Nakazato Y, Taniguchi A, et al. Disinhibited blink reflex recovery is related to lateral trunk flexion in parkinson disease. *J Clin Neurophysiol*. 2018 Jul;35(4):346-50. <https://doi.org/10.1097/WNP.0000000000000457>
21. Bologna M, Suppa A, Di Stasio F, Conte A, Fabbrini G, Berardelli A. Neurophysiological studies on atypical parkinsonian syndromes. *Park Relat Disord*. 2017 Sep;42:12-21. <https://doi.org/10.1016/j.parkreldis.2017.06.017>
22. Valls-Solé J, Valldeoriola F, Tolosa E, Marti MJ. Distinctive abnormalities of facial reflexes in patients with progressive supranuclear palsy. *Brain*. 1997 Oct;120(Pt 10):1877-83. <https://doi.org/10.1093/brain/120.10.1877>
23. Di Lazzaro V, Restuccia D, Nardone R, Tartaglione T, Quartarone A, Tonali P, et al. Preliminary clinical observations on a new trigeminal reflex: The trigemino-cervical reflex. *Neurology*. 1996 Feb;46(2):479-85. <https://doi.org/10.1212/wnl.46.2.479>
24. Bartolo M, Serrao M, Sandrini G, Pierelli F. Lack of trigemino-cervical reflexes in progressive supranuclear palsy. *Mov Disord*. 2008 Jul;23(10):1475-9. <https://doi.org/10.1002/mds.22039>
25. Perrotta A, Serrao M, Bartolo M, Valletta L, Locuratolo N, Pujia F, et al. Abnormal head nociceptive withdrawal reaction to facial nociceptive stimuli in Parkinson's disease. *Clin Neurophysiol*. 2005 Sep;116(9):2091-8. <https://doi.org/10.1016/j.clinph.2005.05.011>
26. Serrao M, Di Fabio R, Bartolo M, Perrotta A, Tassorelli C, Coppola G, et al. The contribution of trigemino-cervical reflexes in distinguishing progressive supranuclear palsy from multiple system atrophy. *Clin Neurophysiol*. 2011 Sep;122(9):1812-5. <https://doi.org/10.1016/j.clinph.2011.02.012>
27. Brown P, Rothwell JC, Thompson PD, Britton TC, Day BL, Marsden CD. New observations on the normal auditory startle reflex in man. *Brain*. 1991 Aug;114(Pt 4):1891-902. <https://doi.org/10.1093/brain/114.4.1891>
28. Kofler M, Müller J, Seppi K, Wenning GK. Exaggerated auditory startle responses in multiple system atrophy: A comparative study of parkinson and cerebellar subtypes. *Clin Neurophysiol*. 2003 Mar;114(3):541-7.
29. Rothwell JC, Vidailhet M, Thompson PD, Lees AJ, Marsden CD. The auditory startle response in progressive supranuclear palsy. *J Neural Transm Suppl*. 1994;42:43-50. https://doi.org/10.1007/978-3-7091-6641-3_4
30. Zweig RM, Whitehouse PJ, Casanova MF, Walker LC, Januarykel WR, Price DL. Loss of pedunculopontine neurons in progressive supranuclear palsy. *Ann Neurol*. 1987 Jul;22(1):18-25. <https://doi.org/10.1002/ana.410220107>
31. Walsh P, Kane N, Butler S. The clinical role of evoked potentials. *Neurol Pract*. 2005 Jun;76(Suppl 2):16-22. <https://doi.org/10.1136/jnnp.2005.068130>
32. Liu C, Zhang Y, Tang W, Wang B, Wang B, He S. Evoked potential changes in patients with Parkinson's disease. *Brain Behav*. 2017 May;7(5):1-8. <https://doi.org/10.1002/brb3.703>
33. Macerollo A, Brown MJN, Kilner JM, Chen R. Neurophysiological Changes measured using somatosensory evoked potentials. *Trends Neurosci*. 2018 May;41(5):294-310. <https://doi.org/10.1016/j.tins.2018.02.007>
34. Cheron G. Is the frontal N30 component of the somatosensory evoked potentials a reliable physiological index of the dopaminergic motor pathways? Editorial. *Clin Neurophysiol*. 1999 Oct;110(10):1698-9. [https://doi.org/10.1016/s1388-2457\(99\)00128-5](https://doi.org/10.1016/s1388-2457(99)00128-5)
35. Albanese A, Lalli S. Is this dystonia? *Mov Disord*. 2009 Sep;24(12):1725-31. <https://doi.org/10.1002/mds.22597>

36. Deuschl G, Heinen F, Kleedorfer B, Wagner M, Lücking CH, Poewe W. Clinical and polymyographic investigation of spasmodic torticollis. *J Neurol*. 1992 Jan;239(1):9-15. <https://doi.org/10.1007/bf00839204>
37. Panizza M, Lelli S, Nilsson J, Hallett M. H-reflex recovery curve and reciprocal inhibition of H-reflex in different kinds of dystonia. *Neurology*. 1990 May;40(5):824-8. <https://doi.org/10.1212/wnl.40.5.824>
38. Hallett M. Neurobiology of Disease neurophysiology of dystonia: the role of inhibition. *Neurobiol Dis*. 2011 May;42(2):177-84. <https://doi.org/10.1016/j.nbd.2010.08.025>
39. Van Gerpen JA, Matsumoto JY, Ahlskog JE, Maraganore DM, McManis PG. Utility of an EMG mapping study in treating cervical dystonia. *Muscle Nerve*. 2000 Nov;23(11):1752-6. [https://doi.org/10.1002/1097-4598\(200011\)23:11%3C1752::aid-mus12%3E3.0.co;2-u](https://doi.org/10.1002/1097-4598(200011)23:11%3C1752::aid-mus12%3E3.0.co;2-u)
40. Tisch S, Limousin P, Rothwell JC, Asselman P, Quinn N, Jahanshahi M, et al. Changes in blink reflex excitability after globus pallidus internus stimulation for dystonia. *Mov Disord*. 2006 Oct;21(10):1650-5. <https://doi.org/10.1002/mds.20899>
41. Allam N, De Oliva Fonte-Boa PM, Bezerra Tomaz CA, Brasil-Neto JP. Lack of effect of botulinum toxin on cortical excitability in patients with cranial dystonia. *Clin Neuropharmacol*. 2005 Jsn/Feb;28(1):1-5. <https://doi.org/10.1097/01.wnf.0000152044.43822.42>
42. Kofler M, Leis AA, Valls-Solé J. Cutaneous silent periods – Part 1: Update on physiological mechanisms. *Clin Neurophysiol*. 2019 Apr;130(4):588-603. <https://doi.org/10.1016/j.clinph.2019.01.002>
43. Pullman SL, Ford B, Elibol B, Uncini A, Su PC, Fahn S. Cutaneous electromyographic silent period findings in brachial dystonia. *Neurology*. 1996 Feb;46(2):503-8. <https://doi.org/10.1212/wnl.46.2.503>
44. Sabbahi M, Etnyre B, Al-Jawayed I, Jankovic J. Soleus H-reflex measures in patients with focal and generalized dystonia. *Clin Neurophysiol*. 2003 Feb;114(2):288-94. [https://doi.org/10.1016/s1388-2457\(02\)00375-9](https://doi.org/10.1016/s1388-2457(02)00375-9)
45. Koelman JHTM, Willemsse RB, Bour LJ, Hilgevoord AAJ, Speelman JD, Visser BWO De. Soleus H-Reflex Tests in Dystonia. *Mov Disord*. 1995 Jan;10(1):44-50. <https://doi.org/10.1002/mds.870100109>
46. Hallett M. Neurophysiology of dystonia: the role of inhibition. *Neurobiol Dis*. 2011 May;42(2):177-84. <https://doi.org/10.1016/j.nbd.2010.08.025>
47. Apartis E, Vercueil L. To jerk or not to jerk: A clinical pathophysiology of myoclonus. *Rev Neurol (Paris)*. 2016 Aug/Sep;172(8-9):465-76. <https://doi.org/10.1016/j.neuro.2016.07.013>
48. Apartis E. Clinical neurophysiology in movement disorders. *Handb Clin Neurol*. 2013;111(1):87-92. <https://doi.org/10.1016/B978-0-444-52891-9.00008-7>
49. Caviness JN, Brown P. Myoclonus: Current concepts and recent advances. *Lancet Neurol*. 2004 Oct;3(10):598-607. [https://doi.org/10.1016/S1474-4422\(04\)00880-4](https://doi.org/10.1016/S1474-4422(04)00880-4)
50. Zutt R, Elting JW, van Zijl JC, van der Hoeven JH, Roosendaal CM, Gelauff JM, et al. Electrophysiologic testing aids diagnosis and subtyping of myoclonus. *Neurology*. 2018 Feb 20;90(8):e647-e657. <https://doi.org/10.1212/WNL.0000000000004996>
51. Shibasaki H, Hallett M. AANEM Monograph #30 Electrophysiologic Studies of Myoclonus. Certified for CME credit 2. *Muscle Nerve*. 2005 Feb;157-74.
52. Latorre A, Rocchi L, Berardelli A, Rothwell JC, Bhatia KP, Cordivari C. Reappraisal of cortical myoclonus: A retrospective study of clinical neurophysiology. *Mov Disord*. 2018 Feb;33(2):339-41. <https://doi.org/10.1002/mds.27234>
53. Shibasaki H, Thompson PD. Milestones in Myoclonus. 2011 May;26(6):1142-8. <https://doi.org/10.1002/mds.23673>
54. Avanzini G, Shibasaki H, Rubboli G, Canafoglia L, Panzica F, Franceschetti S, et al. Neurophysiology of myoclonus and progressive myoclonus epilepsies. *Epileptic Disord*. 2016 Sep;18(S2):S11-27. <https://doi.org/10.1684/epd.2016.0835>
55. Bai O, Rathi V, Lin P, Huang D, Battapady H, Fei DY, et al. Prediction of human voluntary movement before it occurs. *Clin Neurophysiol*. 2011 Feb;122(2):364-72. <https://doi.org/10.1016/j.clinph.2010.07.010>
56. van der Salm SMA, Tijssen MAJ, Koelman JHTM, Van Rootselaar AF. The Bereitschaftspotential in jerky movement disorders. *J Neurol Neurosurg Psychiatry*. 2012;83(12):1162-7. <https://doi.org/10.1136/jnnp-2012-303081>
57. Barrett G. Jerk-locked averaging: technique and application. *J Clin Neurophysiol*. 1992 Oct;9(4):495-508.
58. Terada K, Ikeda A, Ness PC Van, Nagamine T, Kaji R, Kimura J, et al. Presence of Bereitschaftspotential preceding psychogenic myoclonus: clinical application of jerk-locked back averaging. *J Neurol Neurosurg Psychiatry*. 1995 Jun;58(6):745-7. <https://doi.org/10.1136/jnnp.58.6.745>
59. Dawson GD. The relation between the electroencephalogram and muscle action potentials in certain convulsive states. *J Neurol Neurosurg Psychiatry*. 1946 Jan;9(1):5-22. <https://doi.org/10.1136/jnnp.9.1.5>
60. Shibasaki H, Yamashita Y, Kuroiwa Y. Electroencephalographic studies of myoclonus: myoclonus-related cortical spikes and high amplitude somatosensory evoked potentials. *Brain*. 1978;101(3):447-60. <https://doi.org/10.1093/brain/101.3.447>
61. Beudel M, Elting JWW, Uyttenboogaart M, van den Broek MWC, Tijssen MAJ. Reticular myoclonus: it really comes from the brainstem! *Mov Disord Clin Pract*. 2014 Sep;1(3):258-60. <https://doi.org/10.1002/mdc3.12054>
62. Hallett M, Chadwick D, Adam J, Marsden CD. Reticular reflex myoclonus: a physiological type of human post-hypoxic myoclonus. *J Neurol Neurosurg Psychiatry*. 1977 Mar;40(3):253-64. <https://doi.org/10.1136/jnnp.40.3.253>
63. Caviness JN, Truong DD. Myoclonus. *Handb Clin Neurol*. 2011;100:399-420. <https://doi.org/10.1016/B978-0-444-52014-2.00031-8>
64. Donaldson I, Marsden CD, Scheinder S, Bhatia KP. Essential Myoclonus. In: Donaldson I, Marsden CD, Scheinder S, Bhatia KP. *Marsden's Book of Movement Disorders*. 6. ed. London; 2012. p.1079-89.
65. Roze E, Apartis E, Clot F, Dorison N, Thobois S, Guyant-Marechal L, et al. Myoclonus-dystonia: clinical and electrophysiologic pattern related to SGCE mutations. *Neurology*. 2008 Mar;70(13):1010-6. <https://doi.org/10.1212/01.wnl.0000297516.98574.c0>
66. Li JY, Cunic DI, Paradiso G, Gunraj C, Pal PK, Lang AE, et al. Electrophysiological features of myoclonus-dystonia. *Mov Disord*. 2008 Oct;23(14):2055-61. <https://doi.org/10.1002/mds.22273>
67. van der Salm SMA, Erro R, Cordivari C, Edwards MJ, Koelman JHTM, van den Ende T, et al. Propriospinal myoclonus: Clinical reappraisal and review of literature. *Neurology*. 2014;83(20):1862-70. <https://doi.org/10.1212/WNL.0000000000000982>
68. Roze E, Bounolleau P, Ducreux D, Cochen V, Leu-Semenescu S, Beaugendre Y, et al. Propriospinal myoclonus revisited. *Neurology*. 2009 Apr;72(15):1301-9. <https://doi.org/10.1212/WNL.0b013e3181a0fd50>
69. Wilkins DE, Hallett M, Erba G. Primary generalised epileptic myoclonus: A frequent manifestation of minipolymyoclonus of central origin. *J Neurol Neurosurg Psychiatry*. 1985 Jun;48(6):506-16. <https://doi.org/10.1136/jnnp.48.6.506>
70. Valls-Solé J. Facial nerve palsy and hemifacial spasm. *Handb Clin Neurol*. 2013;115:367-80. <https://doi.org/10.1016/B978-0-444-52902-2.00020-5>
71. Incirli SU, Yilmaz R, Akbostanci MC. Hemifacial spasm in sleep – A polysomnographic study. *J Clin Neurosci*. 2019 Jun;64:160-2. <https://doi.org/10.1016/j.jocn.2019.03.013>
72. Lefaucheur JP, Ben Daamer N, Sangla S, Le Guerinel C. Diagnosis of primary hemifacial spasm. *Neurochirurgie*. 2018 May;64(2):82-86. <https://doi.org/10.1016/j.neuchi.2017.12.003>

73. Valls-Solé J, Montero J. Movement disorders in patients with peripheral facial palsy. *Mov Disord.* 2003;18(12):1424-35. <https://doi.org/10.1002/mds.10605>
74. Sawlani K, Katirji B. Peripheral nerve hyperexcitability syndromes. *Continuum (Minneap Minn).* 2017 Oct;23(5, Peripheral Nerve and Motor Neuron Disorders):1437-1450. <https://doi.org/10.1212/CON.0000000000000520>
75. Gutmann L, Libell D, Gutmann L. When is myokymia neuromyotonia? *Muscle Nerve.* 2001 Feb;24(2):151-3. [https://doi.org/10.1002/1097-4598\(200102\)24:2%3C151::aid-mus10%3E3.0.co;2-7](https://doi.org/10.1002/1097-4598(200102)24:2%3C151::aid-mus10%3E3.0.co;2-7)
76. Georgesco M, Salerno A. Les activités spontanées en électromyographie. *Intérêts pratiques. Neurophysiol Clin Neurophysiol.* 2002;30(5):289-305.
77. Whaley NR, Rubin DI. Myokymic discharges in amyotrophic lateral sclerosis (ALS): A rare electrophysiologic finding? *Muscle Nerve.* 2010 Jan;41(1):107-9. <https://doi.org/10.1002/mus.21540>
78. Baizabal-Carvalho JF, Cardoso F, Jankovic J. Myorhythmia: phenomenology, etiology, and treatment. *Mov Disord.* 2015 Feb;30(2):171-9. <https://doi.org/10.1002/mds.26093>
79. Masucci E, Kurtzke J, Saini N. Myorhythmia: a Widespread Movement Disorder. *Brain.* 1984 Mar;107(Pt 1):53-79. <https://doi.org/10.1093/brain/107.1.53>
80. Tan EK, Chan LL, Lo YL. Isolated facial myorhythmia. *J Neurol Sci.* 2007 Jan;252(1):36-8. <https://doi.org/10.1016/j.jns.2006.10.009>
81. Raina GB, Cersosimo MG, Folgar SS, Giugni JC, Calandra C, Paviolo JP, et al. Holmes tremor Clinical description, lesion localization, and treatment in a series of 29 cases. *Neurology.* 2016 Mar;86(10):931-8. <https://doi.org/10.1212/WNL.0000000000002440>
82. Dressler D, Thompson PD, Gledhill RF, Marsden CD. The syndrome of painful legs and moving toes. *Mov Disord.* 1994 Jan;9(1):13-21. <https://doi.org/10.1002/mds.870090104>
83. Alvarez M V, Driver-dunckley EE, Caviness JN, Adler CH, Evidente VGH. Case series of painful legs and moving toes: clinical and electrophysiologic observations. *Mov Disord.* 2008 Oct;23(14):2062-6. <https://doi.org/10.1002/mds.22272>
84. Mitsumoto H, Levin K, Wilbourne A, Chou S. Hypertrophic mononeuritis clinically presenting with painful legs and moving toes. *Muscle Nerve.* 1990 Mar;13(3):215-21. <https://doi.org/10.1002/mus.880130308>