

Primary Cholesteatoma of the Bilateral External Acoustic Meatus

Colesteatoma Primário de Meato Acústico Externo Bilateral

*Luciana Almeida Moreira**, *Raquel Chartuni Pereira Teixeira**, *Carlos Eduardo Guimarães de Salles***,
*Cláudia Inês Guerra de Sousa Silva***, *Daniel Mochida Okada****.

* Resident Physician of Otorhinolaryngology and Head and Neck Surgery at HSPE-SP (R3).

** Otorhinolaryngologist.

*** Otorhinolaryngologist. Assistant Doctor of Otology at HSPE-SP

Institution: Hospital do Servidor Público Estadual de São Paulo.
São Paulo / SP - Brazil

Mail address: Luciana Almeida Moreira - Rua Borges Lagoa, 933 - Apto. 73 - Vila Clementino - São Paulo / SP - Brazil - Zip code: 04038-032 - Telephone: (+55 11) 8684-5502 - E-mail: lu21moreira@hotmail.com

Article received on February 5, 2009. Approved on May 10, 2009.

SUMMARY

Introduction:

The cholesteatoma of the external acoustic meatus is an uncommon pathology. Most series in the literature describe secondary cases, with a few reports of primary cholesteatoma. It is characterized by the erosion of the external acoustic meatus bone portion by proliferation of the adjacent squamous tissue.

Objective:

To report an uncommon case of primary cholesteatoma of the bilateral external acoustic meatus.

Case Report:

Female patients aged 20 years old with ear ache for 3 years, associated to hypacusis and otorrhea to the left. Without a previous history of otologic pathologies. Upon otoscopy, there could be noticed bilateral erosion from the external acoustic meatus with a large amount of epidermal debris. The computed tomography confirmed cholesteatoma of the bilateral external acoustic meatus and the patient was submitted to modified radical tympanomastoidectomy to the right.

Final Comments:

The primary cholesteatoma of the external acoustic meatus is an uncommon pathology that is part of the differential diagnosis of chronic otalgia and otorrhea. The evaluation of its extension must be done with computed tomography and surgery is the choice treatment.

Keywords:

cholesteatoma, bilateral external meatus, primary, bilateral.

RESUMO

Introdução:

O colesteatoma de meato acústico externo é uma patologia rara. A maioria das séries na literatura descreve casos secundários, com poucos relatos de colesteatoma primário. Caracteriza-se pela erosão da porção óssea do meato acústico externo por proliferação de tecido escamoso adjacente.

Objetivo:

Relatar um caso raro de colesteatoma primário de meato acústico externo bilateral.

Relato do Caso:

Paciente de 20 anos, sexo feminino, com otalgia há 3 anos, associada à hipoacusia e otorreia à esquerda. Sem história prévia de patologias otológicas. À otoscopia, observava-se erosão bilateral do meato acústico externo com grande quantidade de debris epidérmicos. A tomografia computadorizada evidenciou colesteatoma de meato acústico externo bilateral, sendo a paciente submetida à timpanomastoidectomia radical modificada à direita.

Comentários Finais:

O colesteatoma primário de meato acústico externo é uma patologia rara, fazendo parte do diagnóstico diferencial de otalgia e otorreia crônicas. A avaliação da sua extensão deve ser feita com tomografia computadorizada e o tratamento de eleição é a cirurgia.

Palavras-chave:

colesteatoma, meato acústico externo, primário, bilateral.

INTRODUCTION

The external auditory canal cholesteatoma (EACC) is an uncommon disease that affects 1 per 1000 patients with otologic complaints (1). It is characterized by the erosion of the external auditory canal (EAC) bone portion by proliferation of the adjacent squamous tissue (2). It may be classified into primary or secondary trauma, surgery, inflammatory process or obstruction of the EAC (5, 6). There are several series in the literature describing secondary EACC, but a few reports of primary EACC (2, 3). In a recent article, PERSAUD et al. reported the first case of bilateral primary EACC in a black young man (4). We reported an uncommon case of bilateral primary EACC in a patient aged 20 years old.

CASE REPORT

L.C.B.S., student, female sex, 20 years old, from São Paulo, reported bilateral monotone otalgia for 3 years, associated to hypacusis and otorrhea at the left side (Figure 1). She reported periods of worsening of the earache, especially associated to water entry at the EAC. There was no prior record of other affections, trauma or otologic surgeries. Upon otoscopy, she had erosion from both EAC with a large number of epidermal debris that prevented the viewing of the tympanic membrane (Figure 2). The tonal audiometry (TA) confirmed a light bilateral conductive loss. Temporal bones computed tomography (CT) confirmed bilateral EACC with a stronger bone erosion of the EAC right posterior wall (Figures 3 and 4). Radical tympanomastoidectomy was performed and modified at the right side with production of microbox and interposition of the mastoid cortical bone between the clamp head and the temporal fascia. Upon surgery, we noticed erosion of the EAC posterior wall with a large amount of descamative material. There was a good postoperative evolution with reduction of the gap at the right side of the AT that had no signals of the lesion recurrence. The patient still expects contralateral intervention.

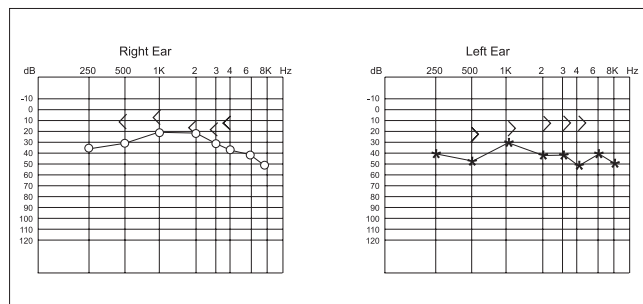


Figure 1. Preoperative tonal audiometry. - Observed by bilateral conductive loss, stronger at the left side.

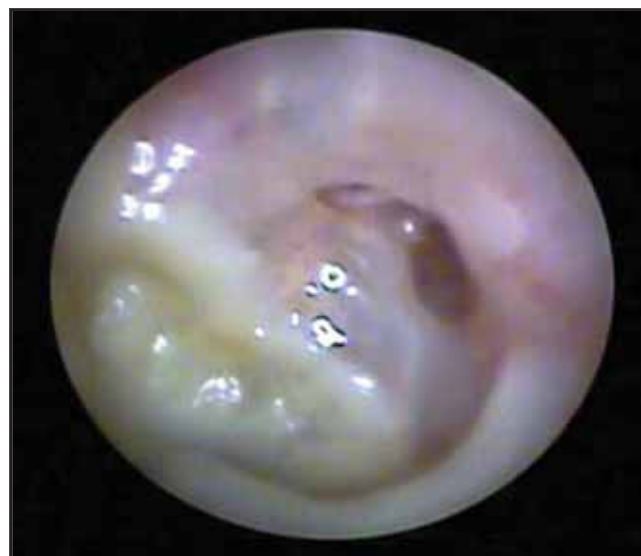

Figure 2. Otoscopy at the left side. - Presence of epidermal debris in the external acoustic canal, with erosion of the posterior wall.

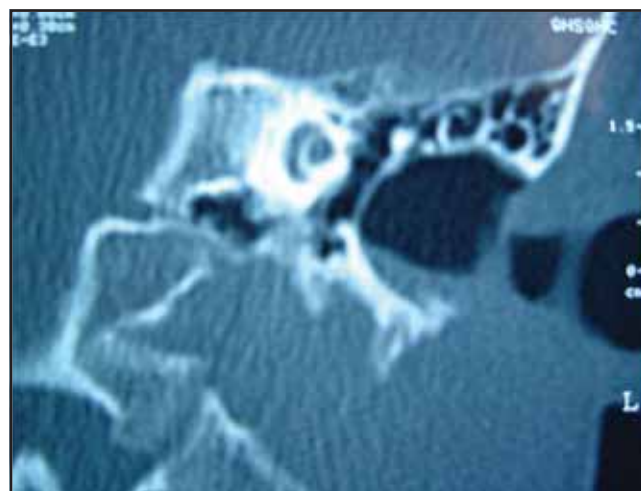


Figure 3. Computed tomography of temporal bones in coronal cut - left side - Enlarging of the auditory conduct and presence of material with density of soft parts.

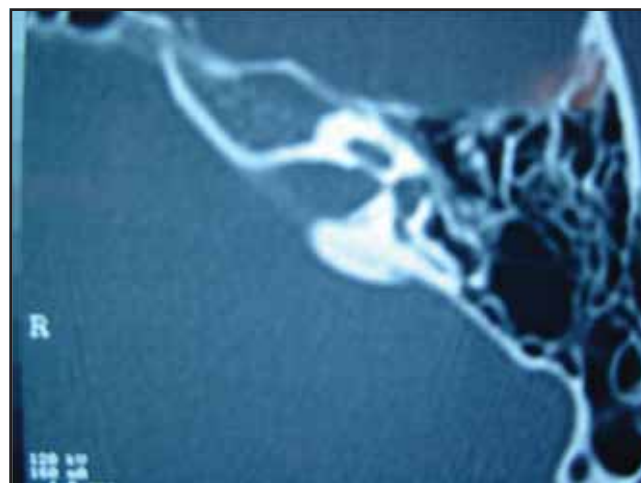


Figure 4. Computed tomography of temporal bones in axial cut - left side - Well pneumatized and airy mastoid, confirming the pathology is not originated from the middle ear.

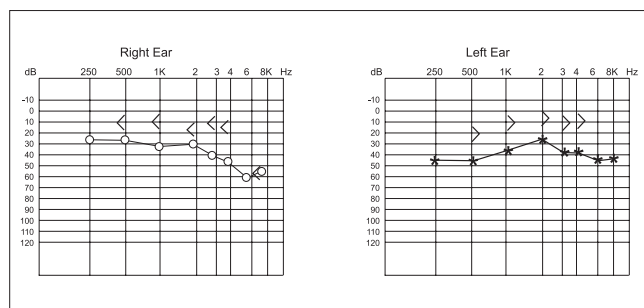


Figure 5. Postoperative tonal audiometry. - Observed a maintenance of the aerial-osseous gap.

DISCUSSION

The first description of the EACC was made by TOYNBEE in 1850, but the precise definition of this disease was obtained by PIEPERGERDES et al., in 1980, when the differentiation between EACC and keratosis obturans was made (2). The KO is defined as the accumulation of keratin produced by exfoliation of the EAC skin. In the other hand, the EACC is characterized by the erosion of the bone portion of the EAC from the adjacent squamous tissue (2). The differential diagnosis must also include neoplasms, Panner disease and malignant external otitis (1). The clinical profile is generally characterized by light and constant otalgia, sporadic otorrhea and pruritus in the EAC. The occurrence of hypacusis is due to the obstruction of the EAC by the keratin debris. Alterations of the tympanic membrane are not part of the profile (1).

The EACC etiology remains obscure, and there is the attempt to classify it as primary or secondary to surgery, trauma, inflammatory process, congenital stenosis or obstruction of the EAC (5, 6).

As regards to the primary or spontaneous EACC, there are several theories that seek to explain its etiology. One of these states that such affection could appear from a small trauma onto the EAC that would lead to periostitis and further infiltration/erosion by the adjacent squamous tissue (3). The other one reports alterations to the epithelial migration of the EAC's skin and to the cerumen produced by it would lead to the appearing of the EACC (6).

The treatment of EACC is based on the type of lesion and intensity of the symptoms. Patients with light symptoms, small and circumscribed lesions, with a high surgical risk or that refuse the surgery may be clinically treated with frequent aspirations under microscopy and otologic drops when required. The surgical treatment is prescribed in the other cases to prevent progression of the erosion and complications. The surgical procedure is determined by the extension of the osteonecrosis, erosion and assumption by the surgeon (3).

FINAL COMMENTS

The EACC is an uncommon affection that is part of the differential diagnosis of chronic otalgia and otorrhea. The treatment is especially surgical and the follow up is clinical and exceptional. The evaluation of the lesion and surgical planning must be done after performance of CT of temporal bones. The most common surgery is modified radical mastoidectomy.

BIBLIOGRAPHICAL REFERENCES

1. Anthony PF, Anthony WP. Surgical treatment of external auditory canal cholesteatoma. *Laryngoscope*, 1982, 92(1):70-5.
2. Piepergerdes MC, Kramer BM, Behnke EE. Keratosis obturans and external auditory canal cholesteatoma. *Laryngoscope*. 1980, 90(3):383-391.
3. Vrabec JT, Chaljub G. External canal cholesteatoma. *Am J Otolaryngol*. 2000, 21(5):608-14.
4. Persaud R, Singh A, Georgalas C, Kirsch C, Wareing M. A new case of synchronous primary external ear canal cholesteatoma. *Otolaryngol Head Neck Surg*. 2006, 134(6):1055-6.
5. Naim R, Linthicum Jr. F, Shen T, Bran G, Hormann K. Classification of the external auditory canal cholesteatoma. *Laryngoscope*. 2005, 115(3):455-60.
6. Holt JJ. Ear canal cholesteatoma. *Laryngoscope*. 1992, 102(6):608-13.