

Nasal tip narrowing: Minimally invasive suture technique for thick nose tip

Refinamento da ponta nasal: Técnica de sutura minimamente invasiva para a ponta nasal larga

Antonio Celso Nunes Nassif Filho¹, Giovana Romano², Denise Braga Ribas³, Scheila Maria Gambeta Sass⁴, Emerson Francesch⁵.

1) Doctor in Medicine from UFPR. Professor at PUC/PR, Coordinator of the Medical Residency in Otorhinolaryngology at Paraná's Red Cross Hospital.

2) Specialist in Surgical Plastic - AMB / CFM / SBCP. Plastic Surgeon Doctor.

3) Doctor attending Specialization Degree in Otorhinolaryngology at Paraná's Red Cross Hospital. Junior Doctor.

4) Specialist in Otorhinolaryngology and Facial Cervical Surgery. Otorhinolaryngologist Doctor.

5) Doctor

Institution: Paraná's Red Cross Hospital.
Curitiba / PR - Brazil.

Mailing address: Denise Braga Ribas - Rua Antenor Guimarães, 175 - Casa - Bairro: Pilarzinho - Curitiba / PR - Brazil - Zip code: 82110-010 - Telephone: (+55 41) 9951-0816 / 3338-1423 - Email: deni.ribas@yahoo.com.br

Article received on January 27, 2011. Article approved on April 19, 2011.

SUMMARY

Introduction: Suture techniques are mandatory methods to shape the nasal cartilages. For purposes of achieving a better contour on thick or globose nasal tips, the authors have approached a controlled intercrural and minimally invasive suture technique and the results obtained by submitting 34 patients to rhinoplasty.

Objective: Illustrate the intercrural suture technique as a treatment for a thick or globose nasal tip under closed rhinoplasty and explain the esthetical results.

Method: Retrospective study with 34 patients' clinical documents and photographs (5 male and 20 female) aged between 16 and 52, who were submitted to the thick or globose nasal tip rhinoplasty as an anatomic element found in the physical examination. In all the cases, closed rhinoplasty technique was used. A suture that cannot be absorbed is performed throughout the intermediate process. The study was performed at the Brazilian Red Cross Hospital in the State of Paraná and Sugisawa Hospital in 2009 and 2010. Patients were operated on by the main author and the junior doctors under training.

Results: The controlled intercrural suture enabled the nasal tip to be narrowed and improved the shape in the frontal and lateral angles of the nasal tip.

Conclusion: Controlled intercrural suture is a minimally invasive method providing the thick nasal tip narrowing with satisfactory results.

Keywords: rhinoplasty, nasal cartilage, suture techniques, minimally invasive surgical procedures.

RESUMO

Introdução: Técnicas de sutura são métodos indispensáveis para esculpir as cartilagens nasais. Para obter um melhor contorno em pontas nasais largas ou globosas os autores apresentam uma técnica de sutura intercrural controlada e minimamente invasiva e os resultados obtidos em 34 pacientes submetidos a rinoplastia.

Objetivo: Demonstrar a técnica de sutura intercrural como tratamento para a ponta nasal larga ou globosa em rinoplastia fechada e apresentar os resultados estéticos.

Método: Estudo retrospectivo de documentos clínicos e fotografias de 34 pacientes (5 homens e 29 mulheres), com idade entre 16 e 52 anos, submetidos a rinoplastia com ponta nasal larga ou globosa como elemento anatômico presente no exame físico. Em todos os casos foi utilizada técnica de rinoplastia fechada. Uma sutura inabsorvível é realizada ao longo do processo intermediário. O estudo foi conduzido em 2009 e 2010 no Hospital da Cruz Vermelha Brasileira - Filial do Paraná - Brasil e no Hospital Sugisawa. Os pacientes foram operados pelo autor principal e pelos médicos residentes em treinamento.

Resultados: A sutura intercrural controlada proporcionou um refinamento da ponta nasal e uma melhor forma nos ângulos frontal e lateral da ponta nasal.

Conclusão: A sutura intercrural controlada é um método minimamente invasivo que oferece resultados satisfatórios em refinamento da ponta nasal larga

Palavras-chave: rinoplastia, cartilagens nasais, técnicas de sutura, procedimentos cirúrgicos minimamente invasivos.

INTRODUCTION

The techniques of nasal tip narrowing represent an attractive subject in rhinoplasty surgery. Patient's satisfaction with the result is mainly achieved by the quality of the post-surgical aspect of the nasal tip. The first techniques were based on removing cartilages, breaking and releasing or also undermine the internal nasal architecture. Methods breaking the support mechanisms of the nasal tip complex (1, 2, 3).

After decades of studies, the concepts of rhinoplasty has changed (1,3,4). The radical cartilage resections and the rupture of the support mechanisms have been replaced (5). Techniques intended to preserve and reorient the nasal tip cartilage are used, while maintaining or restoring the intrinsic support mechanisms (1, 6, 7, 8).

From 1935 to 1980, the nasal tip surgery consisted of excising, incising or dividing alar cartilages (4,9). The first results were usually amazing, but hematoma, boron narrowing and collapse of external valve used to gradually occur, especially under a thin skin (10). The alar cartilage division was the fatal failure of the technique, because it takes to a loss of support and subsequently results in breaking the soft tissue, retraction of the alar rimas and tip clamping. These noses, with their "operated appearance" take the nasal surgery to the era of grafts (11, 12).

Anyway, along with the inherent changeability of structural grafts for a contour, there is always a risk for extrusion, distortions and externally apparent abnormalities. To relive such graft disadvantages, the sutures to modify the alar cartilage were adopted in the late 1980's (13). McCOLLOUGH and ENGLISH and TARDY and CHEN, by using an endonasal approach, introduced the concept of tip approximation with only one suture through 2 intermediate and lateral crurals (6, 8).

The objective of this study is to describe a technique of controlled intercrural suture in a closed rhinoplasty and evaluate the esthetic result of the narrowing of wide or globous nasal tips.

METHOD

We evaluated the photos and records of 34 patients (5 male and 29 female aged between 16 and 52, showing a wide or globous nasal tip and submitted to a closed rhinoplasty, in which the technique of controlled intercrural suture was used. The surgeries were performed between January 2009 and November 2010 at the Brazilian Red

Cross Hospital in Paraná and at Sugisawa Hospital. The work was not evaluated by the Ethical Committee of these hospitals.

All the patients submitted to a classic Converse-Diamond rhinoplasty (basic technique), under a general anesthesia and local infiltration (xylocaine 2% with epinephrine 1:100,000). All the patients signed a term of free and clarified agreement.

Description of the basic rhinoplasty technique (closed technique)

1. Bilateral intercartilaginous incision and release of structures of soft tissues in the nasal dorsum with a septocolumellar transfixation.
2. Separation of the junction of the upper lateral cartilage of the nasal septum with a bistoury lamina number 15.
3. Lowering of cartilage quadrangular.
4. Detachment of the periosteum of the nasal dorsum.
5. Reduction of bone gibbus by using a straight osteotome (cutting type Maury-Parkes).
6. Septoplasty (when necessary).
7. Lateral osteotomies performed with 4mm-curved converse-type osteotome. Medial fracture with a straight osteotome.
8. Controlled intercrural suture performed to sharpen the nasal tip (technique described below).
9. Septocolumellar suture and mucosa suture.

Description of the technique of controlled intercrural suture.

1. Infiltration of the nasal mucosa and release of the epithelium covering the lower lateral cartilage bilaterally with Converse scissors, in order to leave the lower lateral cartilage completely free of the epithelium (Figure 1).
2. Alar cartilage transfixed with Mononylon 5-0 threads on its cranial border in the caudal direction. The location of the transfixed cartilage can be marked with digital compression on it or with a Compass, so that the points can be symmetrical (Figure 2).

There is the possibility of marking of the alar cartilage points to be transfixed with a needle-aided external maneuver (insulin) and a simulation of the suture effect over the narrowing and the upper rotation of the domes.

3. Pass the needle through the septum-columellar incision to the opposite side (Figure 3).
4. Transfix the alar cartilage in the reverse direction to that of the first transfixation (Figure 4).

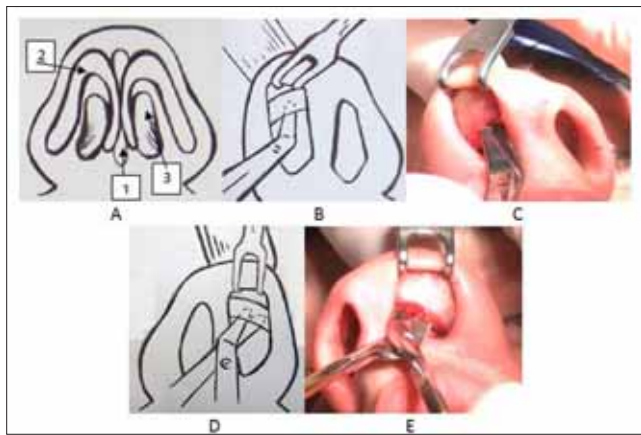


Figure 1. - A: 1 nasal septum, 2 lateral crura, 3 nasal opening. B, C: Abruptio between the epithelium and the right lower lateral cartilage with Converse scissors. D, E: Abruptio between the cartilage and the left lateral skin with Converse scissors.

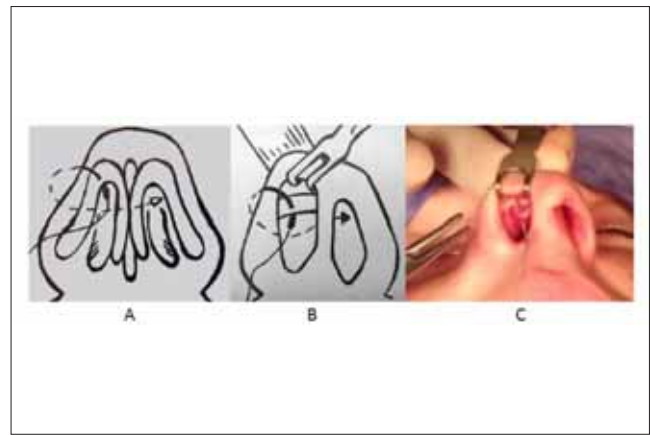


Figure 2. - A, B and C: Placement of plaster in the right lateral crura with mononylon 5.0 wire (note that the plaster is in the caudal direction).

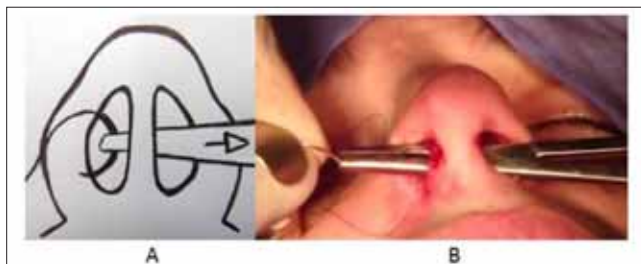


Figure 3. A and B: Pass the mononylon thread with a needle-holder from the right nostril to the left one between septum and nasal columella.

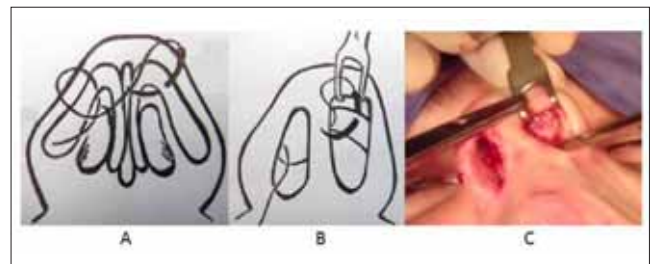


Figure 4. A, B and C: Placement of plaster in the left lateral crura with a mononylon 5.0 thread in the opposite direction to the point on the other side (cranial).

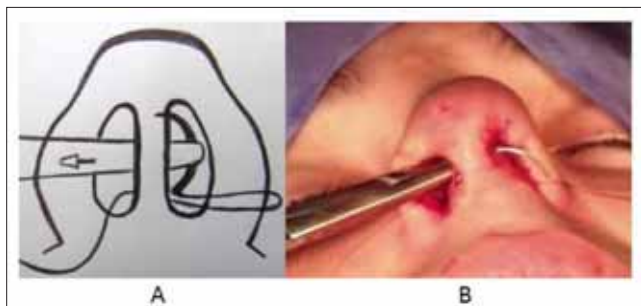


Figure 5. Pass the mononylon thread with a needle-holder from the right nostril to the left one between septum and nasal columella.

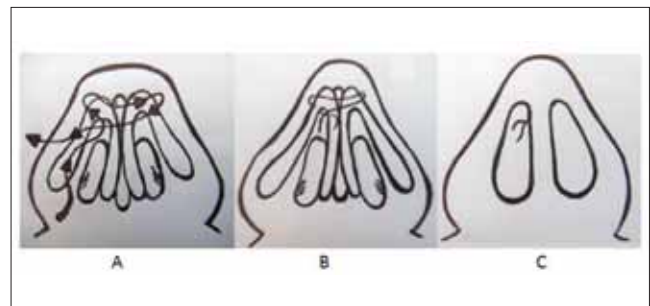


Figure 6. Placement of intercrural plaster.

5. Pass the needle through the septum-columellar incision to the side of the initial suture (Figure 5).
6. Controlled finishing of the node by making an approach of the domes according to desired refinement of tip (Figure 6).

The controlled tension of suture must be performed according to the aesthetic aspect externally observed by

the surgeon. If necessary, two or three more nodes are made to fix the ideal tension.

RESULTS

The controlled intercrural suture was performed in 34 patients submitted to closed rhinoplasty. In 100% of the

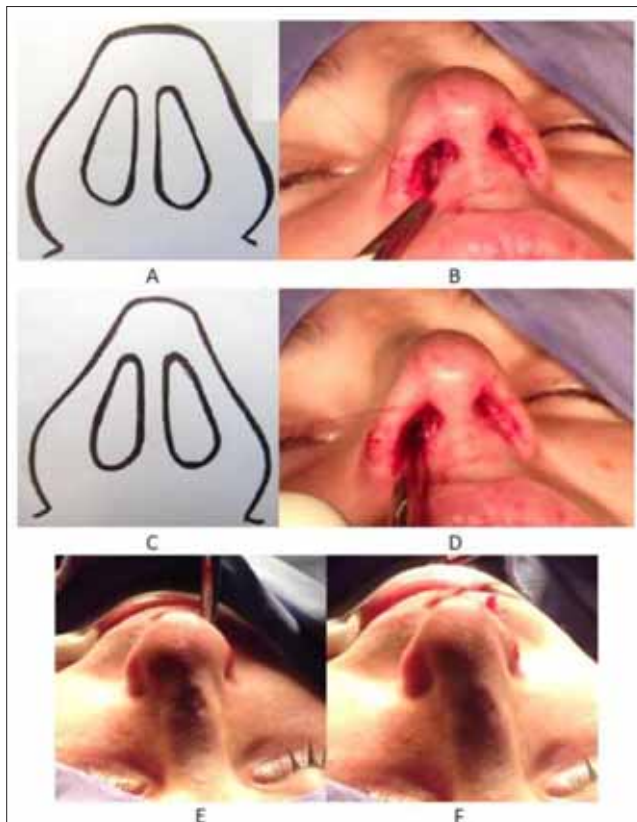


Figure 7. - A and B: Overview of the nasal base before placing the intercrural plaster (intraoperative). C and d: Overview of the nasal base after placing the intercrural plaster (intraoperative). E: Superior overview of the nasal base before placing the intercrural plaster (intraoperative). F: Overview of the nasal base after placing the intercrural plaster (intraoperative).

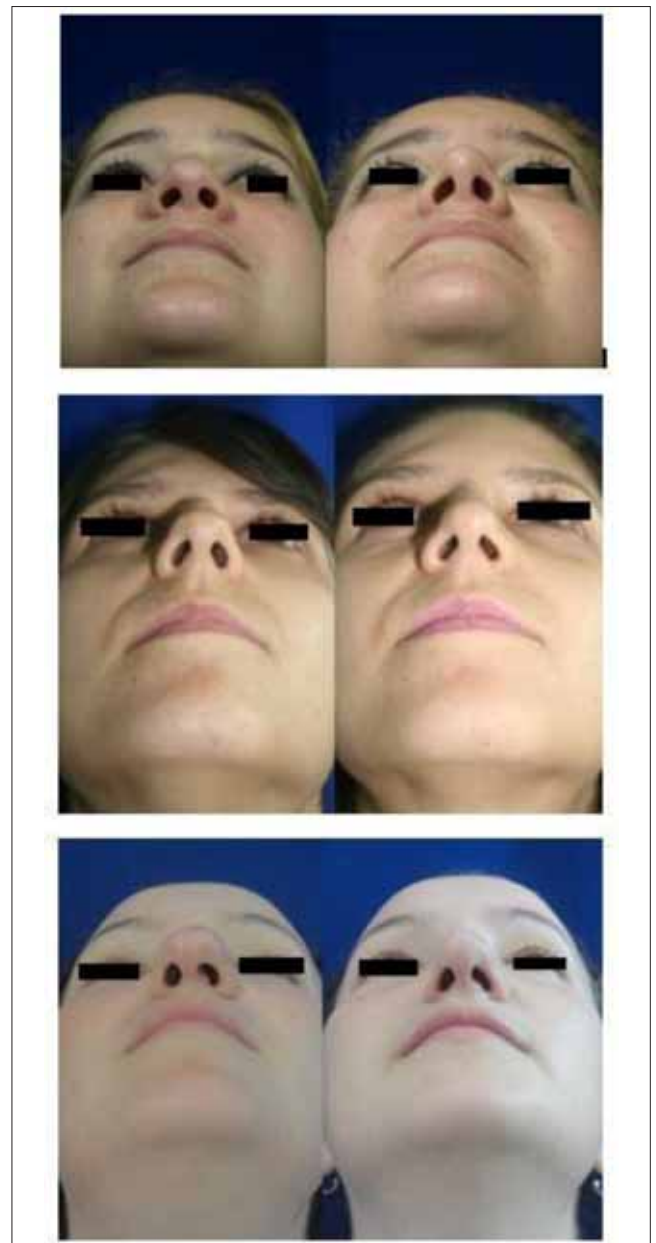

Figure 8. Results achieved by using the described technique.

cases, the nasal tip was narrowed and sharpened as well as the previous aspect improved. The result was satisfactory for both patient and surgeon. Figures 7 and 8 proved the result of the technique described in the pre-surgical and post-surgical periods.

Some patients complained about a little discomfort on the nasal tip because of the plaster with an unabsorbable thread. The plaster was removed some months after surgery without changing the result because of the local cicatricial fibrosis.

DISCUSSION

Minimally invasive procedures and with reduced scars are a world trend in the aesthetic surgery (2,3,11). The technical possibility to rectify the wide or globous nasal tip without needing an open rhinoplasty is an advantage of a smaller manipulation of nasal tip cartilages (2,4), in addition to a lower risk of lesions, complications, asymmetries and absence of external scar and shorter surgical time (14).

The control of the nasal tip contour and a natural appearance of the nasal tip are the secret for a successful rhinoplasty (1,15). The intercrural suture technique enables a bigger or smaller narrowing of the by way of a bigger or smaller tension when placing the plaster between the lateral cruras.

The intercrural suture technique was firstly described in 1980 by McCOLLOUGH, ENGLISH, TARDY AND CHEN as an effective and minimally invasive technique (6). This is what we showed in this article, the intercrural suture can be performed under a closed rhinoplasty with a minimally invasive access.

For being a controlled and reversible nasal refinement technique, intercrural suture is a first-choice procedure in nasal tip surgery (6). Despite not having demonstrated any complication in our cases presented in the article, if there was any, this technique enables us to totally reverse the nasal tip to original, what does not occur when more invasive techniques are chosen as a first option of surgical treatment of nasal tip.

The convexity of the alar cartilage is one of the most common deformities and it requires attention during a rhinoplasty (6). The use of suture intercrural allows create concave contour to be created in this structure.

Out of the various existing techniques for thinning nasal tip, intercrural suture is the most indicated when it chooses closed Rhinoplasty and program a subtle refinement of the nasal tip (16).

The final result of nasal refinement is influenced by factors such as type of cartilage and degree of enlargement of the nasal tip, degree of intrinsic strength of the lower lateral cartilage and tensile strength of suture, thus promoting a higher or lower dome approximation (8,17).

The thickness of the skin is a determining factor when improving the nasal tip contour (12,14). In patients with Caucasian nose, the result is more significant because their skin and lower lateral cartilage are thinner (17,18). In patients with a thicker skin, excessive subcutaneous tissue and a thicker lower lateral cartilage, the effect of the suture can be more discrete (6).

According to the authors, in the intercrural controlled suture technique, some details noted in our article must be observed (9, 15,16):

1. The symmetrical local mark in the cartilage to be transfixated and approached by an external maneuver and a narrowing simulation.
2. The direction to perform suture so that a superior rotation of the lateral crura and the nasal tip narrowing can occur.

3. Suture must be performed with non-absorbable thread.
4. The result is less expressive in patients with a thick skin, thick lower lateral cartilage and excessive subcutaneous cellular tissue above the lower lateral cartilage.

CONCLUSION

The controlled intercrural suture via a closed rhinoplasty is an effective method to better sharpen the nasal tip and globous or wide tips. It is an easy-to-apply technique, as shown and illustrated by the method of the article, reducing the surgical time. The technique avoids an excessive manipulation of the cartilaginous tissues and an external nasal scar.

This technique represents a possibility for visualization and dynamic surgical control of the nasal tip, increasing the arsenal of surgical tactics to narrow the contour of the nasal tip.

The results found in the 34 patients submitted to this surgical technique was satisfactory from both patients and surgeon's standpoints; the good technical quality can be proved by the documents used in the results.

REFERENCES

1. Behmand RA, Ghavami A, Guyuron B. Nasal tip sutures, part I: the evolution. *Plast Reconstr Surg.* 2003, 112(4):1125-29.
2. Tebbetts JB. Shaping and positioning the nasal tip without structural disruption: a new, systematic approach. *Plast Reconstr Surg.* 1994, 94(1):61-77.
3. Fuleihan NS. The Transvestibular Approach: A new horizon in Rhinoplasty. *Arch Facial Plast Surg.* 2006, 8(4):273-82.
4. Peck GC. *Techniques in aesthetic rhinoplasty*, 2nd ed. New York: Thieme-Stratton, 1990.
5. McCollough EG, English JL. A new twist in nasal tip surgery: an alternative to the Goldman tip for the wide or bulbous lobule. *Arch Otolaryngol.* 1985, 111(8):524-9.
6. Baker SR. Suture contouring of the nasal tip. *Arch Facial Plast Surg.* 2000, 2(1):34-42.
7. Leach JL, Athré RS. Four suture tip rhinoplasty: a powerful tool for controlling tip dynamics. *Otolaryngol Head Neck Surg.* 2006, 135(2):227-31.

8. Tardy ME, Cheng E. Transdomal suture refinement of the nasal tip. *Facial Plast Surg.* 1987, 4(4):317-26.
9. Papel ID. Interlocked transdomal suture technique for the wide interdomal space in rhinoplasty. *Arch Facial Plast Surg.* 2005, 7(6):414-17.
10. Kridel RW, Konior FJ, Shumrick KA, Wright WK. Advances in nasal tip surgery: the lateral crural steal. *Arch Otolaryngol Head Neck Surg.* 1989, 115(10):1206-12.
11. Daniel RK. Tip Refinements Grafts: The designer Tip. *Aesthet Surg J.* 2009, 29(6):528-37.
12. Mocellin M, Pasinato R, Berger CAS, Soares CMC, Grinfeld A, Fagundes MSC. Estreitamento da Base Nasal no Nariz Caucasiano através da técnica de Cerclagem. *Arch Otolaryngol.* 2010, 4(3):199-205.
13. Daniel RK. Rhinoplasty: creating an aesthetic tip: a preliminary report. *Plast Reconstr Surg.* 1987, 80(6):775-83.
14. Converse JM. Corrective rhinoplasty. In: Converse JM. *Reconstructive Plastic Surgery.* Philadelphia, Pa WB Saunders Co. 1977, 2:1091-3.
15. Toriumi DM. New Concepts in Nasal Tip Contouring. *Arch Facial Plast Surg.* 2006, 8(3):156-185.
16. Gruber RP, Friedman GD. Suture algorithm for the broad or bulbous nasal tip. *Plast Reconstr Surg.* 2002, 110(7):1752-64.
17. Corrado A, Bloom JD, Becker DG. Domal Stabilization Suture in Tip Rhinoplasty. *Arch Facial Plast Surg.* 2010, 11(3):194-7.
18. Mocella S, Bianchi N. Double interdomal suture in nasal tip sculpturing. *Facial Plast Surg.* 1997, 13(3):179-96.