

## Review Article

# Trophic ulcers-Practical management guidelines

Vinita Puri, Venkateshwaran N<sup>1</sup>, Nishant Khare<sup>2</sup>

Professor and Head, Department of Plastic Surgery, KEM Hospital, Mumbai, <sup>1</sup>Ex. Senior resident, KEM Hospital and Consultant Plastic Surgeon, Jupiter Hospital, Thane, <sup>2</sup>Assistant Professor, Department of Plastic Surgery, KEM Hospital, Mumbai

**Address for correspondence:** Dr. Vinita Puri, Prof. and Head of the Department of Plastic Surgery, KEM hospital, Parel, Mumbai, India. E-mail: profpuri@gmail.com

### ABSTRACT

The management of patients with trophic ulcers and their consequences is difficult not only because it is a recurrent and recalcitrant problem but also because the pathogenesis of the ulcer maybe different in each case. Methodically and systematically evaluating and ruling out concomitant pathologies helps to address each patient's specific needs and hence bring down devastating complications like amputation. With incidence of diabetes being high in our country, and leprosy being endemic too the consequences of neuropathy and angiopathy are faced by most wound care specialists. This article presents a review of current English literature available on this subject. The search words were entered in PubMed central and appropriate abstracts reviewed. Relevant full text articles were retrieved and perused. Cross references from these articles were also reviewed. Based on these articles and the authors' experiences algorithms for management have been presented to facilitate easier understanding. It is hoped that the information presented in this article will help in management of this recalcitrant problem.

### KEY WORDS

Diabetic ulcer; off-loading pressure; plaster boot; trophic ulcer

### INTRODUCTION

The word 'Trophic' is derived from the Greek word Trophe = nutrition. The American Heritage Medical Dictionary 2007 defines trophic ulcers as 'an ulcer due to impaired nutrition of the part'. Mosby's Medical Dictionary 2009 defines trophic ulcer as 'a pressure ulcer caused by external trauma to a part of the body that is in poor condition because of disease, vascular insufficiency

or loss of afferent nerve fibres'.

Trophic ulcers can be classified as tabulated in Table 1.

Though the broad management of all trophic ulcers would be similar, one would have to tweak the management on a case-to-case basis depending on the aetiology of the lesion and its pathophysiology.

**Table 1: Classification of trophic ulcers**

Neurogenic	e.g. Hansens disease, syringomyelia, pressure ulcers in paraplegics, spina bifida, diabetic neuropathy, alcoholic polyneuropathy, etc.
Vascular (arterial)	Poor arterial supply, e.g. peripheral vascular disease, arteriosclerosis, microangiopathy as in diabetes
Vascular (venous)	Venous disease – venous stasis ulcers
Systemic causes or malnutrition	e.g. vitamin B 12 deficiency, severe avitaminosis, ulcers over deposits of gout

#### Access this article online

Quick Response Code:



Website:

www.ijps.org

DOI:

10.4103/0970-0358.101317

Due to the pathogenesis of each ulcer being different an understanding of the pathology would help us in managing the problem better.<sup>[1]</sup> For example diabetic ulcers have a multifactorial pathogenesis with neurogenic, ischaemic and nutritional factors all contributing to its formation and chronicity.

This article presents a review of current English literature available on this subject. The search words were entered in PubMed central and appropriate abstracts reviewed. Relevant full text articles were retrieved and perused. Cross references from these articles were also reviewed. Based on these articles and the authors own experiences algorithms for management have been presented to facilitate easier understanding. It is hoped that the information presented in this article will help in management of this recalcitrant problem.

## DIABETIC ULCERS

### Pathogenesis

The pathogenesis of diabetic ulcers is multifactorial and they will fit under all headings of the classification of trophic ulcers.

### Nerve damage/neuropathy

Nerve damage in diabetic mellitus is all encompassing involving the motor, sensory and the autonomic pathways. Five clinical types of diabetic neuropathies have been described-large fibre neuropathy, small fibre neuropathy, proximal motor neuropathies, acute mononeuropathies and pressure palsies.<sup>[2]</sup> All these, either in isolation or collectively, contribute to the formation of the ulcer. Because of motor nerve involvement, the patient has an abnormal gait, leading to unwieldy, unusual pressure on the foot, resulting in trauma proceeding to ulceration. Sensory neuropathy causes an insensate foot or hand with loss of protective pain, pressure, and temperature and repeated injury leads to ulceration. Neuropathy of the sympathetic autonomic system leads to vasodilatation as well as loss of or decreased sweating leading to warm, dry hands and feet. These are prone to cracks and fissures which get infected proceeding to form ulcers. Diabetic neuropathy also impairs the nerve axon reflex that depends on healthy C-receptor function and causes local vasodilatation in response to a painful stimulus. This further compromises the vasodilator response normally present during injury or inflammation.<sup>[3]</sup> Many of these can be circumvented by preventive patient education measures.

### Ischaemic damage

Ischaemia impairs wound healing by preventing or decreasing the flow of O<sub>2</sub>, and all the components required for healing. Problems of ischaemia are of two types in diabetics.

- Decreased angiogenesis in the small vessels of diabetic foot (presently no therapeutic options are available and this is one area in which further research is required).<sup>[4]</sup>
- Microangiopathy may be due to both structural and functional abnormalities in the vessels. Structural abnormalities are seen most commonly in the retinal and renal vasculature leading to blindness and renal failure. But some with severe microcirculatory problems of the foot have normal capillaries on skin or skeletal muscle biopsy. Levin and O'Neal's bible on Diabetic foot mentions that sluggish microcirculation resulting in microvenular dilatation is considered 'functional' in that it may be reversed with improved control of diabetes. Periungual telangiectasia, red skin and rubeosis faciei, erysipelas-like erythema may also be markers of structural microangiopathy.<sup>[2]</sup>

### Peripheral arterial disease

Peripheral arterial disease (PAD) can occur concomitantly with diabetes. Atherosclerotic plaques can occur in the femoral, popliteal and posterior tibial arteries (most often involves medium sized arteries at the trifurcation in diabetics) leading to occlusion of these vessels or decreased flow. These diabetic patients are more prone to ulceration than those without PAD. In cases of severe ischaemia this problem may be circumvented by arterial bypass revascularization procedures (as distal vessels are usually spared) if one has to salvage the foot and avoid an amputation. In diabetics who are not able to undergo revascularization surgeries, endovascular angioplasties are a viable option. Endovascular interventions for both, claudication and critical limb ischaemia, have been shown to have high 6- to 12-month patency rates with limited morbidity.<sup>[5-8]</sup> A multicentric study of diabetic foot patients undergoing peripheral angioplasty showed good improvement in the ankle brachial index from 0.53 to 0.9 ( $P < 0.0001$ ) and also an end to ischaemic pain following the procedure.<sup>[9]</sup>

### Associated systemic factors

- (a) High glucose levels in tissues leads to infection and hence spread of tissue damage.
- (b) Physiological derangements due to diabetes severely hamper the closure of ulcers.<sup>[10,11]</sup>

- (c) The cracks, fissures and ulcers act as portals of entry for systemic infection, and as diabetics have an impaired innate immunity it significantly increases the risk of infection.<sup>[12]</sup>
- (d) Associated malnutrition with immunodeficiency also impairs wound healing.
- (e) Diabetes affects all systems and patients may have associated nephropathies, retinopathies, heart disease, renal failure, etc. all affecting the outcome of the healing ulcer.

### Initial evaluation

Screening is important for a variety of reasons. Hyperglycaemia plays a role in the pathogenesis of—microangiopathy, neuropathy and macrovascular disease (atherosclerosis).<sup>[2]</sup> All patients should undergo the following investigations -- complete blood counts, blood sugar levels, prothrombin time, partial thromboplastin time, renal and hepatic function tests, lipid profile, haemoglobin A1c levels, prealbumin levels and urinary albuminuria levels.<sup>[4]</sup> Plasma HbA1c levels (every 4 months) are done to monitor the long-term glucose control. Elevated HbA1c levels have been correlated with comorbidity like heart disease, retinopathy, neuropathy and nephropathy.<sup>[13]</sup> Prealbumin levels provide objective data that indirectly correlate with malnutrition. They are seen to be significantly lower in patients with pressure ulcers. In diabetics it may assist in diagnosing malnutrition and help in optimizing the nutritional status.<sup>[14,15]</sup> All diabetic patients with nephropathy should be screened annually for albuminuria as there is a high prevalence of micro- and macroalbuminuria in them. Foot ulcers are more common in microalbuminuric (13%) and macroalbuminuric (25%) patients compared to patients with normoalbuminuria (5%).<sup>[4]</sup>

### Investigations

#### Assessment of neuropathy

1. Ten gram Semmes--Weinstein monofilament
2. Self measurement of sole temperature
3. Dynamic plantar pressure measurement

Yearly somatosensory testing should be done to evaluate the level of sensations in diabetic feet.<sup>[16]</sup> This can be done using the 10 g Semmes--Weinstein monofilament.<sup>[17,18]</sup> Once the patient has lost sensations, self-measurement of sole temperature is a good method to prevent ulcers.<sup>[19-21]</sup> When focal differences of more than 4° are detected, reduced use of the foot until the temperature returned to normal (usually 2--4 days, maybe up to 4

weeks) helped avoid ulcers.<sup>[19]</sup> Paul Brand originally observed that prior to breakdown of the skin at the start of an ulcer; an inflammatory state developed leading to rise in local skin temperature in the affected area. Brand and Bergtholdt felt that if this area prior to breakdown is effectively managed, it may prevent permanent injury.<sup>[22]</sup>

### Assessment of arterial blood supply

1. Pedal pulses.
2. Ankle brachial index (ABI).
3. Toe pressures, Doppler echography waveforms.
4. Digital subtraction angiography (DSA).
5. Magnetic resonance angiography (MR Angio).

The pedal pulses need to be assessed in all patients. The presence of good volume and pressure pedal pulse precludes arterial disease. In the absence of a good pulse volume it is essential to measure the ankle brachial index (ABI). The ABI is a ratio of the highest systolic pressure at the ankle with the highest systolic pressure at the arm. An index of 0.9--1.3 is considered normal. In diabetics there may be a falsely elevated or normal ABI even in the presence of arterial disease because of atherosclerotic calcification of the vessels making the vessels noncompressible. This falsely elevates pressures. Toe pressures in diabetics are a better judge of vascularity. Doppler echography waveforms can also be seen. Dampened waves in the presence of normal ABI suggest calcified vessels. Once arterial disease is diagnosed, further investigations in form of DSA or MR Angio should be done. DSA is an accepted standard of arterial assessment. MR Angio has now been proven to be more accurate in diagnosing arterial disease than DSA as it can image blood flow at velocities as low as 2 cm/s.<sup>[23]</sup>

Patients with diabetes must understand their treatment goals and should essentially aim to attain glycaemic control, aggressive control of blood pressure and normalization of lipids. As mentioned by Levin they should 'avoid cigarette smoking, use prophylactic aspirin therapy, take excellent care of their feet, have regular medical examinations and avail appropriate interventions as needed. When this occurs on a regular basis, it should be possible to reduce the risk of complications and lessen the burden of diabetes'.<sup>[2]</sup>

### VENOUS DISEASE

#### Pathogenesis

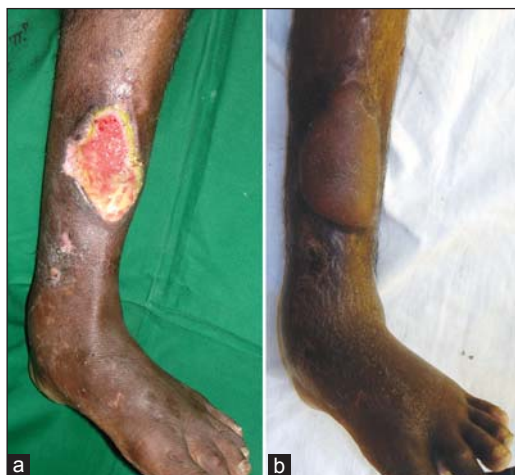The pathogenesis of chronic venous ulcers is an increased ambulatory venous hypertension with microcirculatory

abnormalities. Raffetto's article on chronic venous ulcers clearly elucidates the mechanism of action of formation of these ulcers. He describes that chronic venous ulcers result because of the consequences of persistent elevated venous ambulatory pressures on the dermal microcirculation. RBCs extravasate into the interstitium, where they are broken down. These breakdown products are chemo-attractive to leukocytes leading to leukocyte infiltration into the capillary and postcapillary venules. The leukocyte activation, cytokines and matrix metalloproteinases (MMP) sustain an inflammatory response that stimulates abnormal fibroblast collagen production, proliferation and pathologic fibrosis. This persistent inflammatory response leads to advanced dermal changes with lipodermatosclerosis and ulcer formation [Figure 1]. Additionally, chronic venous ulcer wound exudate perpetuates cellular inhibition and increases the cytokines of MMPs that impair cells and wound healing.<sup>[24]</sup> He postulates that therapies at each level of the pathway may help to modulate the disease process.

### Associated systemic factors

- (a) Increasing age.
- (b) Obesity.
- (c) Triple system disease.

Labropoulos' article on factors associated with poor healing and recurrence of venous ulceration concluded that advanced age, obesity, history of DVT, triple system venous disease, large ulcer area and patient noncompliance with compression therapy were all associated with ulcer nonhealing.<sup>[25]</sup> Increasing age together with varicose veins and pitting oedema is considered the most important risk factor for trophic skin changes.<sup>[26,27]</sup>



**Figure 1:** (a) Ulcer in a patient with PVD and venous disease showing skin changes, (b) skin changes persist after reconstruction with sural artery flap

### Initial evaluation

The American Venous Guidelines forum recommend that history and clinical examination of the lower limb for chronic venous disease should be detailed to include the following:<sup>[28]</sup> patients should be asked for symptoms of chronic venous disease, which may include tingling, aching, burning, pain, muscle cramps, swelling, sensations of throbbing or heaviness, itching skin, restless legs, leg tiredness and fatigue. On inspection, one should look for telangiectasia, varicosity, oedema, skin discoloration, corona phlebectatica, lipodermatosclerosis and ulcer. On palpation, examination for cord, varicosity, tenderness, induration, reflux, pulses, thrill, groin or abdominal masses is essential. On auscultation look for a bruit. Joint examination of ankle for mobility should be done.<sup>[28]</sup>

Concomitant ischaemic vascular disease should be ruled out.

In laboratory screening, besides all routine investigations evaluation for thrombophilia is required in patients with recurrent DVT and thrombosis at a young age.<sup>[28]</sup>

### Investigations

#### Complete duplex scanning

Including visualization, compressibility, venous flow, measurement of duration of reflux and augmentation reflux to confirm valvular competence in upright posture.<sup>[28]</sup>

#### Plethysmography

For those patients of advanced chronic venous disease when duplex scanning does not provide definitive information on pathophysiology.<sup>[28]</sup>

#### Imaging studies

Computed tomographic venography, magnetic resonance venography, ascending and descending contrast venography and intravascular ultrasonography can be used selectively (consider in following cases: post-thrombotic syndrome, thrombotic or nonthrombotic iliac vein obstruction, pelvic congestion syndrome, vascular malformations, venous trauma, tumours and planned open or endovascular venous interventions).<sup>[28]</sup>

All patients with venous disease must be advised compression stockings. If there is concomitant ischaemic disease stockings should not be used.



## NEUROGENIC ULCERS

These include all ulcers in insensate hands and feet in patients with neuropathies like Hansen's disease, syringomyelia, spina bifida, traumatic nerve injuries, diabetic neuropathies, polyneuritis of different causes, etc.

### Pathogenesis

Dr. Paul Wilson Brand (1914--2003) who worked with leprosy patients in South India in the mid-20th century made major contributions to the understanding of the pathogenesis, medical and surgical management of the neurological complications of leprosy. He famously said 'Pain is God's greatest gift to mankind'. He described pain as the gift that none of us want but none of us can do without. Till then it was considered that leprosy patients had nonhealing tissues and that nothing could be done about them. He pioneered the use of total contact casting (eliminating pressure directly on the ulcer using a plaster cast) and observed rapid healing of ulcers of even long duration. His clinical observations made him realize that the ulceration and paralysis found in leprosy were a result of cutaneous anaesthesia and nerve damage and not as a consequence of the infection itself. His research confirmed the relationship between repetitive pressure and ulceration in the insensitive limb.<sup>[29]</sup> Thus Brand's observations and research in leprosy are very relevant and important in the management of the insensate limbs of all aetiologies.

Neuropathic ulcers on the sole of feet or fingertips usually develop at sites exposed to repetitive high pressures during activities of daily living like walking or working. In people with normal sensation, avoidance measures like changing gait or modifying activity would relieve the discomfort of the repetitive pressure. In patients with peripheral sensory deficits, this protective pain perception being absent, they do not relieve pressures and hence the repetitive trauma leads to skin breakdown and ulceration.

In addition to the sensory component, modification of gait may also happen due to a motor weakness and muscle mass decrease seen in most patients of peripheral neuropathy. There may be a sharp increase of pressure under the forefoot with very high pressures localized to under the metatarsal heads and the heel.

The excessive pressure causes a hypertrophic reactive response of the local keratinocytes causing local hyperkeratosis. Hence at points of abnormal weight bearing and friction, callus formation may occur [Figure 2].

This callus finally cracks and breaks leading to ulceration. Hence, the risk of an ulcer is even higher when a callus is present. Importance of shaving callus at the margins of the ulcer and callus removal has shown reduction in dynamic plantar pressures in the forefoot by 30% during barefoot walking.<sup>[30]</sup>

### Initial evaluation

Every patient must undergo an initial comprehensive history and physical examination to find the root cause of the neuropathy-rule out diabetes, Hansen's disease, multiple sclerosis, polyneuropathies, etc.

Laboratory investigations for identifying nutritional deficiencies and achieving a positive nitrogen balance are necessary.

## MANAGEMENT

The key to successful management of a chronic ulcer would be to correctly identify the aetiology as well as the local and systemic factors that could be contributing to its nonhealing nature. Two algorithms are presented to describe the broad guidelines in management of this recalcitrant problem [Figures 3 and 4].

### History, clinical examination and investigations

A detailed history and clinical examination will help in diagnosing and classifying the ulcer as diabetic, venous, arterial, neuropathic, pressure sore or due to malnutrition. Once a clinical diagnosis is reached, the investigations recommended would be according to the concerned aetiology (to confirm the clinical diagnosis and for further management) as outlined in the sections above. Simultaneous wound management is started.

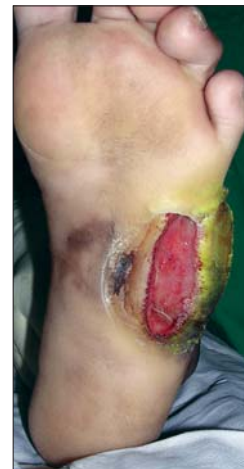

Figure 2: Hypertrophic skin and callus at site of hyper pressure

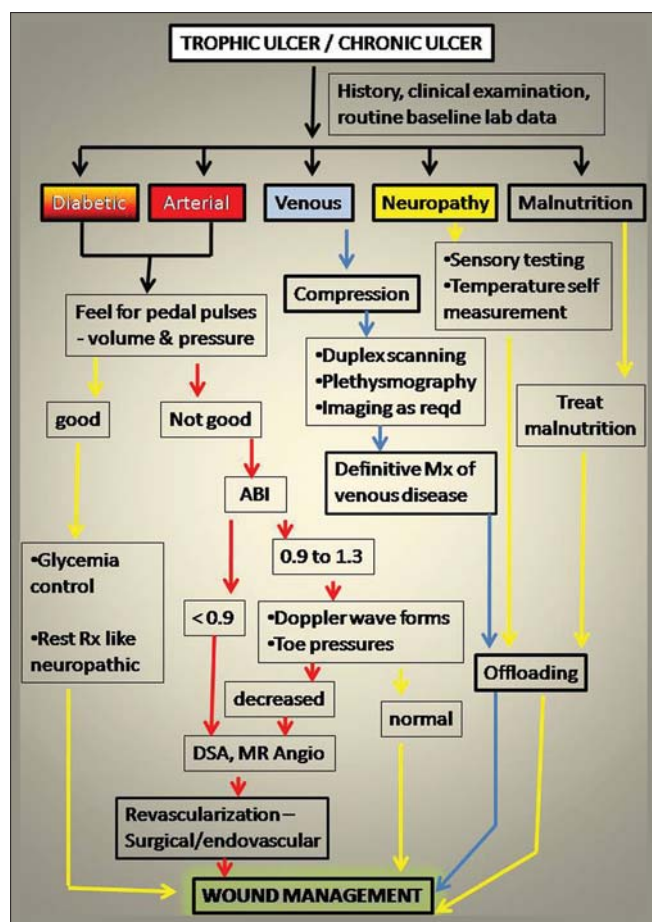


Figure 3: Algorithm for initial management and investigations

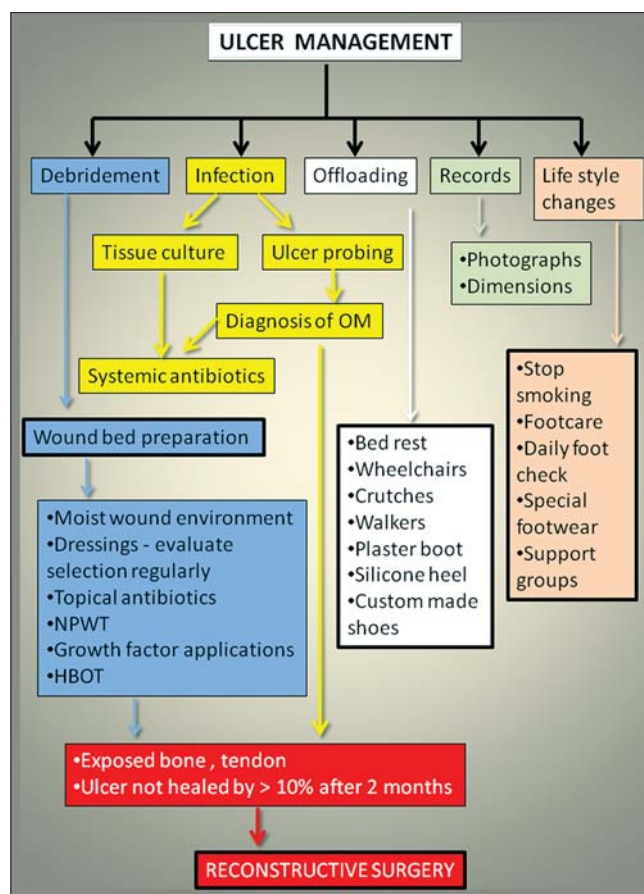


Figure 4: Algorithm for ulcer management

Control of hyperglycaemia and off-loading of pressure is begun immediately.

### Debridement

Wound management begins with debridement. Surgical debridement should be aggressive to include removal of all surrounding hard callus, hyperkeratotic skin, all dead necrotic tissue, infected soft tissue and bone. The end result of debridement should be soft, nonkeratotic wound edges with a well-vascularized tissue bed [Figure 5]. During debridement, activation of platelets for control of haemorrhage leads to release of growth factors which begins the process of healing.<sup>[31]</sup> After debridement wound bed preparation is started aimed at the goal of complete healing.

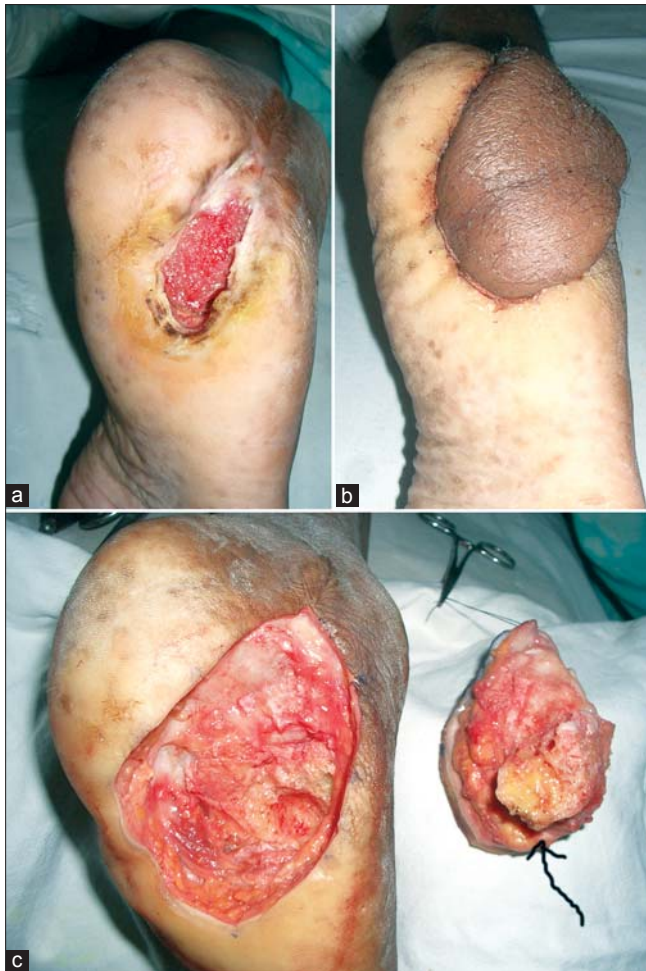### Microbiological tests and antimicrobial agents

During debridement a deep tissue culture should be taken. Different studies have been done regarding the efficacy of deep tissue culture vis-a-vis swabbing with some claiming swabs to be as effective as deep cultures<sup>[32]</sup> and some concluding that deep tissue cultures are more relevant.<sup>[33,34]</sup> During debridement, after the superficial

tissue is removed till a viable bed is reached, a tissue piece is removed from the depth for culture using a rongeur or blade. This should be the most reliable tissue culture for starting appropriate systemic antibiotic therapy.<sup>[4]</sup> Systemic antibiotics, oral or parenteral, are required only in the acute infective phase, in the presence of cellulitis or failure of a properly treated wound to heal. Clinical signs of infection include purulent secretions, two or more signs of inflammation (e.g. pain, redness, erythema, warmth, tenderness and induration), foul odour and presence of necrotic tissue.<sup>[4]</sup> [Figure 6] Once debridement is done topical antimicrobial therapies are adequate to help eliminate bacteria in the foot ulcer.<sup>[35]</sup>

### Osteomyelitis

To rule out osteomyelitis, probe the ulcer. If bone can be reached during an ulcer probing, no other test is required to diagnose osteomyelitis. Bone probing has a positive predictive value of 89%.<sup>[36]</sup> Radiograph should be done in all cases [Figure 7]. MRI and bone biopsy are presently the best tools for diagnosis of osteomyelitis when probing results are negative [Figure 8].



**Figure 5:** (a) Trophic ulcer involving bone, (b) reconstruction with regional flap (c) debridement with excision of osteomyelitic bone (arrow pointing to excised bone)

## Wound bed preparation

### Moist wound dressings

A moist wound environment facilitates rapid migration of keratinocytes across the wound bed. During a moist wound dressing, balance should be maintained between keeping the wound as moist as possible while avoiding maceration of the surrounding tissues. Classically moist wound dressings were done by keeping the wound wet with a constant irrigation fluid or by using an intermittent spray. With recent advances in dressing materials, advanced moist wound therapy (AMWT) can be easily given with hydrogels (INTRASITE Gel, Smith and Nephew, Hydroheal, Dr. Reddys) and alginates.

### Dressing material selection

Among the topical antimicrobial therapies available, mention needs to be made of the silver cation which is effective at eliminating antibiotic-resistant strains of bacteria. Silver is available in different types of

applications-silversulphadiazine creams, silver ion with hydrogel dressings (e.g. Hydroheal AM, Megaheal), silver nanocrystals barrier dressing (e.g. Acticoat). The silver barrier dressings destroy bacteria within the wound and as the antimicrobial barrier remains effective for up to 3 days it increases convenience for the patient and caregiver. Wounds which are exudative can be dressed with hydrocolloid dressings which can absorb the exudate. Dressing selection should be reassessed at regular intervals.

### Vacuum-assisted closure (VAC)/negative pressure wound therapy (NPWT)

Use of NPWT has increased over the years, and it is now a viable option. It is used after debridement in trophic ulcers for wound bed preparation leading to delayed primary or secondary wound closure. Results of a large NPWT randomized controlled trial demonstrated that NPWT is as safe as and more efficacious than advanced moist wound therapy (AMWT) in the treatment of diabetic foot ulcers. A significantly greater number of NPWT patients achieved complete ulcer closure and granulation tissue formation than AMWT patients. They also had decreased length of time required for ulcer healing compared with AMWT.<sup>[37]</sup>

### Hyperbaric oxygen therapy (HBOT)

HBOT is effective in the treatment of severe diabetic foot ulcers and should be utilized if available.<sup>[2]</sup> Benefits may be seen in those patients who are ischaemic and it may avoid amputations.<sup>[38]</sup> The Consensus Development Conference of the American Diabetes Association has recognized the value of adjunctive hyperbaric oxygen in difficult cases, stating that 'It is reasonable to use this modality to treat severe or limb-threatening wounds that have not responded to other treatments, particularly if ischaemia that cannot be corrected by vascular procedures is present'.<sup>[39]</sup>

### Growth factors

Topically applied growth factors may accelerate healing by stimulating granulation tissue formation and enhancing epithelialization. Single or isolated growth factors may be effective in healing diabetic ulcers, like platelet derived growth factor (PDGF).<sup>[4]</sup>

### Off-loading measures

Offloading pressure off the ulcer is the KEY to successful management of a trophic ulcer. Offloading can be in the form of strict bed rest, use of crutches, wheel chairs, walkers, pressure reducing measures like aircushion,



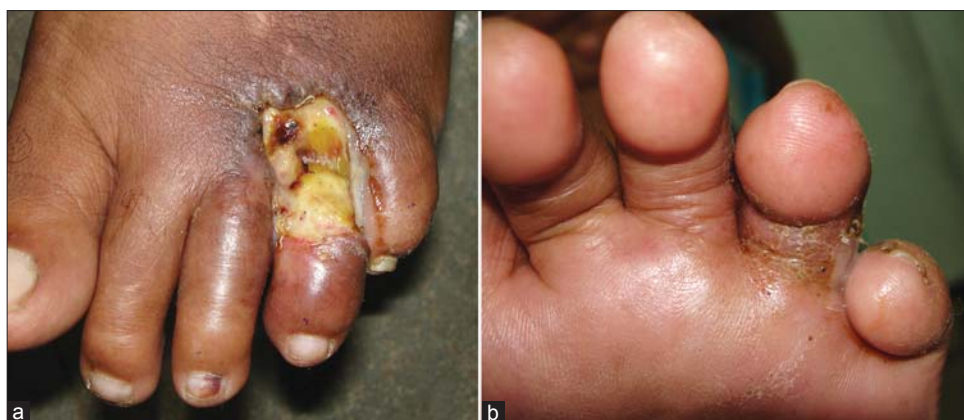

Figure 6: Infected diabetic foot ulcer with (a) exposed joint and tendons, (b) plantar surface showing erythema

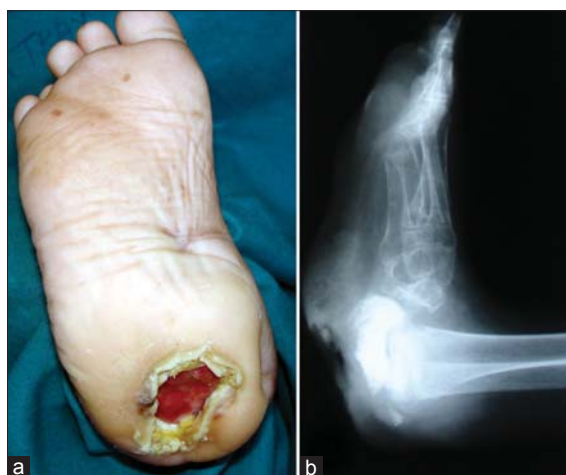

Figure 7: (a) Neuropathic bone deep ulcer, (b) radiograph showing bone destruction

waterbeds, plaster boot (total contact casting), removable contact casting, half shoes or specialized footwear. Transition from one offloading measure to the other should be slow. For example if a patient has been on bed rest and leg elevation, moving on to dependence and mobile offloading measures should be done in a graded manner. No offloading device will be of any benefit if it is not used consistently and if compliance is poor. Once the ulcer heals, in the early phase (6--8 weeks) it is yet liable to breakdown and more restrictive types of offloading devices need to be used before the patient can graduate to specialized footwear. The problem of recurrence persists because appropriate use of off-loading is very often not done.<sup>[40]</sup> Cavanagh and Bus's study on offloading pressures states that there is strong evidence to prove that uncomplicated plantar ulcers can heal in approximately 6 to 8 weeks with strict offloading. Though this was in sharp contrast to reported clinical experience in the 'standard of care' arms of U.S. clinical trials in which only 24% and 31% of uncomplicated

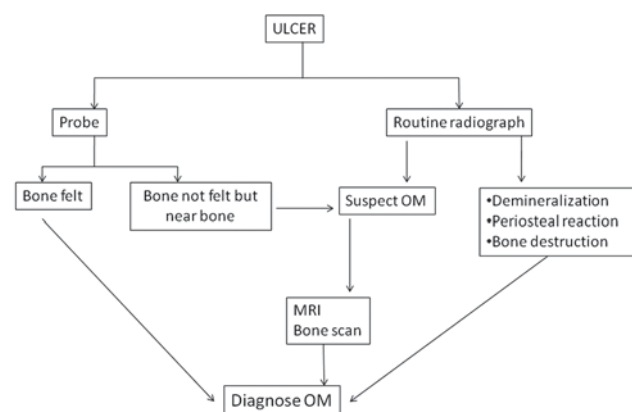


Figure 8: Algorithm for diagnosis of osteomyelitis

ulcers healed after 12 and 20 weeks, respectively, they believe that inadequate use of off-loading explains this difference. They add that many ulcers are complicated by factors such as infection and vascular disease, and the same expectations for time to heal cannot be applied to infected neuroischaemic wounds. However, off-loading is still important in such complex wounds.<sup>[41]</sup>

The best off loading device is a total contact cast (TCC)/ plaster boot.<sup>[42,43]</sup> TCC should be applied only after debridement and removal of all dead tissue. Its greatest advantage is that the problem of unreliability is taken care of as it is a nonremovable device. The drawbacks of a plaster boot are that it is technically demanding and if wrongly applied can lead to more ulcers. It does not allow daily inspection and cannot be used in ischaemic ulcers. The problem of a removable plaster cast is that patients tend to remove it more often than not, resulting in the off-loading becomes unreliable.

Once ulcers are healed, for preventive care special orthotic devices or footwear can be made to keep pressure off the



high pressure areas. In-shoe pressure measurements may be required to evaluate therapeutic shoe prescriptions in certain individual cases.<sup>[44]</sup> The full-length shoe total contact insert also provides pressure reduction with optimal compromise for cosmetic acceptance and function.<sup>[45]</sup>

### Reconstructive options

Surgical options for reconstruction should be considered for ulcers which have exposed bone, tendons and when the area of the ulcer has not decreased by more than 10% after sincere conservative management for 2 months.<sup>[4]</sup> Surgical options can range from skin grafts to local [Figure 9], regional or free flaps depending on the available donor tissue and the requirements of the defects. Common flaps done for foot ulcers are local transposition flaps, medial plantar artery flap, fillet flaps, distally based sural neurocutaneous flaps, VY plantar flaps and local muscle flaps.<sup>[46-52]</sup> Many authors have stated that tendon imbalance correction, particularly Achilles or gastroc-soleus tightness correction can help address foot problems and avoid ulcers.<sup>[53-55]</sup> Flexor tenotomies have also been suggested to decrease metatarsal head ulcers in patients with claw toes.<sup>[56]</sup>

### Nerve decompression

Lee Dellon's 1988 article first hypothesized that systemic metabolic abnormalities of diabetes rendered the peripheral nerve susceptible to chronic nerve compression.<sup>[57]</sup> This hypothesis has since been confirmed by many laboratory studies. Research literature also suggests that the diabetic nerve has an increased susceptibility to compression. Hence neurolysis for diabetic neuropathy is now followed by many surgeons worldwide. The compression and neuropathy can be documented by a nerve conduction study, quantitative sensory testing and positive Tinnel's sign at the site of compression. Aszmann *et al.*'s study of 20 patients who underwent decompression included only those who had a positive Tinnel sign located at the site of known

anatomic narrowing. They mention that a Tinnel's sign identifies the presence of nerve fibers with the capacity for regeneration.<sup>[58]</sup> Ducic *et al.*'s review article discusses the role of peripheral nerve surgery in diabetic limb salvage. They conclude that neurolysis as an adjunct therapy to medical treatment should be used when there is clinical and/or electrodiagnostic evidence of compression neuropathy and that results of peripheral nerve surgery are promising for the prevention of limb loss in chronic diabetes mellitus, for diminishment of pain and for restoration of sensory/motor function.<sup>[59]</sup>

### Foot/nail care

A daily foot check should be part of the patient's routine from the preventive aspect. Look out for fungal infection in the toenails. The toenails may also harbour bacteria. Topical antifungal agents can be used if fungal infection is diagnosed. If required debridement of the infected nail may have to be done. Routine grooming of nails and feet should be done in all cases of neuropathic feet. This includes regular trimming of nails, treatment of ingrown toe-nails and application of skin creams to keep the skin and nails soft. Regular chiropodist care is very effective in preventing ulcers in high risk individuals.<sup>[60,61]</sup>

### Avoid smoking and tobacco

Smoking reduces the rate of O<sub>2</sub> intake and delivery to the wound site and retards wound repair. Nicotine, carbon monoxide and hydrogen cyanide in the smoke also have a toxic effect on platelets and inhibit normal cellular metabolism which creates a deleterious environment for healing. Smoking is a risk factor due to its effects of vessel constriction (short-term) and the enhanced development of atherosclerosis (long term).<sup>[2]</sup> An increase in complications after primary amputations of the lower limb in patients who continued to smoke cigarettes postoperatively have been documented with rate of infection and reamputation being 2.5 times higher than that of nonsmokers.<sup>[62]</sup>

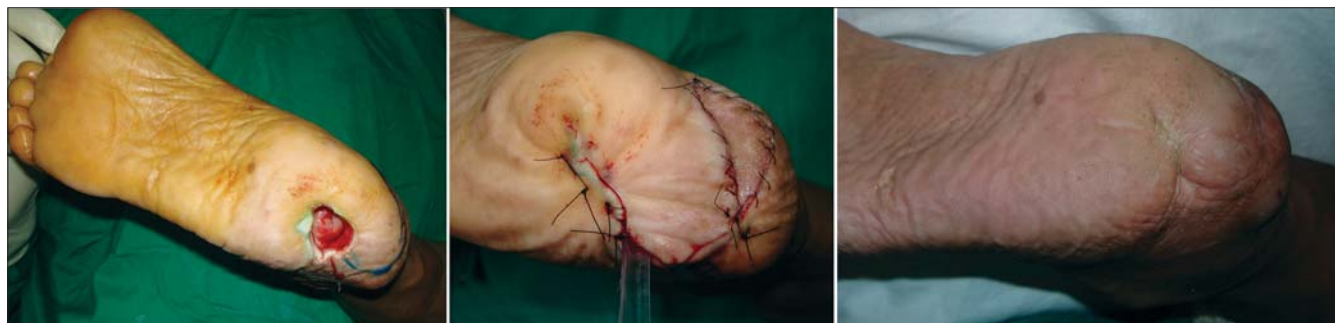

Figure 9: Neuropathic ulcer reconstructed with local flap (a) pre-, (b) intra- and (c) postop views

### Objective wound measurement/record keeping

Records of treatment, ulcer size and behaviour are an essential part of management as it keeps the treating surgeon and the patient aware of progress. Recordkeeping should be done by two methods-(a) photographic record of the ulcers, (b) document the length, breadth and depth measurements of the ulcer at weekly intervals. If the patient is on a home care regime measurements can be recorded by the caregivers at home. It helps to objectively analyse healing and motivates patients towards self-care.

### Patient education and home care

Patient education empowers the patient and their caregivers towards preventive measures. All high-risk individuals should have the benefit of disease specific education which can be in the form of one on one explanation by the primary physician, books, pamphlets, videos and/or disease support groups. The following are essential:

1. Explanation in simple terms about their specific pathology.
2. Understanding that changing habits and making a few lifestyle changes could go a long way to keep progression of disease and its consequences in check, e.g. leg elevation whenever possible, changing position to keep pressure off one point.
3. Cessation of smoking.
4. Regular chiropodist care (foot and nail grooming).
5. Strict glycaemia control for diabetics.
6. Compression for venous diseases.
7. Daily end of day check of hands and feet for signs of breakdown.
8. Self-monitoring of sole/fingertip temperature.
9. Specialized footwear for off-loading pressure.
10. Regular follow-up with physician even in periods of no ulcer stage.

### CONCLUSIONS

Care of patients with trophic ulcers needs to be multidisciplinary involving a large team which includes physician, general surgeon, plastic surgeon, endocrinologist, vascular surgeon, interventional radiologist, dietician, physiotherapist and chiropodist. The requirements of a patient with an ulcer would be best served if he/she would get all services under one roof. The need of the day in our country is to have wound care centres where all patients presenting with chronic ulcers and all high-risk patients can be referred. These patients could be started on a care program which would address their specific needs

and help bring down devastating complications like amputation.

### REFERENCES

1. Ghauri AS, Nyamekye IK. Leg ulceration: The importance of treating the underlying pathophysiology. *Phlebology* 2010;25 (Suppl 1):42-51.
2. O'Neal L. *The Diabetic Foot*. 7<sup>th</sup> ed. Mosby; Maryland Heights, U.S.A 2008. Pages 34,190-192, 24, 31, 350-351, 405.
3. Nazimek-Siewniak B, Moczulski D, Grzeszczak W. Risk of macrovascular and microvascular complications in Type 2 diabetes: Results of longitudinal study design. *J Diabetes Complications* 2002;16:271-6.
4. Brem H, Sheehan P, Rosenberg HJ, Schneider JS, Boulton AJ. Evidence-based protocol for diabetic foot ulcers. *Plast Reconstr Surg* 2006;117(7 Suppl):193S-209S; discussion 210S-211S.
5. Bosiers M, Peeters P, Elst FV, Vermassen F, Maleux G, Fourneau I, *et al.* Excimer laser assisted angioplasty for critical limb ischemia: Results of the LACI Belgium Study. *Eur J Vasc Endovasc Surg* 2005;29:613-9.
6. Laird JR, Zeller T, Gray BH, Scheinert D, Vranic M, Reiser C, *et al.* Limb salvage following laser-assisted angioplasty for critical limb ischemia: Results of the LACI multicenter trial. *J Endovasc Ther* 2006;13:1-11.
7. Mousa A, Rhee JY, Trocciola SM, Dayal R, Beauford RB, Kumar, *et al.* Percutaneous endovascular treatment for chronic limb ischemia. *Ann Vasc Surg* 2005;19:186-91.
8. Trocciola SM, Chaer R, Dayal R, Lin SC, Kumar N, Rhee J, *et al.* Comparison of results in endovascular interventions for infrainguinal lesions: Claudication versus critical limb ischemia. *Am Surg* 2005;71:474-9; discussion 479-80.
9. Faglia E, Mantero M, Caminiti M, Caravaggi C, De Giglio R, Pritelli C, *et al.* Extensive use of peripheral angioplasty, particularly infrapopliteal, in the treatment of ischaemic diabetic foot ulcers: Clinical results of a multicentric study of 221 consecutive diabetic subjects. *J Intern Med* 2002;252:225-32.
10. Falanga V. Wound healing and its impairment in the diabetic foot. *Lancet* 2005;366:1736-43.
11. Stojadinovic O, Brem H, Vouthounis C, Lee B, Fallon J, Stallcup M, *et al.* Molecular pathogenesis of chronic wounds: The role of beta-catenin and c-myc in the inhibition of epithelialization and wound healing. *Am J Pathol* 2005;167:59-69.
12. Bessman AN, Sapico FL. Infections in the diabetic patient: The role of immune dysfunction and pathogen virulence factors. *J Diabetes Complications* 1992;6:258-62.
13. Stratton IM, Adler AI, Neil HA, Matthews DR, Manley SE, Cull CA, *et al.* Association of glycaemia with macrovascular and microvascular complications of type 2 diabetes (UKPDS 35): Prospective observational study. *BMJ* 2000;321:405-12.
14. Frykberg RG. A summary of guidelines for managing the diabetic foot. *Adv Skin Wound Care* 2005;18:209-14.
15. Lansdown AB. Nutrition 2: A vital consideration in the management of skin wounds. *Br J Nurs* 2004;13:1199-210.
16. Mayfield JA, Reiber GE, Sanders LJ, Janisse D, Pogach LM. Preventive foot care in people with diabetes. *Diabetes Care* 2003;26 (Suppl 1):S78-9.
17. Mayfield JA, Sugarman JR. The use of the Semmes-Weinstein monofilament and other threshold tests for preventing foot ulceration and amputation in persons with diabetes. *J Fam Pract* 2000;49(11 Suppl):S17-29.
18. Singh N, Armstrong DG, Lipsky BA. Preventing foot ulcers in patients with diabetes. *JAMA* 2005;293:217-28.

19. Arad Y, Fonseca V, Peters A, Vinik A. Beyond the monofilament for the insensate diabetic foot: A systematic review of randomized trials to prevent the occurrence of plantar foot ulcers in patients with diabetes. *Diabetes Care* 2011;34:1041-6.
20. Lavery LA, Higgins KR, Lanctot DR, Constantinides GP, Zamorano RG, Armstrong DG, *et al.* Home monitoring of foot skin temperatures to prevent ulceration. *Diabetes Care* 2004;27:2642-7.
21. Lavery LA, Higgins KR, Lanctot DR, Constantinides GP, Zamorano RG, Athanasiou KA, *et al.* Preventing diabetic foot ulcer recurrence in high-risk patients: Use of temperature monitoring as a self-assessment tool. *Diabetes Care* 2007;30:14-20.
22. Bergtholdt HT, Brand PW. Thermography: An aid in the management of insensate feet and stumps. *Arch Phys Med Rehabil* 1975;56:205-9.
23. Dorweiler B, Neufang A, Kreitner KF, Schmiedt W, Oelert H. Magnetic resonance angiography unmasks reliable target vessels for pedal bypass grafting in patients with diabetes mellitus. *J Vasc Surg* 2002;35:766-72.
24. Raffetto JD, Marston WA. Venous ulcer: What is new? *Plast Reconstr Surg* 2011;127 (Suppl 1):279S-88S.
25. Labropoulos N, Wang ED, Lanier ST, Khan SU. Factors associated with poor healing and recurrence of venous ulceration. *Plast Reconstr Surg* 2011;129:179-86.
26. Carpentier PH, Maricq HR, Biro C, Poncot-Makinen CO, Franco A. Prevalence, risk factors, and clinical patterns of chronic venous disorders of lower limbs: A population-based study in France. *J Vasc Surg* 2004;40:650-9.
27. Musil D, Kaletova M, Herman J. Age, body mass index and severity of primary chronic venous disease. *Biomed Pap Med Fac Univ Palacky Olomouc Czech Repub* 2012;155:367-71.
28. Gloviczki P, Comerota AJ, Dalsing MC, Eklof BG, Gillespie DL, Gloviczki ML, *et al.* The care of patients with varicose veins and associated chronic venous diseases: Clinical practice guidelines of the Society for Vascular Surgery and the American Venous Forum. *J Vasc Surg* 2011;53:2S-48S.
29. Trautman JR, Kirchheimer WF, Prabhakaran K, Hastings RC, Shannon EJ, Jacobson RR, *et al.* An overview of Carville research. *Acta Leprol* 1981;July-Sept(84)1-29.
30. Young MJ, Cavanagh PR, Thomas G, Johnson MM, Murray H, Boulton AJ. The effect of callus removal on dynamic plantar foot pressures in diabetic patients. *Diabet Med* 1992;9:55-7.
31. Steed DL, Donohoe D, Webster MW, Lindsley L. Effect of extensive debridement and treatment on the healing of diabetic foot ulcers. *Diabetic Ulcer Study Group. J Am Coll Surg* 1996;183:61-4.
32. Pellizzer G, Strazzabosco M, Presi S, Furlan F, Lora L, Benedetti P, *et al.* Deep tissue biopsy vs. superficial swab culture monitoring in the microbiological assessment of limb-threatening diabetic foot infection. *Diabet Med* 2001;18:822-7.
33. Kessler L, Piemont Y, Ortega F, Lesens O, Boeri C, Averous C, *et al.* Comparison of microbiological results of needle puncture vs. superficial swab in infected diabetic foot ulcer with osteomyelitis. *Diabet Med* 2006;23:99-102.
34. Senneville E, Melliez H, Beltrand E, Legout L, Valette M, Cazaubiel M, *et al.* Culture of percutaneous bone biopsy specimens for diagnosis of diabetic foot osteomyelitis: Concordance with ulcer swab cultures. *Clin Infect Dis* 2006;42:57-62.
35. White RJ, Cooper R, Kingsley A. Wound colonization and infection: The role of topical antimicrobials. *Br J Nurs* 2001;10:563-78.
36. Grayson ML, Gibbons GW, Balogh K, Levin E, Karcher AW. Probing to bone in infected pedal ulcers. A clinical sign of underlying osteomyelitis in diabetic patients. *JAMA* 1995;273:721-3.
37. Blume PA, Walters J, Payne W, Ayala J, Lantis J. Comparison of negative pressure wound therapy using vacuum-assisted closure with advanced moist wound therapy in the treatment of diabetic foot ulcers: A multicenter randomized controlled trial. *Diabetes Care* 2008;31:631-6.
38. Roeckl-Wiedmann I, Bennett M, Kranke P. Systematic review of hyperbaric oxygen in the management of chronic wounds. *Br J Surg* 2005;92:24-32.
39. Consensus Development Conference on Diabetic Foot Wound Care: 7-8 April 1999, Boston, Massachusetts. American Diabetes Association. *Diabetes Care* 1999;22:1354-60.
40. Wu SC, Jensen JL, Weber AK, Robinson DE, Armstrong DG. Use of pressure offloading devices in diabetic foot ulcers: Do we practice what we preach? *Diabetes Care* 2008;31:2118-9.
41. Cavanagh PR, Bus SA. Off-loading the diabetic foot for ulcer prevention and healing. *Plast Reconstr Surg* 2011;127(Suppl 1):248S-56S.
42. Boulton AJ, Bowker JH, Gadia M, Lemerman R, Caswell K, Skyler JS, *et al.* Use of plaster casts in the management of diabetic neuropathic foot ulcers. *Diabetes Care* 1986;9:149-52.
43. Ha Van G, Siney H, Hartmann-Heurtier A, Jacqueminet S, Greau F, Grimaldi A. Nonremovable, windowed, fiberglass cast boot in the treatment of diabetic plantar ulcers: Efficacy, safety, and compliance. *Diabetes Care* 2003;26:2848-52.
44. Praet SF, Louwerens JW. The influence of shoe design on plantar pressures in neuropathic feet. *Diabetes Care* 2003;26:441-5.
45. Mueller MJ, Strube MJ, Allen BT. Therapeutic footwear can reduce plantar pressures in patients with diabetes and transmetatarsal amputation. *Diabetes Care* 1997;20:637-41.
46. Attinger CE, Ducic I, Cooper P, Zelen CM. The role of intrinsic muscle flaps of the foot for bone coverage in foot and ankle defects in diabetic and nondiabetic patients. *Plast Reconstr Surg* 2002;110:1047-54; discussion 55-7.
47. Gahalaut P, Pinto J, Pai GS, Kamath J, Joshua TV. A novel treatment for plantar ulcers in leprosy: Local superficial flaps. *Lepr Rev* 2005;76:220-31.
48. Giraldo F, De Haro F, Ferrer A. Opposed transverse extended V-Y plantar flaps for reconstruction of neuropathic metatarsal head ulcers. *Plast Reconstr Surg* 2001;108:1019-24.
49. Koshima I, Narushima M, Mihara M, Nakai I, Akazawa S, Fukuda N, *et al.* Island medial plantar artery perforator flap for reconstruction of plantar defects. *Ann Plast Surg* 2007;59:558-62.
50. Kuntscher MV, Erdmann D, Homann HH, Steinau HU, Levin SL, Germann G. The concept of fillet flaps: Classification, indications, and analysis of their clinical value. *Plast Reconstr Surg* 2001;108:885-96.
51. Pallua N, Di Benedetto G, Berger A. Forefoot reconstruction by reversed island flaps in diabetic patients. *Plast Reconstr Surg* 2000;106:823-7.
52. Shakirov BM. Different surgical treatment of post-burn trophic ulcers of the plantar surface in foot burns. *Burns* 2011;37:1439-43.
53. Greenhagen RM, Johnson AR, Peterson MC, Rogers LC, Bevilacqua NJ. Gastrocnemius recession as an alternative to tendoAchillis lengthening for relief of forefoot pressure in a patient with peripheral neuropathy: A case report and description of a technical modification. *J Foot Ankle Surg* 2010;49:159 e9-13.
54. Laborde JM. Tendon lengthening for neuropathic foot problems. *Orthopedics* 2010;33:319-26.
55. Laborde JM. Treatment of diabetic foot ulcers with tendon lengthening. *Am Fam Physician* 2009;80:1351; author reply 1351.
56. Tamir E, McLaren AM, Gadgil A, Daniels TR. Outpatient percutaneous flexor tenotomies for management of diabetic claw toe deformities with ulcers: A preliminary report. *Can J Surg* 2008;51:41-4.



57. Dellon AL. Optimism in diabetic neuropathy. *Ann Plast Surg* 1988;20:103-5.
58. Aszmann OC, Kress KM, Dellon AL. Results of Decompression of Peripheral Nerves in Diabetics: A Prospective, Blinded Study *Plast Reconstr Surg* 2000;106:816-22
59. Ducic I, Felder JM 3rd, Iorio ML The role of peripheral nerve surgery in diabetic limb salvage. *Plast Reconstr Surg*. 2011;127(Suppl 1):259S-269S.
60. Plank J, Haas W, Rakovac I, Gorzer E, Sommer R, Siebenhofer A, *et al.* Evaluation of the impact of chiropodist care in the secondary prevention of foot ulcerations in diabetic subjects. *Diabetes Care* 2003;26:1691-5.
61. Ronnema T, Hamalainen H, Toikka T, Liukkonen I. Evaluation of the impact of podiatrist care in the primary prevention of foot problems in diabetic subjects. *Diabetes Care* 1997;20:1833-7.
62. Lind J, Kramhoft M, Bodtker S. The influence of smoking on complications after primary amputations of the lower extremity. *Clin Orthop Relat Res* 1991;Jun(267)211-7.

**How to cite this article:** Puri V, Venkateshwaran N, Khare N. Trophic ulcers-Practical management guidelines. *Indian J Plast Surg* 2012;45:340-51.

**Source of Support:** Nil, **Conflict of Interest:** None declared.