

## Original Article

# Thoracodorsal artery perforator fasciocutaneous flap: A versatile alternative for coverage of various soft tissue defects

Celalettin Sever, Fatih Uygur, Yalcin Kulahci, Huseyin Karagoz, Cihan Sahin

Department of Plastic and Reconstructive Surgery and Burn Unit, Gulhane Military Medical Academy and Medical Faculty, Haydarpasha Training Hospital, Istanbul, Turkey

**Address for correspondence:** Dr. Celalettin Sever, Department of Plastic and Reconstructive Surgery and Burn Unit, Gulhane Military Medical Academy and Medical Faculty, Haydarpasha Training Hospital, Istanbul, Turkey. E-mail: drcsever@hotmail.com

### ABSTRACT

**Objective:** The thoracodorsal artery perforator (TDAP) flap has contributed to the efficient reconstruction of tissue defects that require a large amount of cutaneous tissue. The optimal reconstruction method should provide thin, and well-vascularized tissue with minimal donor-site morbidity. The indications for the use of this particular flap with other flaps are discussed in this article. **Materials and Methods:** Thirteen patients underwent soft tissue reconstruction using TDAP flaps between 2009 and 2011. Of those, there were four cases of antecubital burn contracture, three cases of axillary burn contracture, two cases of giant hair cell nevus of upper extremity, two cases of axillary reconstruction following severe recurrent hidradenitis, and two cases of crush injury. All patients were male and their ages ranged from 20 to 23 (average, 21 years). The mean follow-up period was 8 months (range, 4-22 months). **Results:** All reconstructive procedures were completed without any major complications. Minor complications related to transferred flaps were wound dehiscence in one case, transient venous congestion in two cases. Minor complication related to the donor site was seroma in one case. The success rate was 100%, with satisfactory cosmetic results. **Conclusions:** The TDAP flap is a safe and extremely versatile flap that offers significant advantages in acute and delayed reconstruction. Although the vascular anatomy may be variable, free and pedicled TDAP flap is a versatile alternative for soft tissue defects. It adapts very well to the soft tissue defects with acceptable donor site scar.

### KEY WORDS

Burn contracture; hidradenitis suppurativa; soft tissue defects; the thoracodorsal artery perforator; thoracodorsal artery perforator flap

### INTRODUCTION

The thoracodorsal artery perforator (TDAP) flap is a relatively new member of the perforator flap family in reconstructive surgery. Over the past years, free or pedicled transfers of TDAP flap were used for reconstruction of defects that require a large amount of cutaneous tissue. It has been used as a pedicled flap for reconstruction of regional soft tissue defects, including trunk, axilla and breast, or as a free flap in reconstruction of

Access this article online	
Quick Response Code:	Website: www.ijps.org
	DOI: 10.4103/0970-0358.105956

various distant tissue defects such as face, elbow, forearm and lower extremity.<sup>[1-5]</sup> Advantages of the TDAP flap include simultaneous flap elevation, easy dissection, minimal donor-site morbidity, and constant vascular anatomy with a long pedicle. Therefore, the TDAP flap has become more popular among reconstructive surgeons recently.<sup>[4-8]</sup>

Up to the present time, there are not sufficient articles published concerning the versatile use of the TDAP flap in soft tissue reconstruction. We have used a number of designs of the TDAP flap, depending on the needs of the recipient areas, including free and local pedicle fasciocutaneous flaps. Our experience is presented in this article.

## MATERIALS AND METHODS

Thirteen patients were reconstructed with TDAP flap between July 2009 and July 2011 in our department. All patients were male and their ages ranged from 20 to 23 years old (average, 21 years). There were four cases of antecubital burn contracture, three cases of axillary burn contracture, two cases of giant hair cell nevus of upper extremity, two cases of axillary reconstruction following severe recurrent hidradenitis, and two cases of crush

injury. The size and orientation of the skin islands were planned according to the defect sizes and orientations. The details of the patients are given in Table 1.

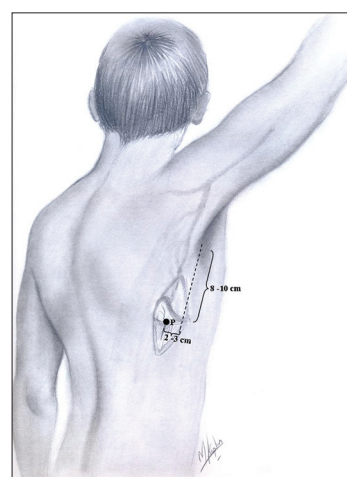
## SURGICAL TECHNIQUE

A marking line was drawn from the posterior axillary fold to the posterior superior iliac spine, which demarcates the lateral border of the latissimus dorsi muscle. The location of cutaneous perforators of the thoracodorsal artery on the back were marked using a handheld Doppler preoperatively. Subsequently, we designed fasciocutaneous TDAP flap preoperatively, including the point where the cutaneous perforator was marked, as its long axis was perpendicular to the running of the latissimus dorsi muscle [Figure 1]. The proximal perforator was usually located 8-10 cm below the axilla and 2-3 cm behind the lateral border of the latissimus dorsi muscle.

All the cases were positioned in a lateral decubitus position with the arm abducted 90 degree over the head to achieve flap elevation under general anaesthesia. The flap size and shape was designed according to the defect size, with incorporation of the point of perforator artery to obtain a long pedicle for free flap transfer and provide appropriate mobilization for pedicled flap transfers. Usually pedicled flaps were designed in such a way that the perforator enters the skin paddle right in the centre of flap skin island. However, the free flaps were designed on the basis of the proximal perforator, which was placed on the proximal third of the flap to

**Table 1: The dermographic features of the patients**

Case number	Age/ Sex	Cause	Flap size	Type of flap	Complications
1	20/M	Antecubital burn contracture	18×9 cm	Pedicled	None
2	23/M	Hidradenitis	15×9 cm	Pedicled	None
3	21/M	Axillary burn contracture	16×7 cm	Pedicled	Seroma in donor site
4	21/M	Antecubital burn contracture	20×12 cm	Pedicled	Venous congestion
5	20/M	Axillary burn contracture	16×10 cm	Pedicled	Wound dehiscence
6	20/M	Giant hair cell nevus	14×7 cm	Free	None
7	20/M	Axillary burn contracture	16×9 cm	Pedicled	None
8	22/M	Antecubital burn contracture	19×8 cm	Pedicled	None
9	23/M	Antecubital burn contracture	15×10 cm	Free	Venous congestion
10	21/M	Hidradenitis	18×12 cm	Pedicled	None
11	20/M	Crush injury	16×9 cm	Free	None
12	21/M	Crush injury	13×8 cm	Free	None
13	20/M	Giant hair cell nevus	15×9 cm	Free	None



**Figure 1:** Locating the perforators and flap designs in lateral decubitus position. The dotted line is the lateral border of the latissimus dorsi muscle. Point P is the point presenting the main perforator artery of flap. Point P is usually located in 2-3 cm from the lateral margin of the LD

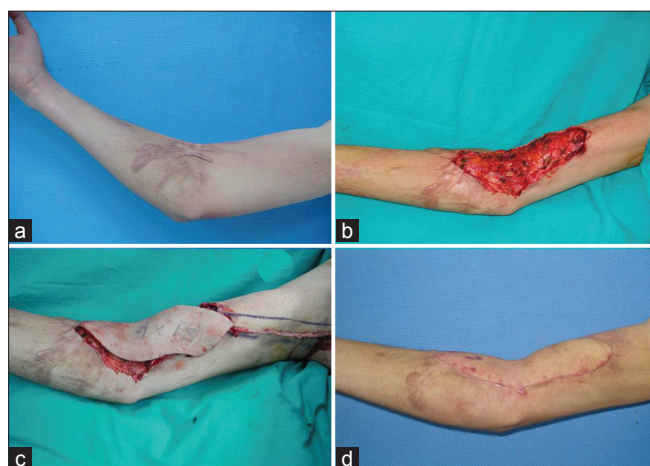increase effective pedicle length, and the size of the flap. The first incision was made at the lateral margin of the flap, and dissection was carried carefully out medially through the loose areolar tissue above the muscle under loupe magnification for identification of the pulsating perforator. The fascia was incised in order to carry out a subfascial dissection plane. After identifying the pulsating perforator, dissection was continued through the muscle until the thoracodorsal vessels were found. In all of these cases the pedicle was dissected as high as the bifurcation of subscapular artery. However, a very tiny amount of muscle was added to the pedicled flap in order to prevent any harm to the perforators for pedicled flap transfers. During this dissection, the thoracodorsal nerve and its branches were preserved. The flap was harvested on the thoracodorsal perforator and separated from the underlying muscles. Subsequently, the flap was transferred to the defect. The pedicled flap was tunneled in every case towards the defect. At this step, it was important to be careful not to damage the perforator and to avoid all external pressure. In all cases, the donor site was closed primarily and negative pressure aspiration drains was inserted. A follow-up of the flaps was done by clinical observation of capillary refilling, congestion, and handheld Doppler.

## CASE REPORTS

Four clinical cases are described in detail.

### Case 1

A 20-year-old man had suffered postburn right antecubital



**Figure 2:** (a) Severe antebraclial contracture. (b) Intraoperative view of contracture releasing. (c) 19 × 8 cm the thoracodorsal artery perforator flap was elevated and transferred the defect area. (d) Postoperative appearance 8 months after surgery

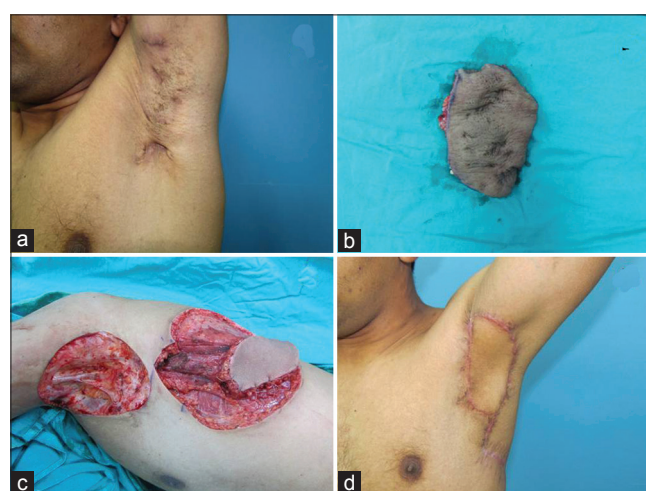burn contracture causing restriction of extremity abduction for 12 years due to flame burn. The patient had not previously undergone reconstructive surgery. The TDAP flap was planned for reconstruction. During the operation, the contracted scar was completely released. The thoracodorsal perforator-based cutaneous flap, 18 × 9 cm in size, was harvested by including the first two perforators of the lateral branch of thoracodorsal artery. After complete elevation of the flap, thinning was performed except at the area 1 cm around the vascular perforator. Subsequently, the flap then transferred to the defect on its pedicle and sutured in defect. The donor site was closed primarily. There was no restriction of the extremity abduction at 8-months postoperatively. The result was accepted as satisfactory by the patient and the physician [Figure 2].

### Case 2

A 23-year-old man referred for assessment and treatment of axillary hidradenitis suppurativa that had evolved over 10 years. He had undergone several conservative treatments with recurrence of the lesion. During the operation, all the hair-bearing area was completely resected. The pedicled TDAP flap was planned according to the defect size and subsequently, TDAP flap was performed to coverage of the defect. The donor area of TDAP was closed primarily. The TDAP flap survived completely, and all wounds healed without complication. The patient was able to complete arm abduction 3 weeks after surgery. A satisfactory result was obtained without long-term recurrence [Figure 3].

### Case 7

A 20-year-old man patient sustained a flame burn to



**Figure 3:** (a) Preoperative view of chronic left axillary hidradenitis. (b) Excision of hydraadenitis. (c) Design of a the thoracodorsal artery perforator flap according to the defect size. (d) View 10 months after surgery

his upper extremity and lateral thoracic area when he was 2-years-old. His burns were allowed to heal spontaneously with resulting axillary contracture. This contracture was limited his mobility during sport activities. The TDAP flap was chosen due to its surgical proximity and resemblance in skin texture. During the operation, the scar tissues and the contracture bands in the axillar area was removed and his shoulder joint was released completely. The TDAP flap was harvested on a single perforator and passed through the skin tunnel toward the defect. The donor site was closed primarily. The postoperative course and healing of the recipient area was uneventful. Ten months after surgery, TDAP flap adapted to the axillary region perfectly, and the patient was able to abduct his arm to 160 degree without any difficulty in the postoperative period [Figure 4].

### Case 11

A 20-year-old man had sustained an injury to the left foot dorsum while driving a car. He had referred to another center, where the dorsum defect was skin-grafted. Seven years after the initial trauma, he applied to our department. The free TDAP flap was planned for reconstruction. During the operation, the scar tissue was completely removed. The free TDAP flap 16 × 9 cm in size was designed and elevated to transfer the defect. The thoracodorsal artery and vein of flap were anastomosed to the posterior tibial artery and vein. The flap donor site was closed primarily without grafting. The patient was fully mobilized 3 weeks

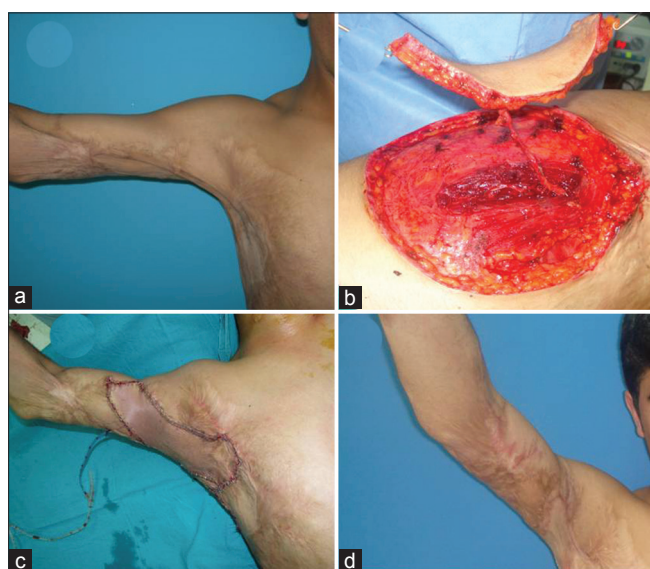after the reconstruction. The follow-up period was 17 months. Flap contour was good, and no debulking procedures were required [Figure 5].

### RESULTS

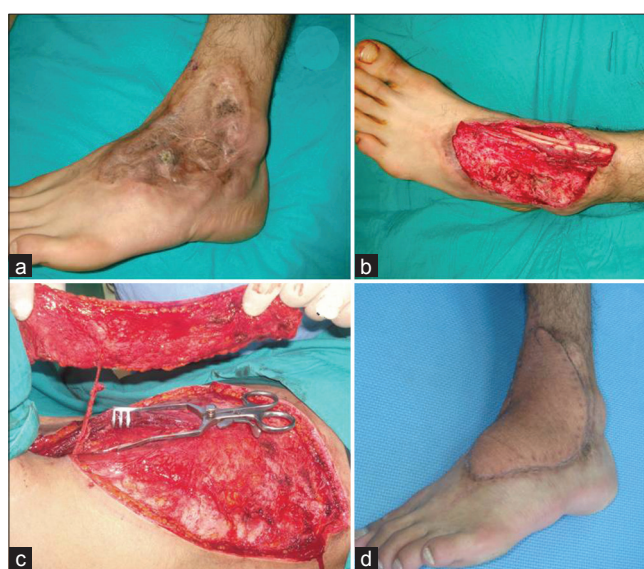
Dimensions of the flaps were determined according to the localization and orientations of soft tissue defects. The largest dimension of the TDAP flap used was 20 × 12 cm. No partial or complete flap loss was seen. Minimal venous congestion was observed in two flaps in the early postoperative period. This condition recovered spontaneously within 3 days. Minor complication related to the donor site was seroma in one case. The initial edema and bulky appearance was diminished by the 6<sup>th</sup> month. All flaps remained stable and donor sites healed uneventfully. The mean operation time was 4 hours for free flap transfer and 2.5 hours for pedicled flap transfer. The average hospital stay was 16 days. Follow-up after surgery ranged from 4 months to 22 months. The linear scars in donor areas were acceptable during late follow-up period. Self-reported cosmesis was rated “acceptable” in all patients. Additional flap thinning procedures were not necessary after the operations. The results and clinical characteristics of the patients are given in Table 1.

### DISCUSSION

The perforator flap depending on muscle perforators without including the underlying muscle was first



**Figure 4:** (a) Severe axillary burn contracture. (b) The thoracodorsal artery perforator flap on a single perforator. (c) Intraoperative view. (d) Postoperative appearance 14 months after surgery



**Figure 5:** (a) Crush injury on the left foot. (b) A wide soft tissue defect after the scar tissue was excised. (c) A free The thoracodorsal artery perforator flap, in 16 × 10 cm in size. (d) Postoperative appearance 17 months after surgery

described by Koshima and Soeda in 1989.<sup>[9]</sup> Recently, the perforator-free flap is becoming increasingly popular because of its thinness, versatility, and low donor-site morbidity. The possibility of the thoracodorsal perforator flap was described by Angrigiani *et al.*<sup>[10]</sup> and many authors presented their experience with it since then. Spinelli *et al.* reported the presence of a predictable row of perforators from the lateral intramuscular branch of the thoracodorsal artery.<sup>[11]</sup> Kim *et al.* reported the use of thin latissimus dorsi perforator flaps including only the superficial adipose layer.<sup>[12]</sup> Binu *et al.* reported the cutaneous vascular supply of the thoracodorsal artery and the number and type of perforators by means of human cadaver dissection.<sup>[13,14]</sup>

The TDAP flap is popular perforator flap among reconstructive surgeons and it is the first flap choice in some clinics for the coverage of soft-tissue defects. The advent of microsurgical techniques has allowed this versatile flap to be transposed to reconstruct soft-tissue defects all around the body. In this study, the series of patients presents multiple versatile uses of TDAP flaps, according to experiences at our institution.

The reliability of the TDAP flap will depend on the presence and size of the perforating vessels.<sup>[4]</sup> The TDAP flap have two or three skin perforator arteries. A predictable row of perforators arise from the lateral branch of the thoracodorsal artery.<sup>[10]</sup> The first perforator artery reaches the subcutaneous tissue at a point located 2 or 3 cm behind the lateral edge of the latissimus dorsi muscle and 8-10 cm below the posterior axillary fold. The second perforator artery is located 1-2 cm below the previous one. All these perforator arteries give off numerous muscular branches before penetrating the fascia to supply the overlying skin and subcutaneous fat layers.<sup>[6-8,15,16]</sup> Even though the distribution of perforators varies widely, a good understanding of the entire perforator anatomy is essential for safe and efficient harvesting of the thoracodorsal artery perforator flap.<sup>[14]</sup>

TDAP flap has the common advantages of perforator flaps. While harvesting flap, preservation of the innervation and vascularization of the latissimus dorsi muscle provide less donor site complications. In addition, the TDAP flap offers distinct advantages, including a large flap dimension, a long pedicle length and excellent contour restoration.<sup>[6-8,17]</sup>

Soft tissue defects on the lower and upper extremity

require thin flaps, and patients who have relatively thin back tissue with the pinch test are ideal candidates for TDAP flap reconstruction.<sup>[17]</sup> The defects of shoulder and axilla have the same soft tissue properties like the donor site and TDAP flap provides good coverage when transferred pedicled to these areas. Hidradenitis suppurativa is a chronic and recurrent inflammatory disease of the apocrine glands characterized by recurrent abscesses frequently located in the axilla.<sup>[17]</sup> The surgical removal of all apocrine glands with wide excision of all hair-bearing skin in the axilla and covering the defect with a fasciocutaneous flap is the definitive treatment to eradicate the recurrence. To best of our knowledge, up to date, usage of the TDAP flap for the reconstruction of hidradenitis suppurativa have been reported by only a few authors.<sup>[3,15,17]</sup>

Patients with severe postburn contractures have many difficulties in their daily life.<sup>[6-8]</sup> These contractures often cause cosmetic problems and functional deficiency. Release of antecubital and axillary burn contractures results in relatively large soft-tissue defects in this region was seen. The aim of surgical correction is the restoration of movements at the shoulder joint that will permit the strategic positioning of the hand in its preoccupation with the activities of daily living.<sup>[18]</sup> Z-plasties, local flaps, island flaps, and free flaps, have been reported for treatment of the contractures. Although these techniques are effective for linear contractures, they are not suitable in patients with severe contractures. The TDAP flap may be safely raised to meet any size required even in the most severe contractures.<sup>[19]</sup> Recently, our team reported the use of TDAP flaps for the reconstruction of axillary, antecubital and thenar contractures.<sup>[6-8]</sup>

Defects of the foot and ankle with exposed tendons or bone require either local or free flap coverage. These areas are easily susceptible to trauma and are the site of numerous trophic problems (e.g., pressure sores, chronic ulcers, and penetrating injuries). Free flaps in the lower extremity may be necessary for high-energy injuries, open fractures of the middle and distal one-third tibia, radiation injuries, osteomyelitis, and large, soft tissue defect exposing bone tissue after radical resections of the tumors.<sup>[20,21]</sup> Several publications in recent years have proven popularity of free fasciocutaneous flaps for the coverage of defects of the foot and ankle. An ideal reconstruction should be stable, thin, well contoured and durable to friction forces caused by footwear. In addition, the flap chosen should be easy to execute quickly with minimal discomfort to the patient

and should provide durable coverage for the defect.<sup>[22]</sup> Among the fasciocutaneous free flap alternatives for soft tissue defects, the lateral arm flap, the scapular flap, the radial forearm flap, the anterolateral thigh flap, superficial circumflex inferior artery flap, superficial inferior epigastric artery flap may be used. The anterolateral thigh flap has gained great popularity among reconstructive and recently has become the first-choice flap at many centers for the reconstruction of soft-tissue defects. However, compared with TDAP flap, the ALT flap has numerous disadvantages. One disadvantage is that the anatomy of the perforator supplying the ALT flap is variable. The perforator may have different pathways such as septocutaneous, musculocutaneous, septomusculocutaneous, and the axial pattern leading ultimately to the source vessels. The variability of perforators and the difficult dissection of the musculocutaneous perforator may be the major challenge for a surgeon. Surgical dissection may easily damage the pedicle. Another disadvantage is the large number of musculocutaneous perforators, which are difficult to dissect without some sacrifice of the vastus lateralis muscle and its peripheral motor nerves. Sometimes patients complain of sensory deficits in the donor site. Infrequently, conspicuous flap donor site scar may be a disadvantage especially for females. Transferring hair-bearing tissue to the soft tissue defects like cervical area may be another disadvantage.<sup>[23]</sup> Compared with TDAP flap, scapular and parascapular flaps are also elevated from the same donor area and have similar skin texture. However, the pedicles of these flaps are shorter when compared with TDAP flap, and this limits the freedom in pedicled and free transfers. In addition, the donor-site morbidity; the need for a secondary defatting procedure; requirement for a change of position during the operation are the other disadvantages.<sup>[24-27]</sup> The thickness of a free TDAP flap is between that of a radial forearm and scapular flap. The free TDAP flaps are able to resurface defects of any size and provide different types of tissue for reconstruction of composite defects. The free TDAP flap offers a long pedicle that may reach recipient vessel distant to soft tissue defects. On the other hand, a long pedicle provides an extensive arc of rotation in pedicled transfers. When the thoracodorsal artery perforator flap is based on a distal perforator, it has been reported that the pedicle length may reach up to 23 cm.<sup>[4]</sup> In our series, the pedicle length was 17-21 cm, with an average pedicle length of 20.0 cm.<sup>[6]</sup> To the best of our knowledge, there are a few reports demonstrating the free TDAP flap for reconstruction of dorsal surface of foot defects in literatures.<sup>[5,28]</sup>

Despite lots of advantages and versatility as mentioned

above, there are also some disadvantages of TDAP flap. The meticulous planning and preoperative perforator mapping is required in order not to place the flap outside the angiosome of perforators, and this takes surgical experience. In clinical practice, identification of these skin perforators may be performed using some anatomic landmarks. The handheld Doppler study is useful in identifying the preoperative identification of perforators. There is a general correlation between the audible volume of the signal and the diameter of the perforator. Patient positioning and dissection of the perforator may increase operative time because of variations of the perforator anatomy. For this reason, the surgeon should be fully aware of perforator topographic variations. The meticulous dissection is worthwhile to obtain a longer pedicle because TDAP is not an axial flap and flap vascularization to the most distant parts is difficult to predict. This situation may predispose to partial fat and skin necrosis. The other disadvantage of the TDAP flap is scar widening or hypertrophic scar of the donor site in some of patients with relatively large flap dimensions.<sup>[8]</sup> The skin paddle is still too bulky in some circumstances, such as in resurfacing defects of the head and neck and in reconstructing defects resulting from traumatic injury of the hand or foot. The thinning procedure may be an ideal solution for these problems.<sup>[29,30]</sup> Although our study demonstrated a low incidence of flap complications, care must be taken in high-risk patients such as smokers and patients with associated comorbid diseases to decrease the risk of flap failure.

Our clinical experience with the TDAP flap in reconstruction of soft tissue defects at the same institution is described.<sup>[6-8]</sup> The location of defects has been variable and includes the neck, trunk, and upper and lower extremities. Our overall experience consists of 33 cases since 2004. Based on the data, according to our clinical experience, TDAP flap has many advantages in comparison with other perforator flaps, including the following:

1. The flap width may reach up to 7-12 cm, and the donor-site wound may be primarily closed without further skin graft coverage. The donor-site scar may be well hidden underneath the arm and in the underwear
2. The TDAP flap contains no muscle, allowing more reconstructive precision, and morbidity is minimised by preserving the function of the latissimus dorsi muscle. TDAP flap provide stable coverage with an acceptable aesthetic appearance for both the donor and reconstruction sites in long-term follow-up

3. The subcutaneous fat tissue at the back region is relatively thinner and thus may provide a thinner skin
4. The flap may provide an extra long pedicle. This feature provides a greater arc of rotation when the flap is used as an island flap. It also allows microvascular anastomosis outside the zone of injury when the flap is used as a free flap
5. The skin island may harvest along with intercostal nerves, this gave us the potential to develop a sensate flap
6. The versatility of the subscapular artery system facilitates combined or chimeric flap elevation.

In conclusion, TDAP flap is a versatile alternative in soft tissue reconstruction both as a free and a pedicled flap, which may be used for a wide range of indications in appropriately selected patients. The success of the TDAP flap depends on patient selection, coordinated planning, and meticulous surgery.

## REFERENCES

1. Khoobehi K, Allen RJ, Montegut WJ. Thoracodorsal artery perforator flap for reconstruction. *South Med J* 1996;89:S110-7.
2. Schwabegger AH, Bodner G, Ninkovic M, Piza-Katzer H. Thoracodorsal artery perforator (TAP) flap: Report of our experience and review of the literature. *Br J Plast Surg* 2002;55:390-5.
3. Hamdi M, Van Landuyt K, Monstrey S, Blondeel P. Pedicled perforator flaps in breast reconstruction: A new concept. *Br J Plast Surg* 2004;57:531-9.
4. Guerra AB, Metzinger SE, Lund KM, Cooper MM, Allen RJ, Dupin CL. The thoracodorsal artery perforator flap: Clinical experience and anatomic study with emphasis on harvest techniques. *Plast Reconstr Surg* 2004;114:32-43.
5. Van Landuyt K, Hamdi M, Blondeel P, Monstrey S. The compound thoracodorsal perforator flap in the treatment of combined soft-tissue defects of sole and dorsum of the foot. *Br J Plast Surg* 2005;58:371-8.
6. Uygur F, Sever C, Tuncer S, Alagöz S. Reconstruction of postburn antebraichial contractures using pedicled thoracodorsal artery perforator flaps. *Plast Reconstr Surg* 2009;123:1544-52.
7. Uygur F, Kulahci Y, Sever C, Duman H. Reconstruction of postburn thenar contractures using the free thoracodorsal artery perforator flap. *Plast Reconstr Surg* 2009;124:217-21.
8. Kulahci Y, Sever C, Uygur F, Oksuz S, Sahin C, Duman H. Pre-expanded pedicled thoracodorsal artery perforator flap for postburn axillary contracture reconstruction. *Microsurgery* 2011;31:26-31.
9. Koshima I, Soeda S. Inferior epigastric artery skin flaps without rectus abdominis muscle. *Br J Plast Surg* 1989;42:645-8.
10. Angrigiani C, Grilli D, Siebert J. Latissimus dorsi musculocutaneous flap without muscle. *Plast Reconstr Surg* 1995;96:1608-14.
11. Spinelli HM, Fink JA, Muzaffar AR. The latissimus dorsi perforator-based fasciocutaneous flap. *Ann Plast Surg* 1996;37:500-6.
12. Kim JT, Koo BS, Kim SK. The thin latissimus dorsi perforator-based free flap for resurfacing. *Plast Reconstr Surg* 2001;107:374-82.
13. Thomas BP, Geddes CR, Tang M, Williams J, Morris SF. The vascular basis of the thoracodorsal artery perforator flap. *Plast Reconstr Surg* 2005;116:818-22.
14. Mun GH, Lee SJ, Jeon BJ. Perforator topography of the thoracodorsal artery perforator flap. *Plast Reconstr Surg* 2008;121:497-504.
15. Ortiz CL, Castillo VL, Pilarte FS, Barraguer EL. Experience using the thoracodorsal artery perforator flap in axillary hidradenitis suppurativa cases. *Aesthetic Plast Surg* 2010;34:785-92.
16. Ortiz CL, Mendoza MM, Sempere LN, Sanz JS, Torres AN, Barraguer EL. Versatility of the pedicled thoracodorsal artery perforator (TDAP) flap in soft tissue reconstruction. *Ann Plast Surg* 2007;58:315-20.
17. Ayhan S, Tuncer S, Demir Y, Kandal S. Thoracodorsal artery perforator flap: A versatile alternative for various soft tissue defects. *J Reconstr Microsurg* 2008;24:285-93.
18. Asuku ME, Ibrahim A, Ijekeye F. Post-burn axillary contractures in pediatric patients: A retrospective survey of management and outcome. *Burns* 2008;34:1190-5.
19. Er E, Ucar C. Reconstruction of axillary contractures with thoracodorsal perforator island flap. *Burns* 2005;31:726-30.
20. Yazar S, Lin CH, Lin YT, Ulusal AE, Wei FC. Outcome comparison between free muscle and free fasciocutaneous flaps for reconstruction of distal third and ankle traumatic open tibial fractures. *Plast Reconstr Surg* 2006;117:2468-75.
21. Karsıdag S, Akçal A, Turgut G, Uğurlu K, Baş L. Lower extremity soft tissue reconstruction with free flap based on subscapular artery. *Acta Orthop Traumatol Turc* 2011;45:100-8.
22. Serletti JM, Moran SL. Soft tissue coverage options for dorsal foot wounds. *Foot Ankle Clin* 2001;6:839-51.
23. Uygur F, Sever C, Kulahci Y, Gideroğlu K. Reconstruction of postburn inguinal contractures using the pedicled anterolateral thigh flap. *Burns* 2009;35:e3-7.
24. Nasir S, Aydin MA. Reconstruction of soft tissue defect of lower extremity with free SCIA/SIEA flap. *Ann Plast Surg* 2008;61:622-6.
25. Engel H, Gazyakan E, Cheng MH, Piel D, Germann G, Giessler G. Customized reconstruction with the free anterolateral thigh perforator flap. *Microsurgery* 2008;28:489-94.
26. Ulusal BG, Lin YT, Ulusal AE, Lin CH, Yen JT. Reconstruction of foot defects with free lateral arm fasciocutaneous flaps: Analysis of fifty patients. *Microsurgery* 2005;25:581-8.
27. Maruyama Y. Ascending scapular flap and its use for the treatment of axillary burn scar contracture. *Br J Plast Surg* 1991;44:97-101.
28. Kim SE, Rhyou IH, Suh BG, Chung KC. Use of thoracodorsal artery perforator flap for soft tissue reconstruction in children. *Ann Plast Surg* 2006;56:451-4.
29. Munhoz AM, Montag E, Arruda EG, Aldrighi C, Gemperli R, Aldrighi JM, *et al.* The role of the lateral thoracodorsal fasciocutaneous flap in immediate conservative breast surgery reconstruction. *Plast Reconstr Surg* 2006;117:1699-710.
30. Sever C, Bayram Y, Sahin C. Thoracodorsal artery perforator flap: Basic surgical determinants. *Arch Clin Exp Surg* 2012. doi: 10.5455/aces.20120506072849.

**How to cite this article:** Sever C, Uygur F, Kulahci Y, Karagoz H, Sahin C. Thoracodorsal artery perforator fasciocutaneous flap: A versatile alternative for coverage of various soft tissue defects. *Indian J Plast Surg* 2012;45:478-84.

**Source of Support:** Nil, **Conflict of Interest:** None declared.