

## Original Article

# Isolated cleft of the ala nasi: A report of seven cases

J. Rajesh Jinka, Harikiran Chekuri, Gopalakrishna Annavarapu

Department of Plastic Surgery, Deccan College of Medical Sciences and Allied Hospitals, Hyderabad, India

**Address for correspondence:** Dr. Gopalakrishna Annavarapu, Department of Plastic Surgery, Deccan College of Medical Sciences, D.M.R.L.X. Road Kanchanbagh, Hyderabad - 500 058, India. E-mail: agkga@rediffmail.com

### ABSTRACT

Craniofacial clefts other than cleft lip & palate are reported to be 1.4 to 4.9 per 100,000 live births. Of these, clefts of nose are usually associated with other clefts. Isolated cleft of Ala is rare, 0.7% of all clefts reported by Monasterio. In an analysis of photographic records of 3,500 consecutive patients with craniofacial clefts including cleft lip & palate registered with us between 1985- 2012 which were accessed through our data base, 13 patients with nasal clefts were identified, seven out of which had Isolated cleft of the Ala. All were treated by a rotation flap of the Ala with good results with the longest follow up of 14Yrs. The authors have emphasised the rarity of the condition and presented a simple surgical procedure for correction. In the opinion of the authors this very simple procedure which can be performed by the junior surgeon gives a good long term result in the management of cleft Ala.

### KEY WORDS

Cleft of ala; cleft of nose; coloboma of ala; Tessier 1 and 2 clefts

### INTRODUCTION

The nose being the most prominent feature on the face, any asymmetry or irregularity in the nasal contour assumes a great significance.

Incidence of craniofacial clefts other than cleft lip and palate is reported to be 1.4-4.9 per 100,000 live births. Of these, cleft of the nose is rare. In Tessier's classification<sup>[1]</sup> of craniofacial clefts using the orbit in key position, cleft nos 1 and 2 are paramedian clefts involving the nose. These can have a range of severity from notching of ala to complete absence of the nasal bones. This condition is often seen in association with other craniofacial deformities such as

orbital hypertelorism, broadening of nasal root, midline cleft (Tessier 0), median cleft face syndrome, etc.

Newman and Bird<sup>[2]</sup> observed that isolated notching and clefts of the ala nasi involving only the portion of the lateral nasal wall inferior and lateral to the nasal bone have an embryological significance separate from other craniofacial deformities. These isolated clefts of the ala have been called colobomas, alar clefts, alar rim clefts, etc., by different authors and are rare.

Losee *et al.*<sup>[3]</sup> worked up a classification scheme of congenital nasal anomalies based upon a series of 261 patients, and they reported nasal clefts in 16% of all nasal anomalies.

Monasterio *et al.*<sup>[4]</sup> analysed a series of 6500 patients and found that only 2.2% of all clefts are those of Tessier types 0, 1, 2 and 3, i.e., clefts involving the nose. They also reported that isolated nasal clefts make only 0.7% of all craniofacial clefts.

#### Access this article online

Quick Response Code:



Website:

www.ijps.org

DOI:

10.4103/0970-0358.105962

In a retrospective study of the photographs of 3500 patients with clefts seen in our centre, we could identify 13 patients having a cleft involving the nose. Out of these, seven patients had isolated cleft of the nose. This paper presents our results in these seven patients.

**MATERIALS AND METHODS**

Thirteen patients having cleft involving the nose were identified in our centre over the last 27 years out of a total of 3500 consecutive patients having various clefts including cleft lip and palate. This was done by studying the photographic records existing in the department.

Of these 13 patients, 6 had associated craniofacial anomalies, whereas 7 were isolated clefts of the ala.

Out of the six patients having associated anomalies, one had notching of both alae with a Tessier cleft 0, one patient had unilateral notching with hypertelorism, one had unilateral notching with absence of columella (one of a set of twins) [Figure 1], two had unilateral notching with Tessier 3 and one had a cleft extending through nasal bones.

One of the seven patients who had an isolated cleft of the ala is a twin of the patient with absence of columella and unilateral cleft ala.

We are presenting here our series of seven patients with isolated unilateral alar cleft.

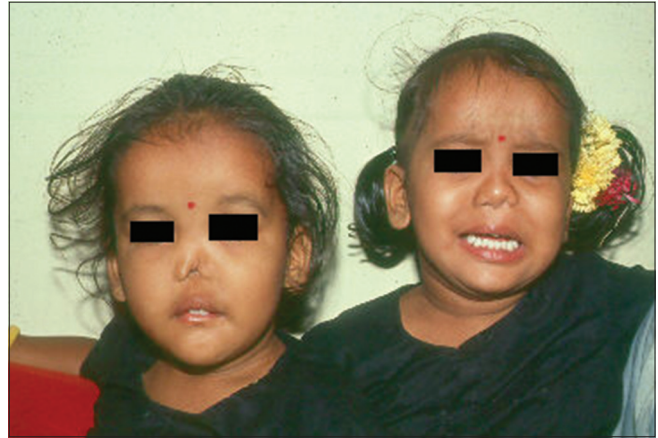All these patients were treated by the same technique of rotation of full thickness of ala. The details of the patients are given in Table 1.

**Table 1: Details of patients with cleft nose as per our photographic database**


Name	Age	Sex	Diagnosis
S1	18 years	F	Right cleft ala
S2	20 years	F	Left cleft ala
P	18 years	M	Left cleft ala
SY	26 years	M	Left cleft ala
H	28 years	F	Right cleft ala
SMA	13 years	M	Left cleft ala
L	35 years	F	Right cleft ala with Tessier cleft 3
R	3 years	M	Bilateral cleft ala with Tessier cleft 0
Twin a	5 years	F	Left cleft ala
Twin b	5 years	F	Left cleft ala with absence of columella
B	32 years	F	Right cleft ala with Tessier cleft 3
KK	1 year	M	Right cleft I with hypertelorism
A	6 months	M	Left cleft I with involvement of nasal skeleton

**Surgical procedure**

A posteriorly based rotation flap of full thickness of ala was marked so as to mimic the alar crease. The ala was incised through and through with a no.11 blade [Figures 2 and 3].



**Figure 1:** Twin sisters with cleft ala. The one on the left has absence of columella as well



**Figure 2:** Incision



**Figure 3:** Closure

This full-thickness flap of ala was rotated down and medially to meet the anterior edge of the defect, where a small “Z” plasty was incorporated in order to avoid a notch.

## RESULTS

Six of the seven patients thus treated had uneventful primary healing with no notching. In one patient, there was a mild wound dehiscence [Figure 4] which healed uneventfully with conservative management.

The shortest follow-up is 1 year [Figure 5a and b] and the longest follow-up is 14 years [Figure 6a-d], with no significant complaints from the patients regarding the shape of the nostril and the scar. However, worm’s eye view does show a discrepancy between the two nostrils in all the patients immediately postoperative and this has persisted throughout the follow-up period, though none of the patients complained about it specifically, probably because in normal day-to-day life this view is not presented to an observer [Figure 7a and b].

## DISCUSSION

Cleft or coloboma of the ala may appear to be a relatively minor defect, but because of its location, it assumes significance.

It has been differently named by different authors (Tessier cleft no. 1, facial cleft no. 1, nasal cleft, coloboma of nose, cleft ala, etc.).

Agrawal<sup>[5]</sup> presented a series of four cases of cleft ala where there was additional tissue adjacent to the cleft. In our series of seven cases, we have not encountered this phenomenon.

Monasterio has reported 10 cases of cleft ala in a series of 6500 clefts, 4 unilateral and 6 bilateral. In our series of 3500 clefts, we have seen 13 cases of which 7 were isolated clefts of the ala, which were all unilateral.

Reconstruction of the cleft should address repair of the cleft proper and augmentation of the cartilage. Most

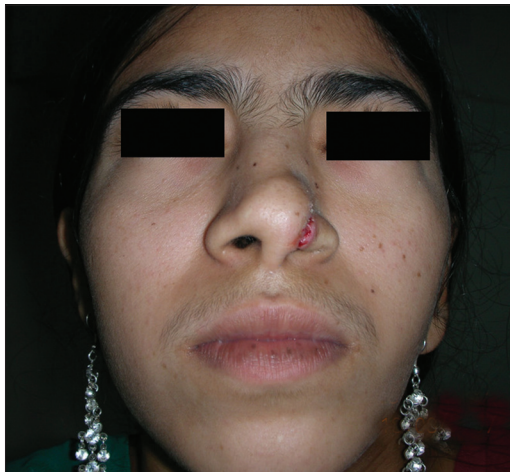

Figure 4: Patient no. 2: Wound dehiscence

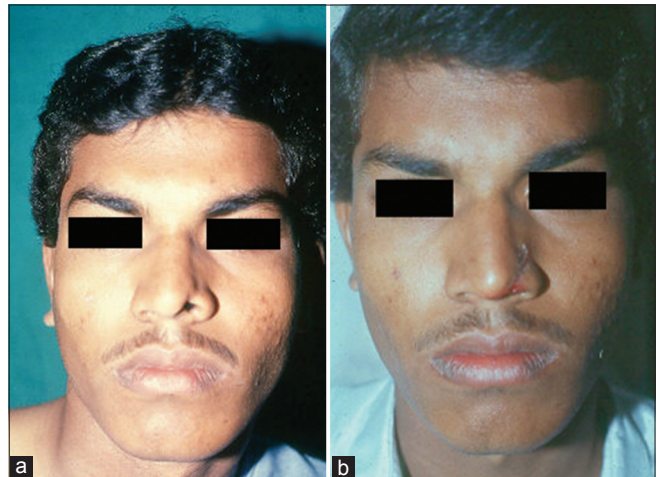

Figure 5: Patient no. 4: (a) pre-op. (b) post-op

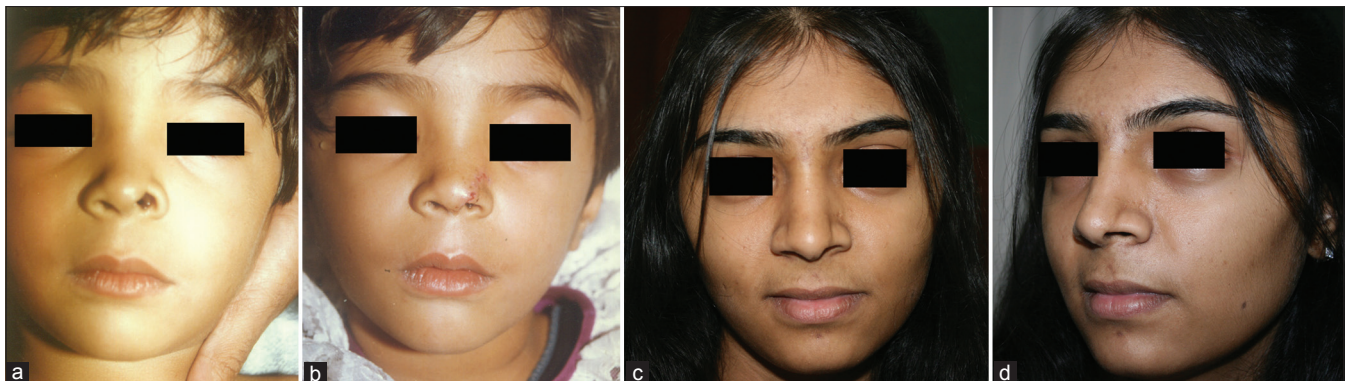

Figure 6: Patient no 3: (a) pre-op. (b) immediate post-op. (c) 14 years post-op. (d) three-fourth profile 14 years post-op

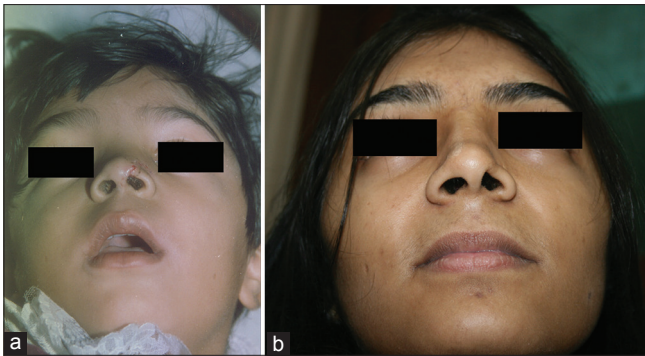


Figure 7: (a) Asymmetry of the nostrils immediate pre-op. (b) asymmetry persisting

authors have used local tissue to correct the defect. Novacovic<sup>[6]</sup> has used the Denonvillier technique in two cases of adults with alar notching. Some authors have used composite grafts in addition of local tissue.

In our series, we have used only local tissue. All the patients were treated by the same technique of a posteriorly based full-thickness flap of the ala rotated into the defect and a Z plasty. Six of the seven patients healed without incident. One had a minor wound dehiscence which was managed conservatively. However, a slight difference has remained in the shape of the two nostrils in all the patients because the cartilage deficiency was not addressed primarily.

In a follow-up of up to 14 years, there has been no complaint from the patients regarding the discrepancy in the two nostrils. This could be corrected with a cartilage graft, but none of our patients opted for it.

## CONCLUSION

In a series of about 3500 patients of clefts, we have come across 13 patients with clefts involving the nose. Of these, seven patients had isolated unilateral cleft of the ala nasi. All the clefts were closed using a posteriorly based rotation flap of full thickness of the ala with acceptable results. The deficiency of the alar cartilage was not corrected primarily and none of the patients opted for cartilage graft for the correction of the asymmetry of the nostrils which was seen only in the worm's eye view. The longest follow-up was 14 years.

## REFERENCES

1. Tessier P. Anatomical classification facial, craniofacial and latero-facial clefts. *J Maxillofac Surg* 1976;4:69-92.
2. Newman MH, Burdi AR. Congenital alar field defects: Clinical and embryological observations. *Cleft Palate J* 1981;18:188-92.
3. Losee JE, Kirschner RE, Whitaker LA, Bartlett SP. Congenital nasal anomalies: A classification scheme. *Plast Reconstr Surg* 2004;113:676-89.
4. Ortiz Monasterio F, Fuentedel Campo A, Dimopoulos A. Nasal clefts. *Ann Plast Surg* 1987;18:377-97.
5. Agrawal K, Panda KN, Prasad S. Isolated tesser no. 1 cleft the nose. *Ann Plast Surg* 1998;41:311-3.
6. Novacovic M, Baralic I, Stepic N, Rajovic M, Stojiljkovic V. Denonvilliers' advancement flap in congenital alar rim defects correction. *Vojnosanit Pregl* 2009;66:403-6.

**How to cite this article:** Jinka JR, Chekuri H, Annavarapu G. Isolated cleft of the ala nasi: A report of seven cases. *Indian J Plast Surg* 2012;45:512-5.

**Source of Support:** Nil, **Conflict of Interest:** None declared.

### Announcement

#### iPhone App



Download  
iPhone, iPad  
application

FREE

A free application to browse and search the journal's content is now available for iPhone/iPad. The application provides "Table of Contents" of the latest issues, which are stored on the device for future offline browsing. Internet connection is required to access the back issues and search facility. The application is Compatible with iPhone, iPod touch, and iPad and Requires iOS 3.1 or later. The application can be downloaded from <http://itunes.apple.com/us/app/medknow-journals/id458064375?ls=1&mt=8>. For suggestions and comments do write back to us.