

Case Report

Congenital fusion of jaw and ankyloblepharon filiforme adnatum: Malformation and multiple systems anomaly

Mallika P Reddy¹, Raghu SR

Departments of Pediatric Surgery, Bangalore Medical College and Research Institute, ¹Oral and Maxillofacial Surgery, K G F College of Dental Sciences, Bangalore, Karnataka, India

Address for correspondence: Dr. Mallika P Reddy, UAS Layout 1st main 5th cross, Bangalore, Karnataka, India.
E-mail: mallikapreddy@gmail.com

ABSTRACT

Congenital fusion of jaw and its association with ankyloblepharon filiforme adnatum is reported but is a quite rare congenital benign anomaly. It may be unilateral or bilateral and can present with a single system or multiple systems involvement. This report concentrates on describing the clinical features of above disease, likely aetiological causes, and embryogenesis with classification, diagnostic, and, treatment modality, anesthesia problems and review of literature.

KEY WORDS

Ankyloblepharon; congenital fusion; malformation; mandible, maxilla

INTRODUCTION

Maxillomandibular fusion can involve only the oral soft tissues or both hard and soft tissues. It may present with aerodigestive problems and facial growth deformities from temporomandibular joint ankylosis at later stage.^[1] Congenital fusion of the maxilla and mandible mostly appears in association with other anatomic oral and maxillofacial anomalies such as cleft lip, cleft palate, aglossia, bifid tongue, ankyloblepharon, aglossia-adactylia syndrome and other oral soft tissue synechiae.^[1-3]

Josef von Hasner (1881) described ankyloblepharon filiforme a dnatum (AFA).^[4] Grace E. Parkins reported the 27th case of congenital fusion of jaw (2009)^[5] after initial

reports of Burket (1936). They were usually associated with cleft palate or systemic anomalies.^[6,7]

We are reporting neonate with the rare case of extensive intra-oral fibrinous congenital synechiae involving both jaws almost completely with extension to buccal mucosa, and its association with AFA without systemic and other orofacial anomalies.

CASE REPORT

A 3-week-old boy weighing 2 kg, presented with inability to open mouth, difficulty in feeding, and failure to thrive. Antenatal and family history was normal. Contrast enhanced computerized tomography had revealed near complete fusion of jaws with normal palate [Figure 1]. Neonate was not fit for any anaesthesia. He was examined in operational theatre and was found to have complete fibrinous fusion of both jaws except 3 mm slit opening at canine region and obliteration of gingivobuccal sulcus posteriorly [Figure 2]. They were released with bipolar cautery after spraying the local anaesthesia. He also had right partial lateral ankyloblepharon and was released with blunt

Access this article online

Quick Response Code:



Website:

www.ijps.org

DOI:

10.4103/0970-0358.105977

dissection [Figure 3]. Manual manipulation gradually increases inter- alveolar opening to 20 mm [Figure 2]. Genetic work up and ophthalmic examination were normal. Post-operatively, mother was able to feed the baby well [Figure 4].

DISCUSSION

Incidence of neonatal congenital birth defects is 2.5%. Congenital fusion defects of the maxilla and mandible including other anatomic oral facial abnormalities are usually rare sporadic event.^[3] Congenital Synechia can involve any part of oral cavity. It commonly occurs either between alveolar ridges of both jaws or between tongue and palate.^[1,3] These adhesion bands consist of variable amount of epithelium, connective tissue, muscle, and bone.^[3]

Fascial development depends on proper coordinations of neural crests cells, all three germal layers of first arch components, fibroblast growth factors, bone morphogenetic proteins, and epithelial-mesenchymal interactions.^[8-10] The cause of congenital synechia may be due to persistence of the buccopharyngeal membrane, ectopic membrane, failure

of tongue to protrude out around 7-8 week, hereditary, amniotic constriction bands in the region of the developing branchial arches, environmental insults, trauma, drugs such as meclozine and large doses of vitamin A.^[1,3,5,9]

Craniofacial abnormalities represent a deficiency, excess or absence of an embryonic developmental field.^[10] Midline and paramedian clefts are commonly associated with oral synechia. They may be due to invisible or dwarf/dysfunctional family of neuromeric organization such as basal prosomeres5, r0, r1-3, 8-11 rhombomeres neuromeres.^[10]

AFA is a partial or complete adhesion of the ciliary edges of the upper and lower eyelids with fine extensile band tissue. It causes the reduction of palpebral fissure with limited movements of the lids.^[4] Bands are single or multiple, lateral, central and rarely nasal.^[4] Histologically, the bands consist of purely highly cellular vascular connective tissue and squamous epithelium.^[4]

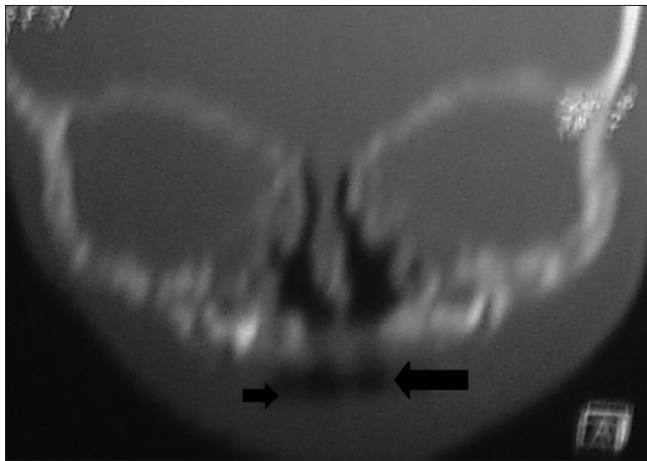


Figure 1: Plain CT scan revealed microsomia and synechia (Arrow)

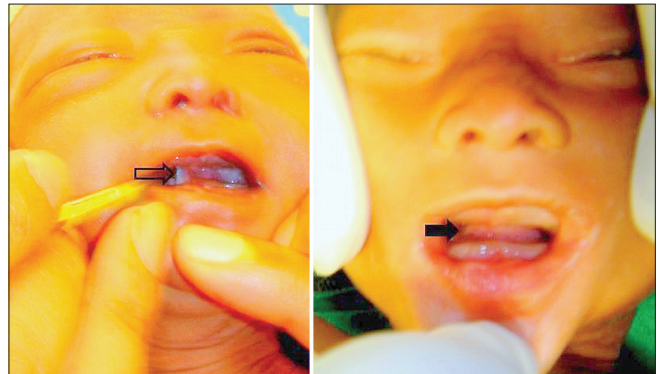


Figure 2: Preoperative and post operative picture showing complete congenital fusion of jaws except slit like opening at right canine region (Hollow arrow) and wide opened inter alveolar margin (Bold arrow)

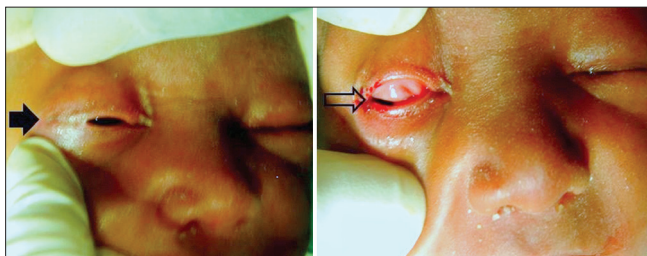


Figure 3: Pre and post-operative photograph showing right incomplete ankyloblepharon filiforme adnatum

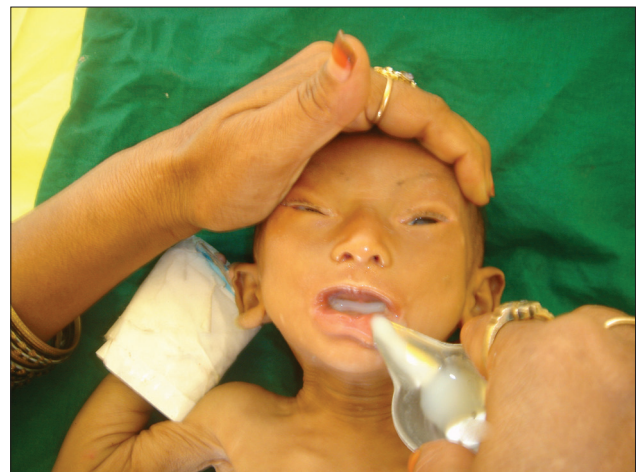

Figure 4: Post-operative picture with mother feeding baby well

Normally the eyelids remain fused until the fifth month of gestation.^[6,7] Developmental abnormal mesodermal overgrowth or temporary epithelial arrest causes eye-lid adhesions and is associated with 7 to 15 weeks intrauterine anomalies.^[4,6,7] AFA may be isolated or is part of multisystem involvement.^[6,7]

Dawson, *et al.*, Laster, *et al.*, and Daniels had proposed varied classifications of intra-oral fusion depending on site, extent, type of fusion (bony/fibrous), and associated anomalies.^[5] Congenital fusion of jaw can also be classified based on their severity, pathogenetic mechanism, or whether they involve a single system or multiple systems.^[11] Congenital synieche of jaws can be either disruption or malformation anomaly.^[6,11] Extensive intra-oral-synechia is major anomaly and usually has multi system involvement such as association or syndromic^[1-3,9,11], but our neonate had only AFA. Our neonate is classified as major and malformation of orofacial congenital birth defect. Mendelian Inheritance in Man (online reference), London dysmorphology, and POSSUM databases search reveals that congenital oral synechia and AFA usually have multisystem involvement such as ectrodactyly ectodermal dysplasia clefting syndrome/Hay-Wells syndrome.

Simple surgical adhesiolysis under local anesthesia would be sufficient to allow normal feeding and prevent upper airway obstruction.^[5,9] Timely separations of the eyelids are crucial to avoid the development of occlusion amblyopia. Air way, feeding management, and physiotherapy issues should be addressed properly.^[2]

CONCLUSION

Maxillomandibular fusion with AFA is quite rarely reported.

They are congenital disorder of malformation and major anomaly of birth defects. The aetiology is still obscure and speculative. Transoral release of extensive intra-oral synechia under local anesthesia is a simplest way of treating this rare condition.

REFERENCES

1. Mortazavi SH, Motamedi MH. Congenital fusion of the jaws. *Indian J Pediatr* 2007;74:416-8.
2. Mir MA, Iqbal S, Hafeez A, Zargar HR, Rasool A, Mohsin M, *et al.* Syngnathia without any other associated anomaly-A very rare case report. *Internet J Plast Surg* 2007;4:1.
3. Tanrikulu R, Erol B, Görgün B, İlhan O. Congenital alveolar synechia-A case report. *Br Dent J* 2005 22;198:81-2.
4. Gupta SP, Saxena RC. Ankyloblepharon filiforme adnatum. *J All India Ophthalmol Soc* 1962;10:19-1.
5. Parkins GE, Boamah MO. Congenital maxillomandibular syngnathia: Case report. *J Craniomaxillofac Surg* 2009;37:276-8.
6. Dollfus H, Verloes A. Dysmorphology and the orbital region: A practical clinical approach. *Surv Ophthalmol* 2004;49:547-1.
7. Sharkey D, Marlow N, Stokes J. Ankyloblepharon filiforme adnatum. *J Pediatr* 2008;152:594.
8. Francis-West P, Ladher R, Barlow A, Graveson A. Signalling interactions during facial development. *Mech Dev* 1998;75:3-8.
9. Shams MG, Motamedi MH, Abad HL. Congenital fusion of the maxilla and mandible: Brief case report. *Oral Surg Oral Med Oral Pathol Oral Radiol Endod* 2006;102:e1-3.
10. Ember EL, Carstens MH. Neuroembryology and functional anatomy of craniofacial clefts. *Indian J Plast Surg* 2009; 42: S19-S34.
11. Tanteles GA, Suri M. Classification and aetiology of birth defects. *Paediatrics and Child Health* 2007;17:233-3.

How to cite this article: Reddy MP, Raghu SR. Congenital fusion of jaw and ankyloblepharon filiforme adnatum: Malformation and multiple systems anomaly. *Indian J Plast Surg* 2012;45:557-9.

Source of Support: Nil, **Conflict of Interest:** None declared.