

Mandibular distraction in a 75-day-old child with severe Pierre Robin sequence

Sir,

Management of respiratory distress associated with severe form of Pierre Robin sequence is challenging and involves medical and surgical interventions.^[1] Though tongue lip adhesion procedure was common, the advent of distraction osteogenesis has improved outcomes.^{[2][3]} We were referred a child with such severe form of Pierre Robin sequence associated with inability to lie supine [Figure 1]. The child was always being nursed prone and had three episodes of respiratory distress needing ventilator support within the first 2 months of birth. An attempt to manage

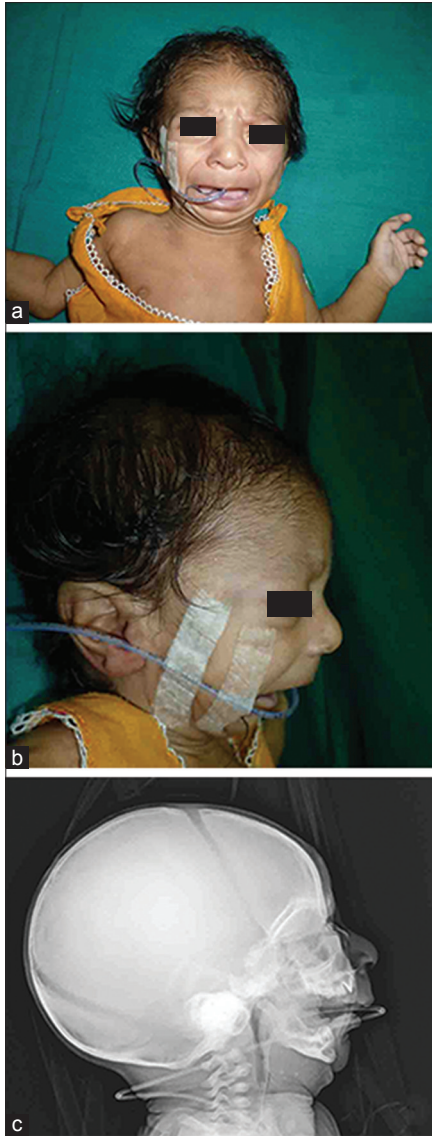

Figure 1: Preoperative photographs of the child: (a) frontal view; (b) lateral view; (c) radiograph showing reduced airway space behind the tongue

the child with tongue lip adhesion was unsuccessful. Hence, it was planned to do distraction of the mandible (at 75 days of age). However, we had difficulty in sourcing a paediatric distractor as even the standard companies had to get it from abroad, which would take some time. In this situation, we had to intervene right away, and hence, we used an adult distractor in a modified way successfully to help distract the paediatric mandible.

Under general anaesthesia and after tracheostomy, the angle of the mandible was exposed through a submandibular approach [Figure 2]. An oblique osteotomy was made at the angle of mandible and a 25-mm intraoral adult external fixation device (Mandibular Distractor,

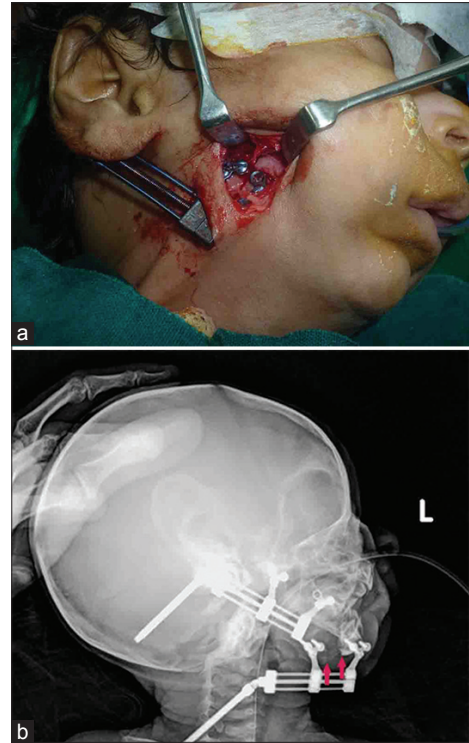


Figure 2: (a) Intraoperative photographs showing fixation of the distraction device onto the mandible; (b) radiograph during course of distraction with the red arrows demonstrating the bone margins, with new bone formation in the intervening space

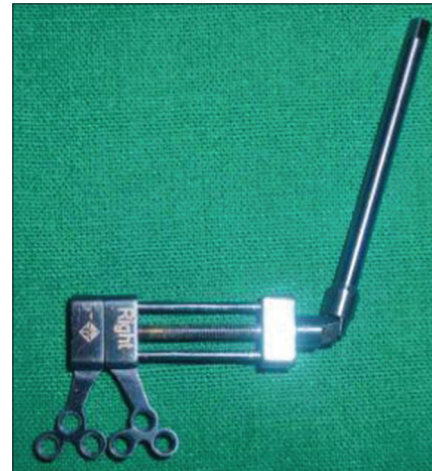


Figure 3: The mandibular distractor used (Mandibular Distractor, Trimos Sharma, Mumbai, India)

Trimos-Sharma, Mumbai, India) [Figure 3] was inverted and attached to allow distraction. The distractor was fixed bilaterally. The distractor was inserted through a different incision with leeway to allow for movement of the distractor arms without stretching the skin. It was activated from the day after surgery at a rate of one turn every 8 h, or 3 turns per day,^[4] which corresponds to a lengthening of 1.5 mm/day. A nasogastric tube was secured to facilitate

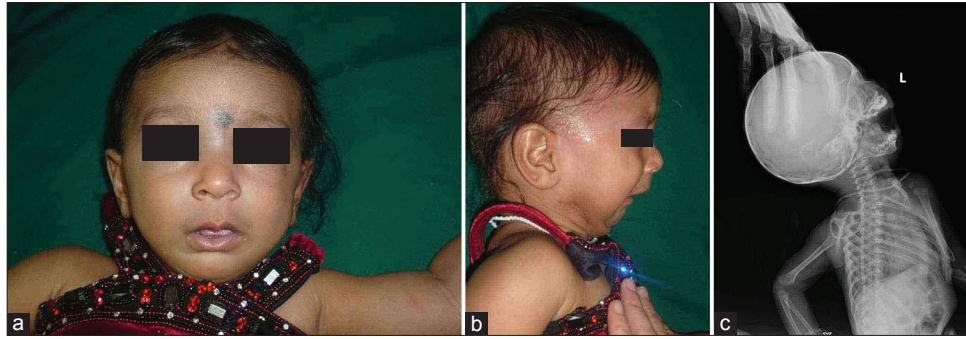


Figure 4: Postoperative images showing the frontal, profile views and the lateral skull radiograph

feeding. By the fourth day, the child was comfortable lying supine and breathing spontaneously, even on blocking the tracheostomy tube. The tracheostomy tube was removed on the fifth day. On the eighth day, the distraction device felt very tight and the child was obviously uncomfortable. So, distraction was stopped. The child was converted onto oral feeds shortly after. The external fixator was left *in situ* to allow consolidation of the osteotomy for 7 weeks. The child progressed well with good weight gain, from 3.1 kg at the beginning of distraction to 4.8 kg after 7 weeks, when the device was removed. Healing was uneventful and the mandibular position has been maintained [Figure 4]. The child has suffered no further respiratory distress.

Though distraction is an accepted method of treatment for such cases, paediatric distractors are not readily available and are prohibitively expensive. We have described a method of distracting the paediatric mandible by using an intraoral adult distractor extraorally with successful outcome.

**Kannan Balaraman,
R. Raja Shanmugakrishnan,
R. Ravindra Bharathi, S. Raja Sabapathy**

Department of Plastic, Hand and Reconstructive
Microsurgery and Burns, Ganga Hospital, Coimbatore,
Tamil Nadu, India

Address for correspondence:

Dr. S. Raja Sabapathy,
Department of Plastic, Hand and Reconstructive
Microsurgery and Burns, Ganga Hospital, 313, Mettupalayam Road,
Coimbatore, Tamil Nadu - 641 043, India.
E-mail: rajahand@vsnl.com

REFERENCES

1. Evans AK, Rahbar R, Rogers GF, Mulliken JB, Volk MS. Robin sequence: A retrospective review of 115 patients. *J Paediatr Otorhinol* 2006; 70: 973-980.

2. Denny AD, Talisman R, Hanson PR, Recinos RF. Mandibular distraction osteogenesis in very young patients to correct airway obstruction. *Plast Reconstr Surg* 2001;108:302-11.
3. Witterborn W, Panchal J, Marsh J, Sekar KC, Gurley J. Neonatal distraction surgery for micrognathia reduces obstructive sleep apnea and the need for tracheotomy. *J Craniofac Surg* 2004;15:623-30.
4. Dauria D, Marsh JL. Mandibular distraction osteogenesis for Pierre Robin sequence: What percentage of neonates need it?. *J Craniofac Surg* 2008;19:1237-43.

Access this article online	
Quick Response Code: 	Website: www.ijps.org
	DOI: 10.4103/0970-0358.113743