

woman to the plastic surgeon. More than the split lobule it is the repair that is a cause concern for the women as it restrains them from wearing ear ornament for a considerable period of time post-repair.

The conventional method was to use a thin wire of gold or silver which was heated and was passed through the ear lobule. The same wire was either left in place or immediately replaced by a wire of similar caliber which was left in place till the newly created hole epithelialized. This was followed by the piercing gun which was used with the same principle but was more rapid and relatively less painful. All these techniques were fraught with the problems of infection Also absence of anesthesia usually makes the whole experience a difficult one for the person. This new technique described by us has in its roots the need for giving the patients of repaired split ear lobule a new hole and enable them to be able to wear an ornament instantly It was then realized that the same can be extrapolated to the children and persons undergoing ear piercing for the first time.

Local anesthetic ointment (a mixture of lignocine and prilocaine) was applied on the desired ear an hour before the procedure as a thick layer and was reinforced at 30 mins. For piercing, a site lateral to the scar was chosen aligning it with the hole of the opposite lobule as far as possible in case of unilateral split ear and marking the two holes at the same level in case of bilateral split lobule repair. Patients were asked to bring an ornament of her choice preferably with a long stem. An 18-G intravenous cannula was used for piercing [Figure 1a]. The cannula was passed through the lobule at the selected site. The direction of this movement was always posterior to anterior or medial to lateral in order to allow the sleeve hole to face anteriorly. The stellate was then withdrawn leaving the sleeve in place. The stem of the ornament

A novel technique for piercing of ear lobule suited to Indian subcontinent

Sir,

Split ear lobule is a problem encountered by many Indian women because of wearing heavy ear ornaments for long durations. This problem usually brings the

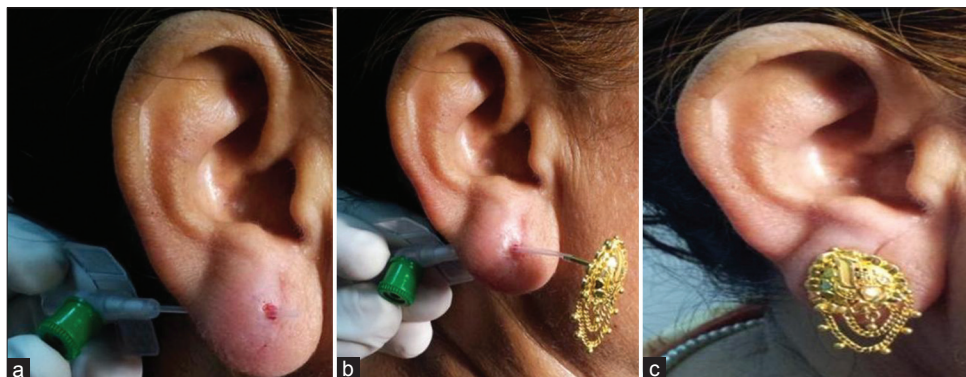


Figure 1: (a) Pierced ear lobule with an 18-F cannula after withdrawal of stellate. (b) Ornament threaded into the cannula sleeve. (c) Ornament in place

was then passed in the lumen of the sleeve [Figure 1b]. The sleeve was gradually withdrawn making sure that the stem of the ornament is not dislodged from the lumen of the sleeve. The stem was gently guided across the newly created hole and anchored in place using a screw [Figure 1c]. Any bleeding from the newly created hole was stopped by compressing the lobule for few minutes. Once the ornament was anchored the patient was advised not to change the ornament for a period of three weeks and apply a local antibiotic ointment for 3-5 days. The described technique is an innovation suited to the traditions of a country where ear ornaments assume a very significant religious, cultural, and social importance. The patient in this case is able to wear an ornament of her choice instantly which has not been achieved by any of the previous methods described in the literature.^[1] When a lobuloplasty is done, the ear piercing is not done simultaneously. Instead we give a gap of minimum 3 weeks before the ears are pierced and it is in that very instant that the ornament which the patient prefers is inserted by this technique in a single stage. What was done earlier was that after piercing the ears with a gold or stainless steel wire, the wire was replaced with the actual ornament only after a gap of at least 2 weeks ensuring that the tract had epithelialized.

The ornaments chosen are in most cases made of gold which is an inert metal and thus reduces the risk of foreign body reaction and inflammation. As the lady is content with having an ornament in her ear, she is in no hurry to replace it with something more suitable and hence the same is safely left in place for 3 weeks or more giving the tract enough time to epithelize. This technique offers a combination of sound surgical principles and aesthetic and cultural considerations which are the true embodiment of plastic surgery.

**Vinay Kumar Tiwari, Anshumali Misra,
Sujata Sarabahi**

Department of Burns, Plastic and Maxillofacial Surgery,
Virtual Memory-Mapped Communication and Safdarjang
Hospital, New Delhi, India

Address for correspondence:

Dr. Sujata Sarabahi, B-18, First Floor, Kailash Colony, New Delhi,
India. E-mail: ssarabahi@yahoo.co.in

REFERENCE

1. Kale SM, Patil SB, Jaiswal S, Khare N. A novel technique of piercing ears. *Indian J Plast Surg* 2010;43:230.

Access this article online	
Quick Response Code: 	Website: www.ijps.org
	DOI: 10.4103/0970-0358.113747