

Original Article

Osteomas of the craniofacial region: A case series and review of literature

Sagar Gundewar, Deepak S. Kothari¹, Nitin J. Mokal, Amol Ghalme¹

Department of Plastic Surgery, G.T Hospital, ¹J. J. Hospital, Mumbai, India

Address for correspondence: Dr. Deepak S. Kothari, Department of Plastic Surgery, Balaram building, J. J. Hospital, Mumbai, India. E-mail: drdeepak15@gmail.com

ABSTRACT

Objective: To discuss the clinical presentation, diagnosis and management of osteomas involving the craniomaxillofacial region. **Materials and Methods:** This study was conducted from June 2004 to March 2012 at our institute. A total of 12 cases between the ages of 10 and 50 years were managed with surgical excision and reconstruction. The criteria used to diagnose osteoma included radiographic and clinical features and histological confirmation of the specimen. The total follow-up period ranged from 6 to 24 months. **Results:** Out of 12 osteomas, 10 were peripheral and 2 were centrally located. Mandible involvement was seen in six patients, four involved the orbit, one the frontal bone and one the frontal bone with the skull base. All patients undergoing excision and reconstruction had a favourable aesthetic and functional outcome. There were no recurrences and no post-operative complications. **Conclusion:** Osteomas affect all age groups with no sex predilection and are usually clinically asymptomatic till they become large in size. Surgical excision and appropriate reconstruction is the mainstay of management. Surgery is indicated when lesion is symptomatic or actively growing and the surgical approach for exposure of the lesion should be case specific.

KEY WORDS

Craniofacial; osteoma; reconstruction

INTRODUCTION

An osteoma is a benign neoplasm in which deposition of compact lamellar cortical or cancellous bone creates a tumour mass^[1,2] The majority of cases occur in the craniofacial skeleton, most frequently in the paranasal sinuses and the jawbones, although rare cases in other bones and in soft tissues such as muscle have been documented.^[1] Two variants of osteoma are recognised which differ in the

origin in relation to the cortical plates: peripheral (periosteal) osteomas develop as masses attached to the cortical plates and central osteomas arise from the endosteal bone surfaces. In the facial bones, both central and peripheral osteomas have been described. Peripheral type of osteoma is the most common variant in the lower jaws, which occurs at the surface of the cortical bone and is sessile or pedicled. The pathogenesis of peripheral osteoma is unclear. Some investigators consider it as a true neoplasm, while others classify it as a developmental anomaly.^[3] These tumours are mostly asymptomatic; however they may present as a slow growing mass with pain over the region of the swelling. The association between maxillofacial osteomas, cutaneous sebaceous cysts, desmoids, multiple supernumerary teeth and colorectal polyposis is known as Gardner's syndrome.^[4]

The purpose of this study is to document the variable

Access this article online

Quick Response Code:



Website:

www.ijps.org

DOI:

10.4103/0970-0358.121982

clinical presentation, diagnosis and management of 12 cases of osteomas involving the craniomaxillofacial (CMF) region, to analyze the radiographic characteristics and discuss the features which distinguish these lesions from other similar lesions of the jaws along with a review of the literature.

MATERIALS AND METHODS

The study period is from January 2004 till 2012 and over this period a total number of 12 cases of osteoma were operated upon at our institute. The age group ranged from 10 years to 50 years. Out of these, 5 patients were males and 7 patients were females. The criteria used to diagnose osteoma included clinical and radiographic features with confirmation of diagnosis with histological analysis of the excised specimen. Most of the patients presented with complaints of pain in the region of the tumour of the mandible, and one of those with orbital involvement presented with unilateral proptosis.

Out of 12 cases, 6 (50%) involved some part of mandible [Table 1], 4 (33%) involved the orbit out of which 3 (25%) were present in the roof of the orbit with only one lesion involved the floor. Two tumours involved the frontal bone with only one involving the frontal bone and extended into the skull base. Of these, 10 of the tumours were peripheral and 2 were central osteomas.

Visible swelling was present in 6 of the patients but most of the patients (8 out of 12) came to us with the chief complaints of pain in the region of the lesion. Only one lesion was diagnosed incidentally on orthopantomogram (OPG) during time of planning for alveolar bone grafting. The one involving the roof and supraorbital region presented with vertical orbital dystopia and that involving the floor presented with proptosis. The field of vision and ocular movements were normal. One patient presented to us with trismus.

Pre-operative CT scan was done in 11 out of 12 patients and provisional diagnosis of osteoma was made. Out of these, 10 lesions were peripheral osteomas of which 7 presented as a pedunculated mass. Those involving the frontal bones (2) and the lingual surface of the mandible (1) presented as a diffuse mass. Diagnosis of central osteoma was made in two lesions with one involving the skull base and the other involving the body of mandible.

All patients underwent excision of the tumour of which two required reconstruction of the defect. Great importance was given to the surgical approach to the lesion using the most optimal incisions in order to minimise the cosmetic deformity. The orbital osteomas were approached transconjunctivally, the mandibular osteomas intraorally and the frontal osteomas through a bicoronal incision.

One of the patients presented with multiple swellings in the jaw with CT scan suggestive of multiple osteomas. On screening colonoscopy he had multiple polyposis but no abdominal complaints. The patient's father was also diagnosed with similar complaints. A diagnosis of Gardner's syndrome was made and the prominent osteomas were removed for cosmetic reasons.

All the excised specimens were sent for histopathological examination (HPE) and diagnosis of osteoma was confirmed for each of the lesions. On microscopic examination, six lesions were of compact type, three of spongy type and three were of mixed type on histology. Thus, the final diagnosis was made on the basis of both radiological and histopathological findings.

All the cases were operated with standard approaches as detailed in Table 1, giving emphasis to the cosmetic considerations since these are benign tumours. Complete excision of the lesions was done. Most of the patients were concerned with the post-operative scarring, so every attempt was made to use incisions which would conceal these scars. Since most of the lesions were pedunculated simple excision of the tumour was performed. The central tumours were excised along with the entire bone. Two patients underwent reconstruction: that of body of mandible with vascularised free fibula flap and the one with skull base involvement with split rib grafts and galeofrontalis flap.

Case no 1

This 14-year-old patient came for alveolar bone grafting after cleft lip and palate repair and was incidentally diagnosed osteoma with complete involvement of the left side of the body of the mandible on OPG [Figure 1a-d]. A confirmatory CT scan was done and it was suggestive of central osteoma with involvement of both the cortices. The patient underwent excision of the tumour along with removal of the entire body of the mandible followed by immediate reconstruction with a double-barrel free fibula flap [Figure 1e,f]. We have used a double-barrel free fibula

for the reconstruction and did the fixation with miniplates for the upper segment of the bone and the entire bone was supported with a 2.5 mm reconstruction plate. There were no post-operative complications and the flap survived very well. After 1 year she underwent cleft nasal rhinoplasty and 1 year later the reconstruction plate was removed for osseointegrated implant placement for dental rehabilitation [Figure 1g,h,i]. The patient has completed the treatment and is doing well with the implants.

Case no 2

A 26-year-old male presented with a right supraorbital swelling since 3 years [Figure 2a]. CT scan was suggestive

of a frontal bony swelling involving both tables and extending into the skull base [Figure 2b,c]. Complete excision was done through the bicoronal approach [Figure 2d] and reconstruction was done using rib grafts [Figure 2e]. The graft were harvested from ipsilateral 5th and 6th ribs and split into two. Around 10 cm long grafts were harvested. The grafts were fixed with titanium screws and were covered with a galeofrontalis flap. There was no recurrence within a follow up of 19 months as well as no resorption of the grafts on clinical assessment [Figure 2f].

Case no 3

A 29-year-old male patient came with 1 cm of mouth

Table 1: Summary of treated cases

S No.	Age (years)	Sex	Region of Involvement	Complaints	Approach	Treatment
1	37	F	Orbital floor	Proptosis	Transconjunctival	Excision
2	31	M	Roof of the orbit	Swelling and pain	Bicoronal	Excision and reconstruction with bone graft
3	33	F	Roof of the orbit	Swelling and pain	Bicoronal	Excision
4	16	M	Supraorbital Region and roof of orbit	Swelling and orbital dystopia	Bicoronal	Excision
5	29	M	Coronoid process mandible	Trismus	Intraoral	Excision
6	42	F	Ramus of mandible	Swelling and pain	Intraoral	Excision
7	21	F	Inferior alveolar nerve canal of mandible	Pain	Intraoral	Excision
8	16	F	Lingual surface of mandibular body	Pain and swelling	Intraoral	Excision
9	14	F	Whole body of mandible	Swelling	Intraoral and extraoral Risdon incision	Excision and Reconstruction with vascularised free fibula
10	30	M	Body of mandible	swelling	Intraoral	Excision
11	46	F	Frontal bone	Pain	Bicoronal	Excision
12	26	M	Frontal bone and skull base	Swelling and pain	Bicoronal	Excision

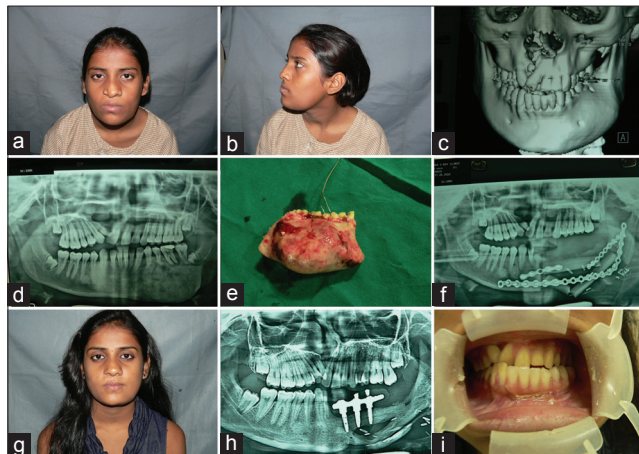


Figure 1: A case of central osteoma treated with complete excision and reconstruction with double barrel osteocutaneous fibula flap and complete dental rehabilitation

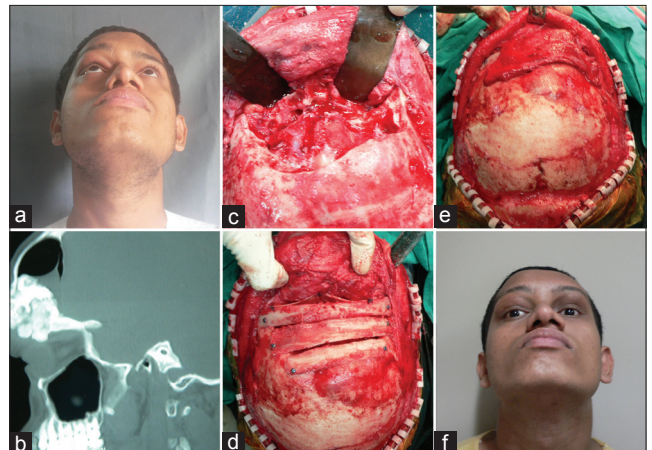


Figure 2: Frontal Osteoma treated with complete excision and reconstruction of the defect with rib grafts and galeofrontalis flap

opening and complaints of progressive increasing trismus since 1 year [Figure 3a]. There was no history of previous trauma. An x ray was done which was suggestive of a mass involving the left coronoid process [Figure 3b]. CT scan was confirmatory for osteoma [Figure 3c]. The mass was removed along with the coronoid process through an intraoral approach and was found to be pedunculated [Figure 3d,e]. Mouth opening improved significantly after removal of the tumour up to 3.5 cm [Figure 3f] and has remained the same for the follow-up period of 8 months.

Case no 4

This 30-year-old patient presented with a painless swelling over the left mandibular region [Figure 4a,b]. On examination, multiple swellings were palpable externally as well as intraorally. Colonoscopy was done and which showed multiple polyps but the patient was asymptomatic. Patient's father also had similar findings and a diagnosis of Gardner's syndrome was made. The most prominent osteomas were surgically excised by intraoral and submandibular incisions [Figure 4c-f] and the patient was advised regular follow up including repeat colonoscopies.

RESULTS

All 12 patients in our series had good functional and aesthetic outcomes.

There were no intra-operative or post-operative complications. All the patients were followed up at 1, 3, 6 and 12 months and yearly thereafter. The mean follow up period was 13 months with shortest follow up of 6 months and longest follow up of 24 months.

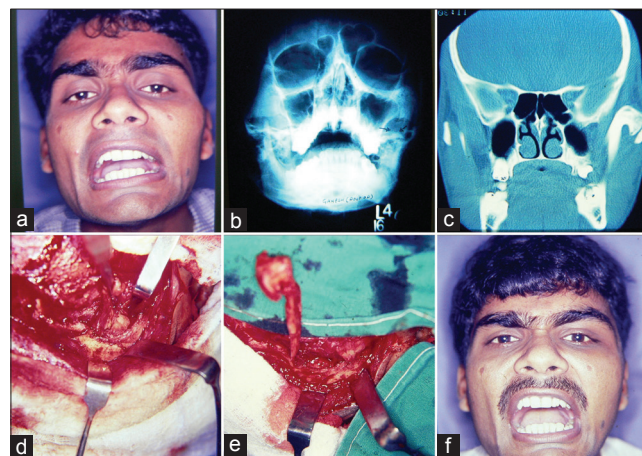


Figure 3: Coronoid osteoma with trismus. Treated with excision and complete mouth opening

All patients reported relief of pain and other symptoms in the post-operative period and there was no recurrence of the lesions in any of our cases. Since transconjunctival and intraoral approaches were used, there were no visible scars and all the five patients with bicoronal approach were satisfied with the aesthetically placed scars.

The outcome of patients who underwent reconstruction was also very pleasing both aesthetically and functionally. The one reconstructed with a free vascularised fibular graft has undergone removal of reconstruction plate for further dental rehabilitation with osseointegrated implants. Double barrel fibula was done purposely to maintain the mandibular height and patient is doing extremely well with the implants in place.

We did not encounter any resorption of the split rib grafts which we had used for skull base reconstruction in a 14 month follow up, probably due to the fact that we had provided a well-vascularised cover in the form of a galeofrontalis flap.

DISCUSSION

Osteomas of the facial bones are a rare entity and very few cases have been reported in the literature. In a study by Larrea *et al.*,^[5] 106 patients were diagnosed with 132 osteomas of the craniomaxillofacial region between 1986 and 2003. Those involving the orbit are even rarer.

An osteoma is a benign lesion characterised by the proliferation of compact or spongy bone. Various etiopathogenetic hypotheses have been proposed for osteoma formation. Some^[6-8] have hypothesised that the lesion is caused by congenital anomalies. Another

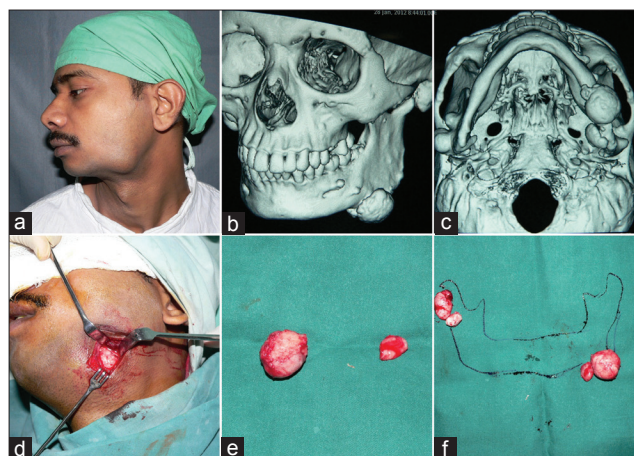


Figure 4: Case of Gardner Syndrome

proposal, which is no longer held, was that chronic inflammation caused neoplastic proliferation.^[9,10] The development of these formations may be a result of trauma or embryogenetic changes. In addition, others^[11] have hypothesised that muscular traction contributes to neoplastic changes in the bone. There is controversy whether osteoma represents true neoplasm, and not all lesions designated as an osteoma may represent a single entity. Some likely represent the end stage of an injury or inflammatory process or the end stage of a hamartomatous process such as fibrous dysplasia.

The lesion has three forms: central, peripheral or extraosseous. The central form derives from the endosteum and the peripheral form derives from the periosteum, whereas the extraosseous form develops in muscular tissue structures.^[12] This lesion has a higher prevalence in males with almost double the number of cases in men than in women.^[3] However, in our series seven of the patients were women and only five were men.

The peripheral form has particular growth characteristics that make it the easiest form to diagnose because it can be verified clinically and the x-ray images are clear. Peripheral osteomas are mainly found in the frontal, ethmoid and maxillary sinuses,^[13] whereas maxillary and mandibular bone sites are less frequent.^[3] It is a rare entity in the jaws when the maxillary sinuses are excluded and the mandible is more often affected than the maxilla with the mandibular angle, condyle and the inferior border of the body being most commonly involved. In our series, we did not encounter any maxillary osteomas but six of our patients had osteoma involving some region of the mandible. Peripheral osteomas typically present as mushroom-shaped hard radiopaque masses which are often pedunculated but may also have a broad-base by which they are attached to the cortical plates. Their growth potential is usually limited; however, they will continue to slowly grow if left untreated. The differential diagnosis may include peripheral ossifying fibroma, exostoses, sessile osteochondroma, osteoid osteoma, periosteal osteoblastoma and paraosteal osteosarcoma. When an exophytic lesion presents inside the oral cavity, still firmly fixed to the underlying bone and of a bony consistency, a differential diagnosis should be made between an osteoma or a more common exostosis. A peripheral osteoma can be distinguished from an exostosis on the basis of an accurate case history and clinical characteristics, but there are no histologic differences.^[13] One of the major differences of osteoma

from other bony exostoses is the ability of this lesion to continue growing during adulthood. The term osteoma is reserved exclusively for those lesions that demonstrate independent growth and clinical characteristics of benign tumours. The slow and progressive growth of osteomas causes subsequent swelling and an asymmetric appearance which prompts clinical evaluation. On x-rays, the lesion is radiopaque with well-defined margins. Computed tomography (CT) scans should be obtained for a complete preoperative evaluation of the lesion.^[14] On CT scan, an osteoma is usually round or oval appears as a homogenous radiopaque projection on a broad base or it will be pedunculated. The margins are smooth, well defined and well corticated. The cancellous type has a normal trabecular bone pattern.

Solitary central osteomas of the jaws seem to be very rare, with only six such case reported in the English language literature since 1955^[15] and four new cases in 2008.^[16] The largest study on osteomas has recently reported 132 osteomas of the craniofacial region, of which 35 were gnathic central osteomas; however, 26 of the 106 cases had more than 1 lesion.^[5] Central osteomas pose a more challenging diagnostic problem and need to be differentiated from other similar lesions of the jaws, such as central ossifying fibroma, condensing osteitis, dense bone island and osteoblastoma, as well as cementoblastoma and odontoma in cases occurring within tooth-bearing areas. Central osteoma which is symptomatic may require a more a more radical excision along with the bone and may require reconstruction on the involved bone.

Osteomas may form in the sinuses of the skull. Presenting complaints include headaches, cerebral symptoms or visual disturbances, depending on the site of the tumour. Involvement of the orbit generally results from the direct extension of an osteoma from the adjacent paranasal sinuses. Primary intraorbital involvement is extremely rare. In our series, two of the orbital osteomas presented as pedunculated tumours, while the rest of the two had more diffuse involvement.

Histologically, three types of osteoma can be identified: compact, spongy and mixed^[13]

Patients with multiple osteomas should be evaluated for Gardner's syndrome.^[11,12] These patients may present with symptoms of rectal bleeding, diarrhoea and abdominal pain. The triad of colorectal polyposis, skeletal

abnormalities and multiple impacted or supernumerary teeth is consistent with this syndrome. Onset occurs in the second decade, with malignant transformation of the colorectal polyps approaching 100% by age 40. The skeletal involvement includes both peripheral and endosteal osteomas, which can occur in any bone but are found more frequently in the skull, ethmoid sinuses, mandible and maxilla. The mandibular osteomas are usually lobulated and located at the angle of the mandible.^[17] We encountered only one patient with this syndrome in our series.

Pain was the most frequent presenting complaint in our series and was present in eight of our patients. Those with orbital osteomas mostly had pain as the chief complaint with only one of the patient having proptosis of the eye. Neurologic disturbances may occur due to compression of adjacent nerves by the tumour. None of our cases had any neurological disturbance.

A peripheral osteoma can be completely cured by surgical intervention, and there is no recurrence. Surgery consists of removing the lesion at the base where it enters the cortical bone. The choice of therapy should be based on the general risks of the operation itself to the patient and the risk of damaging important anatomic structures adjacent to it as most of the lesions are asymptomatic and present without any functional restraints to the patient.

When considering surgical treatment, the factors to take into account should include indications for surgery, size and location of tumour, surgical approach and technique of excision. When surgery is performed, it is extremely important to plan a surgical approach that minimises any damage to the adjacent structures. Consideration must be given to achieving maximum aesthetic result by proper planning of incisions for surgical access. We have used an intraoral incision for mandibular tumours and transconjunctival incisions for the floor of orbit lesions because they give the best cosmetic results in terms of outcome. We had no difficulty during excision as both these incisions provided adequate exposure. There were no significant post-operative complications associated with these incisions. For five patients, a bicoronal approach was chosen since it gives the best possible exposure and the scar is well concealed by the hair bearing scalp. In all the patients, the cosmetic results obtained were excellent.

We had to perform reconstruction in two of the patients. The one patient with central osteoma of the mandible was reconstructed immediately with a vascularised-free fibula graft. Since we have removed the entire bone from parasymphyseal region up to the ramus decision was taken to do reconstruction with a vascularised bone graft. We have used a double-barrel free fibula for the reconstruction and did the fixation with miniplates for the upper segment of the bone and the entire bone was supported with a 2.5-mm reconstruction plate. She also had a very good aesthetic outcome. The plates were removed after a period of 2 years during which she underwent corrective rhinoplasty for the cleft nose deformity. She is now scheduled to undergo dental rehabilitation with osseointegrated implants.

The other patient who underwent excision of the frontal bone osteoma had to be reconstructed with split rib grafts. We planned to use rib grafts because these could be contoured easily to the shape of the excised frontal bone. Calvarial bone grafts were not used because they are difficult to contour for the roof of the orbit and the estimated defect was larger than that could be reconstructed with calvarial grafts. We also used a galeofrontalis flap for coverage of the grafts which has provided a well vascularised cover for the grafts and also hide minor contour defects. We did not encounter any resorption of the free split rib grafts over a follow-up period of 19 months. We presume that the flap which was used provided a well vascularised cover for the free rib grafts prevented their resorption. Overall, we obtained a very good aesthetic result.

CONCLUSION

Osteomas of the facial region although rare, need to be differentially diagnosed from other bony tumours and must be treated if symptomatic. Surgery is the mainstay of treatment for these cases and is curative with no recurrence following complete surgical excision. The final diagnosis should always be confirmed with histopathology of the specimen. However, these being benign lesions an equal emphasis should be given while planning for their removal so that the incisions are cosmetically acceptable. Reconstruction as and when required using free or vascularised bone grafts adds to the chances of a good morphological and functional outcome.

REFERENCES

1. Woldenberg Y, Nash M, Bodner L. Peripheral osteoma of the maxillofacial region. Diagnosis and management: A study of 14 cases. *Med Oral Patol Oral Cir Bucal* 2005;10(Suppl 2):E139-42.
2. Frolich MA. Mandibular osteoma: A case of impossible rigid laryngoscopy. *Anesthesiology* 2000;92:261-2.
3. Sayan NB, Cook C, Karasu HA, Gunhau O. Peripheral osteoma of the maxillofacial region: A study of 35 new cases. *J Oral Maxillofac Surg* 2002;60:1299-301.
4. Lew D, DeWitt A, Hicks RJ, Cavalcanti MG. Osteomas of the condyle associated with Gardner's syndrome causing limited mandibular movement. *J Oral Maxillofac Surg* 1999;57:1004-9.
5. Larrea-Oyarbide N, Valmaseda-Castellon E, Berini-Aytes L, Gay-Escoda C. Osteomas of the craniofacial region. Review of 106 cases. *Oral Pathol Med* 2008;37:38-42.
6. Pelo S, Spota A, Gori P, Giuliani G. Osteomas of the facial massif. *Minerva Stomatol* 1988;37:875-86.
7. Alaerts J. 2 cases of ethmoido-frontal osteoma. *Acta Otorhinolaryngol Belg* 1972;26:294-302.
8. Baraglia M, Ungari L, Pesucci B, Ponti G, Corbi S, Secondari C. Osteomas of the mandibular condyle. A case report of particular surgical interest. *Minerva Stomatol* 1985;34:275-8.
9. Stuart E. Osteoma of the mastoid: Report of a case with an investigation of the constitutional background. *Arch Otolaryngol* 1940;31:838.
10. Dubin J, Bornhauser X, Desnos J. Osteoma of the paranasal sinuses. *J Fr Otorhinolaryngol Audiophonol Chir Maxillofac* 1977;26:573-89.
11. Kaplan I, Calderon S, Buchner A. Peripheral osteoma of the mandible: A study of 10 new cases and analysis of the literature. *J Oral Maxillofac Surg* 1994;52:467-70.
12. Ziccardi VB, Smith JA, Braun TW. Osteoma of the maxillary antrum. *Oral Surg Oral Med Oral Pathol Oral Radiol Endod* 1995;80:378-9.
13. Del Vecchio A, Agrestini C, Salucci P, Manicone AM, Della Rocca C. Osteomas and exostoses of the facial structures: A morphological study and the etiopathogenetic considerations. *Minerva Stomatol* 1993;42:533-40.
14. DelBalso AM, Werning JT. The role of computed tomography in the evaluation of cemento-osseous lesions. *Oral Surg Oral Med Oral Pathol* 1986;62:354-7.
15. Petrikowski CG, Peters E. Longitudinal radiographic assessment of dense bone islands of the jaws. *Oral Surg Oral Med Oral Pathol Oral Radiol Endod* 1997;83:627-34.
16. Kaplan I, Nicolaou Z, Hatuel D, Calderon S. Solitary central osteoma of the jaws: A diagnostic dilemma. *Oral Surg Oral Med Oral Pathol Oral Radiol Endod*. 2008;106:e22-9.
17. Jones K, Korzack P. The diagnostic significance and management of Gardner's syndrome. *Br J Oral Maxillofac Surg* 1990;28:80-4.

How to cite this article: Gundewar S, Kothari DS, Mokal NJ, Ghalme A. Osteomas of the craniofacial region: A case series and review of literature. *Indian J Plast Surg* 2013;46:479-85.

Source of Support: Nil, **Conflict of Interest:** None declared.

Dispatch and return notification by E-mail

The journal now sends email notification to its members on dispatch of a print issue. The notification is sent to those members who have provided their email address to the association/journal office. The email alerts you about an outdated address and return of issue due to incomplete/incorrect address.

If you wish to receive such email notification, please send your email along with the membership number and full mailing address to the editorial office by email.