

Original Article

Effect of intense pulsed light on immature burn scars: A clinical study

Arindam Sarkar, Yatindra Kumar Dewangan, Jayanta Bain, Pritha Rakshit, Krishnanand Dhruw, Sandip Kanti Basu, Jayanta Kumar Saha, Bijay Kumar Majumdar

Department of Plastic Surgery, Institute of Post Graduate Medical Education and Research, Kolkata, West Bengal, India

Address for correspondence: Dr. Yatindra Kumar Dewangan, Near Gandhi Garden, Sankara Road Nagri, Dhamtati, Chhattisgarh, India.
Email: dryatindrakd@gmail.com

ABSTRACT

Introduction: As intense pulsed light (IPL) is widely used to treat cutaneous vascular malformations and also used as non-ablative skin rejuvenation to remodel the skin collagen. A study has been undertaken to gauge the effect of IPL on immature burn scars with regard to vascularity, pliability and height. **Materials and Methods:** This study was conducted between June 2013 and May 2014, among patients with immature burn scars that healed conservatively within 2 months. Photographic evidence of appearance of scars and grading and rating was done with Vancouver Scar Scale parameters. Ratings were done for both case and control scar after the completion of four IPL treatment sessions and were compared. **Results:** Out of the 19 cases, vascularity, pliability and height improved significantly ($P < 0.05$) in 13, 14 and 11 scars respectively following IPL treatment. **Conclusions:** Intense pulsed light was well-tolerated by patients, caused good improvement in terms of vascularity, pliability, and height of immature burn scar.

KEY WORDS

Burn scar; intense pulse light; vancouver scar scale

INTRODUCTION

Natural history of deep burns is that, they heal by post-burn scars; and the extent and magnitude of scarring is directly related to the severity of burn, duration of healing process. Burn scar has a huge impact on the mental health of the patient; it also causes considerable functional morbidity, such as contractures, hypertrophic scar, keloid, and neuropathic pain.^[1] Hence, the management of post-burn scar is a huge challenge.^[2]

Burn wound heal with secondary intention and it often had a long overlapping inflammatory, proliferative and remodelling phase. Proliferative phase is characterized by granulation tissue which is composed of three cell types, namely fibroblasts, endothelial cells, and keratinocytes. Fibroblast may play a major role in synthesis of extracellular matrix. Endothelial cells form new blood vessels and keratinocytes migrates over the granulation tissue to cover it. In remodelling phase the scar matures, which may take several month to years, is by far the least-understood phase of wound healing. This phase is characterised by replacement of the initially laid down type III collagen by type I collagen^[3] which are more thicker and stable;^[4]. Collagen remodelling, causes regression of blood vessels and the wound becomes contracted by the actions of myofibroblasts.^[3]

Access this article online	
Quick Response Code:	Website: www.ijps.org
	DOI: 10.4103/0970-0358.146596

Thus initially the immature burn scar remains hyper vascular (containing oxy-haemoglobin), collagen and water. These bio-molecules present in the scar are conventionally used as the target chromophore for various laser treatments with good results.^[5-8] At present, there are very few studies on the use of intense pulsed light (IPL) for the treatment of immature burn scars;^[9] Hence aim of this study was to appreciate the effect of IPL on immature burn scar in the terms of colour, thickness and pliability of the scar.

MATERIALS AND METHODS

This is a 1-year (June 2013 to May 2014) prospective, non-randomised, case — control study conducted in the Department of Plastic Surgery in our institution. Before starting the study, Institutional Ethical Committee clearance was taken.

Inclusion and exclusion criteria

Cooperative patients above 10 years of age who had newly healed immature burn scars were taken up for this study. They had immature scars of partial thickness burns that healed by conservative treatment in 2 months without skin grafting. Similar adjacent scars were taken as controls. Hypertrophic scar were excluded from the study. In these selected patients no other form of therapy was applied.

Wound assessment

Photographic evidence of appearance of scars and grading and rating was done with the Vancouver Scar Scale (VSS)^[10] parameters based on vascularity, pliability and height before the start of treatment.

Vascularity of the scar was assessed by inspection and photographic evidence of the colour of the scar. Pliability was measured by applying torsion force over the surface of scar in the horizontal plane.^[11,12] Height was measured with measuring scale by keeping it tangentially at the normal skin and scar junction. Scars were considered hypertrophic when the scores of vascularity and height were grade 2 or grade 3 and pliability grade 3 or grade 4 or grade 5. Hypertrophic scars were excluded from study. All these 3 parameters were rated using VSS at the start of treatment.

Photographs were taken with 4 mega pixel camera at a distance of 30-40 cm in a good illumination capturing both the case and control scars simultaneously. Setting of the camera kept same for all patients.

Settings of intense pulsed light machine

It is kept common for all patients at Chiller at maximum; wavelength 590 nm; fluence 25 J/cm²; size of the glass piece of hand piece was 1 cm × 4 cm through which light passes to the scars.

Treatment procedure

Patient was instructed to apply surface anaesthetic cream locally on the treatment area half an hour before the start of IPL session. After removal of anaesthetic cream the Ultrasound electro gel was applied over treatment area and IPL therapy given to the case scars by just touching the surface of scar with the Glass piece of hand piece of IPL machine and triggering the pulse, without overlapping with the previous spot. After the treatment session ice pack was applied to treatment area to minimize the discomfort associated with the treatment. Antibiotic ointment along with steroid is advised for local application. Patient was asked to come for successive treatments after 21 days each for 4 times. Photographic records were kept before every session of treatment [Figures 1a, b, 2a and b].

Statistical analysis

All statistical analyses were performed with SPSS software version 11.0.1 for Windows (SPSS Inc., Chicago, IL, USA). The Chi-square test was used to examine the associations between categorical outcome variables with the IPL treatment. All statistical tests were two sided. $P < 0.05$ were considered as significant.

RESULTS

Twenty four patients got enrolled during the period of study, of which 2 patients did not come for first treatment, 3 patients were treated only once thereafter they were lost to follow up and hence total 19 patients

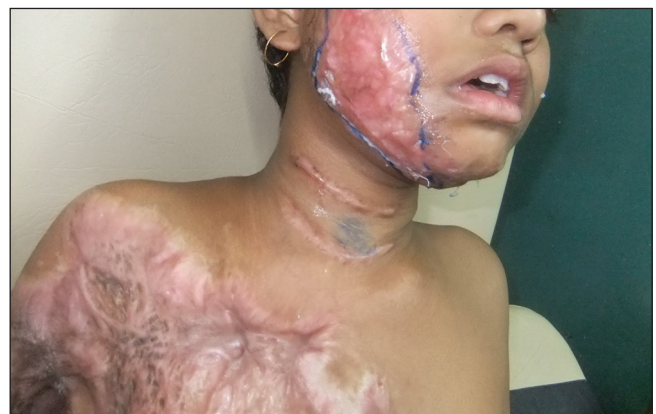

Figure 1a: Pre-treatment photograph of case 1

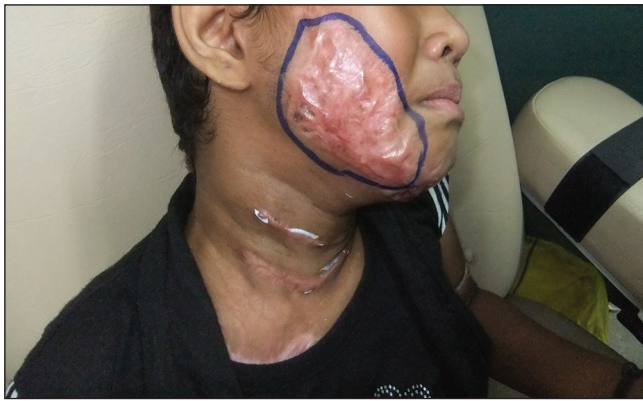

Figure 1b: Post-treatment (after 4 session of intense pulsed light) photograph of case 1

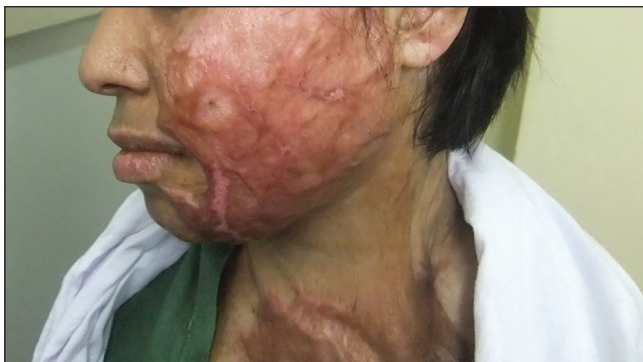

Figure 2a: Pre-treatment photograph of case 16

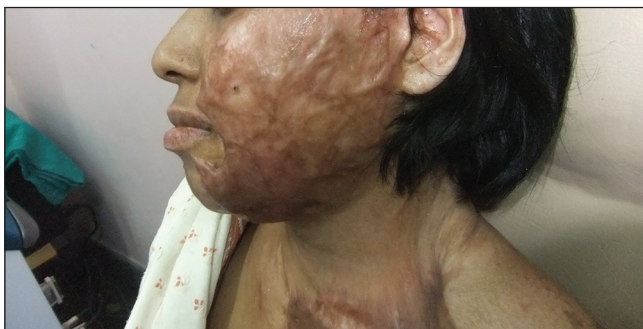

Figure 2b: Post-treatment (after 4 session of intense pulsed light) photograph of case 16

were studied. Of 19 patients only 3 were male and rests were female. All patients were between the ages of 10-40 years [Table 1].

Majority of immature scars selected for study had vascularity about grade 2, pliability around grade 2 and height about grade 1 in grading as per VSS scale. Both the adjacent scars were comparable in all patients according to VSS parameters.

Vascularity decreased in 13 scars and they became pink from red with IPL treatment compared to control scars where only in 1 out of 19 cases showed such change

without treatment ($P < 0.05$). In terms of pliability, 14 scars improved after IPL treatment and became supple from yielding, while, only 2 scars improved in the control arm ($P < 0.05$) of 19 cases. And height of 11 scars became near normal (flat) with the IPL treatment, whereas, only 1 scar improved in control arm ($P < 0.05$) [Table 2].

The procedure (IPL sessions) were well-tolerated by patients; most patients complained only mild snapping sensation after proper surface anaesthetics application.

DISCUSSION

Intense pulsed light, commonly abbreviated as IPL, describes the use of intense pulses of non-coherent light distributed over a range of wavelengths from 500 nm to 1200 nm.^[13] Although not technically a laser, IPL works on the principles of laser, that is, selective photothermolysis, which says that, light energy is absorbed by particular target chromophore and then converted to heat energy, which causes damage to the specific target area.^[9]

As IPL systems deliver many wavelengths (500-1300 nm), with aid of a cut-off filter, a targeted wavelength can be produced. Significant light absorption by oxyhaemoglobin occurs in the range of yellow and green light; with peak absorption at 418 nm, 542 nm, and 577 nm; maximum absorption by collagen occurs in visible and near infrared spectra.^[14] Thus, mono-chromaticity is not a requirement for these chromophores to get activated to cause photothermolysis of target tissue. As IPL emits a spectrum of wavelengths, the key chromophores can be activated with one single pulse.^[13]

In clinical practice, currently IPL therapy is used to treat a number of decreases like unwanted hair removal, to treat vascular lesions, pigmented lesions, acne vulgaris, and to rejuvenate skin.^[13] In facial rejuvenation IPL is used as non-ablative resurfacing technique, where it targets the dermis without affecting the epidermis. Though the exact mechanism is unknown,^[13] such laser-induced remodelling may be associated with evidence of new dermal collagen formation. A study by Goldberg showed histologic evidence of new upper papillary dermal collagen formation. He concluded that dermal remodelling with an IPL source can lead to histologic evidence of new collagen formation with associated clinical improvement.^[15] Recently Feng *et al.*, histologically examined the pre- and post-IPL rejuvenated skin. They found increased activity

Table 1: Clinical profile of the study population

Patient	Age (years)	Sex	Treatment area	Control area
1	10	Female	Cheek	Neck
2	23	Female	Cheek	Cheek
3	11	Female	Neck	Cheek
4	27	Female	Breast	Breast
5	35	Male	Forearm	Fore arm
6	24	Female	Back	Back
7	40	Female	Thigh	Thigh
8	43	Female	Shoulder	Chest
9	38	Female	Shoulder	Arm
10	41	Male	Chest	Chest
11	34	Female	Cheek	Cheek
12	37	Female	Breast	Breast
13	22	Female	Neck	Face
14	16	Male	Hand	Forearm
15	42	Female	Forearm	Forearm
16	21	Female	Face	Neck
17	13	Female	Hand	Hand
18	19	Female	Neck	Neck
19	32	Female	Forehead	Forehead

Table 2: Comparison of scars after the completion of 4 sitting of treatments in terms of VSS parameters

Grade	Case	Control	P
Vascularity of scar			
0	—	—	<0.005
1	13	6	
2	6	13	
3	—	—	
Pliability of scar			
0	—	—	<0.005
1	14	2	
2	5	12	
3	—	5	
4	—	—	
5	—	—	
Thickness of scar			
0	11	1	<0.005
1	8	14	
2	—	4	

VSS: Vancouver scar scale

of fibroblasts; increased type-I and type-III collagens; and decreased elastin content, though the elastin fibres get neatly re-arranged, thus, there was a morphological evidence of clinical improvement.^[16]

The IPL today is also the mostly employed in treatment of variety vascular malformations and haemangiomas, such as, port-wine stains, rosacea, telangiectasia etc.^[13] Here the IPL targeted on the chromophore oxyhaemoglobin, which is abundant in the blood vessels. When activated, by IPL it causes photocoagulation of vascular endothelium, leading to fibrosis and obliteration of the

blood vessels,^[17] thus ensuring improvement of the clinical condition.

Regarding burn scar management by laser, 585 nm PDL is used for last 10 years, and showed good result,^[5-7] but there are very few result showing effect of IPL on burn scar,^[9] especially in immature burn scar. As the immature burn scar has lot of collagen and it is hyper vascular, so, theoretically there is a great scope to control the collagen metabolism and decrease the blood vessels by treating it with IPL and to give a better appearance of the burn scar. In our study, we have shown that there was a significant ($P < 0.05$) decrease of scar vascularity and significant improvement of pliability of scar and it had become flat after treatment with IPL. These were probably because IPL caused coagulation necrosis of the blood vesicle and it may hasten the collagen metabolism as described above.^[15-17]

CONCLUSIONS

IPL causes early decrease of scar vascularity and flattening of scar (reduction of height); it also increases pliability of immature burn scar and thus prevents development of hypertrophic scar. Further studies with increased sample size and longer periods of follow up along with histological and biochemical analysis of pre- and post-treatment scar is required to evaluate the role of IPL on immature burn scars.

ACKNOWLEDGMENT

We acknowledge Prof. Dr. S. S. Chatterjee, Ex-Professor, Department of Plastic Surgery IPGME&R, Kolkata, India, for his guidance and supervision during preparation of this article.

REFERENCES

- Bain J, Lal S, Baghel VS, Yedalwar V, Gupta R, Singh AK. Decaderial of a burn center in Central India. *J Nat Sci Biol Med* 2014;5:116-22.
- Goel A, Shrivastava P. Post-burn scars and scar contractures. *Indian J Plast Surg* 2010;43:S63-71.
- Gurtner GC. Wound healing: Normal and abnormal. In: Thorne CH, Beasley RW, Aston SJ, Bartlett SP, Gurtner GC, Spear SL, editors. *Grabb and Smith's Plastic Surgery*. Philadelphia: Wolters Kluwer Lippincott Williams and Wilkins; 2006. p. 16-22.
- Horch RE, Bleiziffer O, Kneser U. Physiology and wound healing. In: Siemionow MZ, Eisenmann-Klein M, editors. *Plastic and Reconstructive Surgery*. 1st ed. London: Springer-Verlag London Limited; 2010. p. 3-11.
- Kono T, Erçöçen AR, Nakazawa H, Nozaki M. Treatment of hypertrophic scars using a long-pulsed dye laser with cryogen-spray cooling. *Ann Plast Surg* 2005;54:487-93.

6. Parrett BM, Donelan MB. Pulsed dye laser in burn scars: Current concepts and future directions. *Burns* 2010;36:443-9.
7. Bouzari N, Davis SC, Nouri K. Laser treatment of keloids and hypertrophic scars. *Int J Dermatol* 2007;46:80-8.
8. Khatri KA, Mahoney DL, McCartney MJ. Laser scar revision: A review. *J Cosmet Laser Ther* 2011;13:54-62.
9. Hultman CS, Edkins RE, Lee CN, Calvert CT, Cairns BA. Shine on: Review of laser-and light-based therapies for the treatment of burn scars. *Dermatol Res Pract* 2012;2012:243651.
10. Sullivan T, Smith J, Kermode J, McIver E, Courtemanche DJ. Rating the burn scar. *J Burn Care Rehabil* 1990;11:256-60.
11. Murray BC, Wickett RR. Correlation between dermal torque meter and dermal phase meter measurement of human skin. *Skin Res Technol* 1997;3:101-6.
12. Boyce ST, Supp AP, Wickett RR, Hoath SB, Warden GD. Assessment with the dermal torque meter of skin pliability after treatment of burns with cultured skin substitutes. *J Burn Care Rehabil* 2000;21:55-63.
13. Babilas P, Schreml S, Szeimies RM, Landthaler M. Intense pulsed light (IPL): A review. *Lasers Surg Med* 2010;42:93-104.
14. Vrijman C, van Drooge AM, Limpens J, Bos JD, van der Veen JP, Spuls PI, *et al.* Laser and intense pulsed light therapy for the treatment of hypertrophic scars: A systematic review. *Br J Dermatol* 2011;165:934-42.
15. Goldberg DJ. New collagen formation after dermal remodeling with an intense pulsed light source. *J Cutan Laser Ther* 2000;2:59-61.
16. Feng Y, Zhao J, Gold MH. Skin rejuvenation in Asian skin: The analysis of clinical effects and basic mechanisms of intense pulsed light. *J Drugs Dermatol* 2008;7:273-9.
17. Sánchez Carpintero I, Mihm MC, Waner M. Laser and intense pulsed light in the treatment of infantile haemangiomas and vascular malformations. *An Sist Sanit Navar* 2004;27 Suppl 1:103-15.

How to cite this article: Sarkar A, Dewangan YK, Bain J, Rakshit P, Dhruw K, Basu SK *et al.* Effect of intense pulsed light on immature burn scars: A clinical study. *Indian J Plast Surg* 2014;47:381-5.

Source of Support: Nil, **Conflict of Interest:** None declared.

New features on the journal's website

Optimized content for mobile and hand-held devices

HTML pages have been optimized for mobile and other hand-held devices (such as iPad, Kindle, iPod) for faster browsing speed.

Click on **[Mobile Full text]** from Table of Contents page.

This is simple HTML version for faster download on mobiles (if viewed on desktop, it will be automatically redirected to full HTML version)

E-Pub for hand-held devices

EPUB is an open e-book standard recommended by The International Digital Publishing Forum which is designed for reflowable content i.e. the text display can be optimized for a particular display device.


Click on **[EPub]** from Table of Contents page.

There are various e-Pub readers such as for Windows: Digital Editions, OS X: Calibre/Bookworm, iPhone/iPod Touch/iPad: Stanza, and Linux: Calibre/Bookworm.

E-Book for desktop

One can also see the entire issue as printed here in a 'flip book' version on desktops.

Links are available from Current Issue as well as Archives pages.

Click on  View as eBook