

Case Report

Long term assessment of intralipotherapy in Madelung's disease

Silvia Scevola¹, Giovanni Nicoletti^{1,2,3}, Antonino Neri⁴, Angela Faga^{1,2,3}

¹Advanced Technologies for Regenerative Medicine and Inductive Surgery Research Centre, University of Pavia, Viale Brambilla 74, ²Department of Clinical Surgical Diagnostic and Pediatric Sciences, Plastic and Reconstructive Surgery, University of Pavia, Via Aselli 45, ³Plastic and Reconstructive Surgery Unit, Salvatore Maugeri Research and Care Institute, Via Salvatore Maugeri 10, ⁴Radiology Unit, Salvatore Maugeri Research and Care Institute, Via Salvatore Maugeri 10, 27100 Pavia, Italy

Address for correspondence: Dr. Giovanni Nicoletti, Plastic and Reconstructive Surgery, University of Pavia, Salvatore Maugeri Research and Care Institute, Via Salvatore Maugeri, 10, 27100 Pavia, Italy. E-mail: giovanni.nicoletti@unipv.it

ABSTRACT

Madelung's disease is characterised by multiple symmetric abnormal fat masses in the head, neck and upper limbs. Surgical excision or liposuction is the only realistic available option, although palliative in nature. The serial intralipotherapy with phosphatidylcholine/deoxycholate has been proposed as a non-invasive treatment of Madelung's disease. The authors used serial intralipotherapy with phosphatidylcholine/deoxycholate in two patients affected by Madelung's disease. Three injections per lesion per patient were performed with 1 month's interval. Pre- and 6 months' post-treatment dimensions were assessed with ultrasound scan and patients were observed along a 5 years' clinical follow-up. A 42.5% average size reduction was reported in all treated lesions. About 33% recurrence rate was observed in the 5 years' follow-up. We confirm the efficacy of intralipotherapy in the non-invasive palliative treatment of Madelung's disease, as a valid option to reduce the volume and limit the growth of the pathological adipose masses.

KEY WORDS

Deoxycholate; intralipotherapy; Madelung's disease; phosphatidylcholine; ultrasounds

INTRODUCTION

Madelung's disease is characterised by multiple disfiguring abnormal fat masses in the head, the neck, and the radix of upper limbs;^[1] in 90% of cases it's associated with alcohol abuse.^[2]

Surgical treatment can be mandatory although palliative, owing to an high recurrence rate.^[3]

The local injections of phosphatidylcholine/deoxycholate solution have been gaining an increasing consensus as a non-invasive method to shrink localized adiposities.^[4]

The authors report their long term experience on the assessment of serial intralipotherapy with phosphatidylcholine/deoxycholate in two patients affected by Madelung's disease.

MATERIALS AND METHODS

Two male patients suffering from Madelung's disease underwent serial intralipotherapy with phosphatidylcholine/deoxycholate (Lipostabil®-Nattermann Pharma, Cologne, Germany).

Access this article online	
Quick Response Code: 	Website: www.ijps.org
	DOI: 10.4103/0970-0358.146638

Three injections per lesion per patient were performed at 1 month's time interval. Pre- and 6 months' post-treatment dimensions were assessed by measuring three diameters in each lesion with a 7.5 MHz probe ultrasound (US) scan performed by the same operator. Serum lipid pattern was tested before and 1 month after the end of treatment. The patients were then observed along a 5 years' clinical follow-up.

CASE REPORTS

Case 1

A 45-year-old man, smoker, without history of alcohol abuse, affected by multiple comorbidities, presented with symmetric huge lipomatosis of the head, neck, dorsum, posterior aspect of the arms and testicles. Chest X-rays and head and neck magnetic resonance imaging (MRI) confirmed the infiltrative distribution of the lipomatosis and excluded the involvement of the trachea and other deep structures. Even if a previous surgical excision of some cervico-occipital adipose deposits had been successful, the patient, who was still physically and psychologically impaired, refused a further

surgical treatment under general anaesthesia of the remaining untreated adipose deposits: these infiltrating masses were therefore addressed with serial intralesional Lipostabil® injections.

Under US scan control 5 ml of Lipostabil® were injected into the jugular, submandibular and right cheek masses, respectively. The injections were repeated monthly for an overall of three treatments per lesion [Figures 1 and 2].

Case 2

A 49-year-old-man, with a history of alcohol abuse and multiple comorbidities presented with enormous bilateral axillary fat deposits and some unpleasant adipose deposits in the dorsum and the submental and supraclavicular areas.

The axillary masses were surgically addressed, with no evidence of recurrence at 4 years' follow-up.

Three other smaller submental and bilateral supraclavicular deposits were injected with 5 ml of Lipostabil® each under US scan control. The injections were repeated monthly for an overall of three treatments per lesion [Figures 3 and 4].

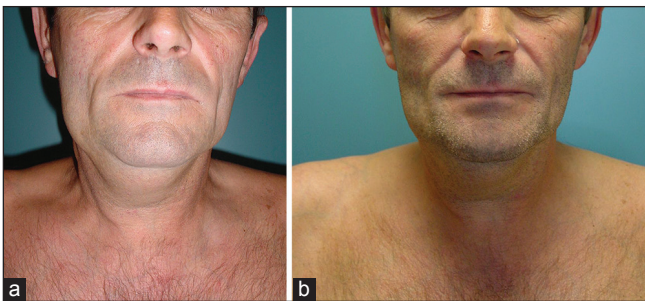

Figure 1: Case 1, right cheek mass: (a) Pre-treatment view; (b) post-treatment view

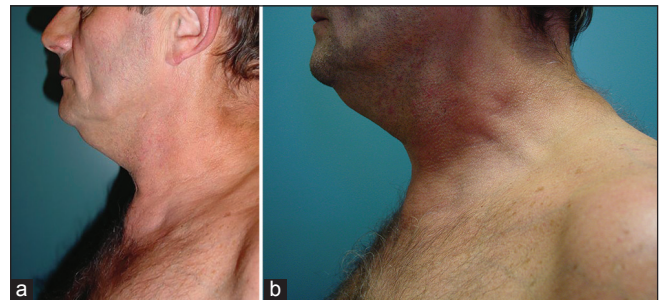

Figure 2: Case 1, submandibular and jugular masses: (a) Pre-treatment view; (b) post-treatment view

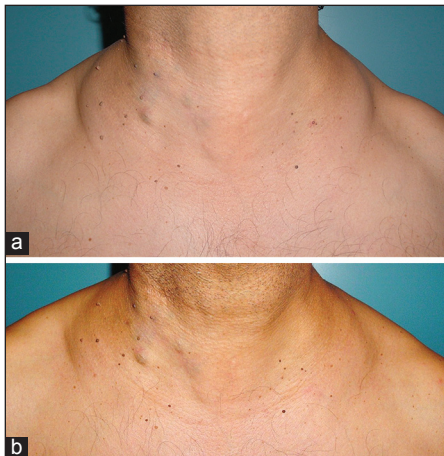

Figure 3: Case 2, bilateral supraclavicular masses: (a) Pre-treatment view; (b) post-treatment view

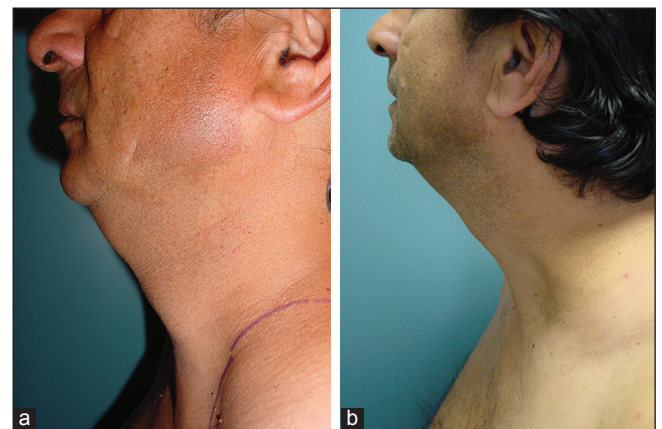

Figure 4: Case 2, submental mass: (a) Pre-treatment view; (b) post-treatment view

RESULTS

Clinically, a significant progressive shrinkage together with a change from a soft to a harder consistency of the adipose masses was appreciated. No alterations were reported in serum lipid pattern 1 month after the last treatment. At 6 months' follow-up all of the lesions appeared stable. Dimension changes in the treated lesions as demonstrated by US scan 6 months after the treatment are reported in Table 1 and Figure 5. No local and/or systemic side-effects were reported. In both patients, one treated lesion out of three showed a slow clinical progression and required surgical excision. The former intralipotherapy did not increase the difficulty of surgery. All of the other treated lesions are clinically stable at 5 years' follow-up.

DISCUSSION

Madelung's disease is a lipomatosis classified in type 1, with adipose masses symmetrically distributed in the body and in type 2, with a diffuse obese-like fat distribution.^[5]

Diagnosis is clinically based and MRI, computed tomography, and US scan allow evaluation of the fat deposits distribution.

Our two cases belong to type 1 with evident deposits in the head and neck.

Both patients had their major masses surgically removed; the smaller, but more visible ones were deliberately addressed non-surgically with Lipostabil®, in order to avoid or at least postpone further surgery.

Lipostabil® is a solution of phosphatidylcholine/deoxycholate licensed for i.v. treatment of hyperlipidemias and fat emboli, but diffusely employed subcutaneously in

an off-label regimen to reduce localised adiposity and the volume of lipomas.^[6]

The off-label use of Lipostabil® for the treatment of localised adiposity is actually controversial in the literature.^[7] In 2010, the United States Food and Drug Administration (FDA) cautioned medical spas against misleading consumers by false statements about drugs including phosphatidylcholine/deoxycholate that would eliminate fat in a procedure called "lipodissolve." The FDA keeps encouraging health care professionals and consumers to report any side-effects with the use of these drugs to the FDA's MedWatch Adverse Event Reporting Program.^[8]

State legislation on the clinical use of Lipostabil® is inhomogeneous worldwide. It is approved for cardiological use to reduce cholesterol in some countries in Europe, though not including the United Kingdom.

Until date, Lipostabil® is not available in the Italian market as the product trade registration was no longer provided by the manufacturer since May the 20th 2004. Nevertheless, in Italy, by the law 94/1998 the clinical use of phosphatidylcholine/deoxycholate is currently allowed as a galenical under the following strict circumstances:^[9] the treatment should be tailored on one individual patient, the physician should provide the patient a fully informed consent and the prescription should provide both the patient's identity data and a reference number to the physician's medical archive.

Its lipolytic action seems to be based on stimulation of lipase activity, emulsification and transport of

Table 1: Measures in centimetres of the three main diameters at US scan before and after 3 injections of Lipostabil®

Cases/Sites	Pre-treatment			Post 3 injections		
	L	T	A-P	L	T	A-P
Case 1						
Sovrajugular	4.2	5.7	1.3	3.3	2.8	0.8
Submandibular	6.5	6.5	2.5	4.5	2.9	1.5
Right cheek	3.8	3.8	0.7	2.4	2.0	0.4
Case 2						
Submental	5.0	8.0	3.5	4.3	4.3	1.0
Right sovraclavear	7.5	5.0	3.5	4.5	3.4	1.4
Left sovraclavear	7.5	5.0	3.2	3.5	3.3	1.5

L: Longitudinal; T: Transversall A-P: Anterior-posterior; US: Ultrasound

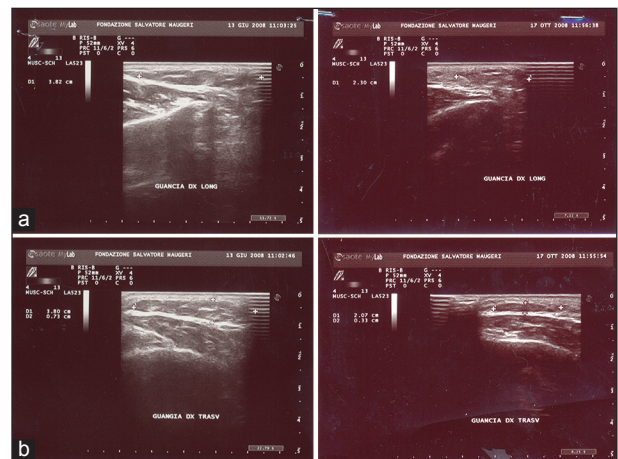


Figure 5: Ultrasound scan images-Case 1, right cheek mass: (a) Pre-treatment; (b) post-treatment

triglycerides and a detergent action by its two main components, both causing cell membrane lysis, inflammation, fibrosis and degeneration of fat tissue.^[10] In one case acute renal failure and liver dysfunction have been reported as severe systemic side-effects following a single high dose subcutaneous injection.^[11] Recently, it has been suggested that phosphatidylcholine might eventually have some therapeutic role in some cancers as animal studies indicate that deficiencies in choline and phosphatidylcholine may disrupt cell membrane signal transduction in ways that could lead to various cancers.^[12] Furthermore, there is ample evidence that liver cancer is promoted in various animals by choline-deficient diets,^[13] and it has been shown that excess choline has a protective effect against carcinogenesis.^[14-16]

Known safety limits of phosphatidylcholine/deoxycholate compound are 15 mg/kg.^[17]

A successful experience of serial intralipotherapy with a blend of lidocaine, aminophyllin, L-carnitine, phosphatidylcholine and deoxycholate solution for the treatment of one patient affected by Madelung's disease is reported.^[18]

According to the literature common off-label use of phosphatidylcholine/deoxycholate compound for localised fat deposits ranges between 1000 and 250 mg/session.^[19] Our choice of Lipostabil[®] dosage, therefore, considered both the fat masses size and those safety limits.

Our results objectively demonstrated an average reduction of 42.5% in the three US scan measured diameters in all of the treated lesions 6 months after the treatment [Table 2 and Figure 5].

The 5 years' clinical follow-up demonstrated the long-term functional and cosmetic stable results in 66% of the treated lesions.

The treatment also proved to be safe as serum lipid status was not modified at 1 month since the last infiltration session.

In Madelung's disease, the surgical approach is always invasive and often risky both for the anatomical complexity of the involved areas (cervico-facial regions) and for these patients' general conditions, which are

Table 2: Percentage reduction of the masses at US scan in the three main diameters

Cases/Sites	Δ%			Mean Δ%
	L	T	A-P	
Case 1				
Sovrajugular	23	50	38	37
Submandibular	30	55	40	41.6
Right cheek	37	47	43	42.3
Case 2				
Submental	14	46	71	43.6
Right sovraclavear	40	32	60	44
Left sovraclavear	53	34	53	46.6
Average overall percentage reduction				42.5

Δ: Delta; L: Longitudinal; T: Transversal; A-P: Anterior-posterior; US: Ultrasound

poor most of the time. The objectively demonstrated efficacy and safety of the treatment at the employed dosage together with its easy execution confirm the role of Lipostabil[®] as a non-invasive palliative reasonable therapeutic opportunity in Madelung's disease and an alternative to surgery in the more awkward locations of the disease.

CONCLUSIONS

The phosphatidylcholine/deoxycholate compound needs wide investigation for new treatment uses and long-term studies and hence that the recommended dose and safe application technique can be standardised.

The use of "lipodissolve" products should be considered an experimental treatment and be performed under strict medical control for both therapeutical and cosmetic purposes.

Our experience might, therefore, further contribute to the investigation of limits and possibilities of the clinical use of phosphatidylcholine/deoxycholate in the treatment of localised adiposities of any nature.

According to our experience the inclusion of phosphatidylcholine/deoxycholate intralesional intralipotherapy in the armamentarium for the palliative treatment of Madelung's disease might be recommended to reduce the volume and limit the growth of the pathological adipose masses and to restrict the aggressive and often unacceptable anatomical consequences of the disease.

ACKNOWLEDGEMENTS

The Authors wish to thank Gian Mario Pelizzoli for his much appreciated technical support.

REFERENCES

- Madelung OW. Über den fetthals (diffuses lipom des halses). *Langenbecks Arch Klin Chir* 1888;37:106-30.
- Knöbber D, Feidt H, Hornberger W. Madelung's lipomatosis of the neck – expression of an alcohol-induced endocrine disorder? *HNO* 1986;34:474-6.
- Carlin MC, Ratz JL. Multiple symmetric lipomatosis: Treatment with liposuction. *J Am Acad Dermatol* 1988;18:359-62.
- RotundaAM, KolodneyMS. Mesotherapy and phosphatidylcholine injections: Historical clarification and review. *Dermatol Surg* 2006;32:465-80.
- Hasegawa T, Matsukura T, Ikeda S. Mesotherapy for benign symmetric lipomatosis. *Aesthetic Plast Surg* 2010;34:153-6.
- Enzi G. Multiple symmetric lipomatosis: An updated clinical report. *Medicine (Baltimore)* 1984;63:56-64.
- van Aerts LA. Adipocytolysis by subcutaneous injection of Lipostabil. *RIVM Brief Report*. 360007001/2010; 2010.
- Food and Drug Administration (FDA). FDA news release. Consumer inquiries: 888-INFO-FDA. Media inquiries: Tom Gasparoli, 301-796-4737. Available from: <http://www.fda.gov/NewsEvents/Newsroom/PressAnnouncements/ucm207453.htm>. [Last accessed on 2010 Apr 07].
- Law April the 8th 1998 number 94. Official Gazzette of the Italian Republic, number 86, April the 14th 1998, Polygraph Institute and National Mint, Italy.
- Bechara FG, Sand M, Sand D, Rotterdam S, Stücker M, Altmeyer P, et al. Lipolysis of lipomas in patients with familial multiple lipomatosis: An ultrasonography-controlled trial. *J Cutan Med Surg* 2006;10:155-9.
- Rey JW, Schreiner O, Barreiros AP, Heise M, Krupp M, Schuchmann M, et al. Acute renal failure and liver dysfunction after subcutaneous injection of 3-sn-phosphatidylcholine (Lipostabil®)-case report. *Z Gastroenterol* 2011;49:340-3.
- Zeisel SH. Dietary choline deficiency causes DNA strand breaks and alters epigenetic marks on DNA and histones. *Mutat Res* 2012;733:34-8.
- Newberne PM, Conner MW. Dietary modifiers of cancer. *Prog Clin Biol Res* 1988;259:105-29.
- Sakakima Y, Hayakawa A, Nagasaka T, Nakao A. Prevention of hepatocarcinogenesis with phosphatidylcholine and menaquinone-4: *In vitro* and *in vivo* experiments. *J Hepatol* 2007;47:83-92.
- Sakakima Y, Hayakawa A, Nakao A. Phosphatidylcholine induces growth inhibition of hepatic cancer by apoptosis via death ligands. *Hepatogastroenterology* 2009;56:481-4.
- Dial EJ, Doyen JR, Lichtenberger LM. Phosphatidylcholine-associated nonsteroidal anti-inflammatory drugs (NSAIDs) inhibit DNA synthesis and the growth of colon cancer cells *in vitro*. *Cancer Chemother Pharmacol* 2006;57:295-300.
- Schuller-Petrovic S, Wölkart G, Höfler G, Neuhold N, Freisinger F, Brunner F. Tissue-toxic effects of phosphatidylcholine/deoxycholate after subcutaneous injection for fat dissolution in rats and a human volunteer. *Dermatol Surg* 2008;34:529-42.
- Lipostabil N® i.v. 5 ml information sheet Artesan Pharma. Luchow, Germany.
- Salti G, Ghersetich I, Tantussi F, Bovani B, Lotti T. Phosphatidylcholine and sodium deoxycholate in the treatment of localized fat: A double-blind, randomized study. *Dermatol Surg* 2008;34:60-6.

How to cite this article: Scevola S, Nicoletti G, Neri A, Faga A. Long term assessment of intralipotherapy in Madelung's disease. *Indian J Plast Surg* 2014;47:427-31.

Source of Support: Nil, **Conflict of Interest:** None declared.

Announcement

Subscription Information

Copies of the journal are provided free of cost to the member of the ASSOCIATION OF PLASTIC SURGEONS OF INDIA. A subscription to Journal of Indian Journal of Plastic Surgery comprises 3 issues. Prices include postage. Annual Subscription Rate for non-members-

- Institutional: INR 2400.00 for India and USD 210.00 for outside India
- Personal: INR 1500.00 for India and USD 120.00 for outside India

For mode of payment and other details, please visit www.medknow.com/subscribe.asp.

Claims for missing issues will be serviced at no charge if received within 60 days of the cover date for domestic subscribers, and 3 months for subscribers outside India. Duplicate copies cannot be sent to replace issues not delivered because of failure to notify publisher of change of address.

The journal is published and distributed by Medknow Publications and Media Pvt. Ltd. Copies are sent to subscribers directly from the publisher's address. It is illegal to acquire copies from any other source. If a copy is received for personal use as a member of the association/society, one cannot resale or give-away the copy for commercial or library use.

The copies of the journal to the members of the association are sent by ordinary post. The editorial board, association or publisher will not be responsible for non receipt of copies. If any member/subscriber wishes to receive the copies by registered post or courier, kindly contact the publisher's office. If a copy returns due to incomplete, incorrect or changed address of a member/subscriber on two consecutive occasions, the names of such members will be deleted from the mailing list of the journal. Providing complete, correct and up-to-date address is the responsibility of the member/subscriber.

Nonmembers: Please send change of address information to subscriptions@medknow.com.