

## Original Article

# Rigid internal fixation of zygoma fractures: A comparison of two-point and three-point fixation

Atul Parashar, Ramesh K. Sharma, Surinder Makkar

Department of Plastic Surgery, Postgraduate Institute of Medical Education and Research, Chandigarh - 160 012, India

**Address for correspondence:** Dr. Ramesh Kumar Sharma, Department of Plastic Surgery, PGIMER, Sector-12, Chandigarh, India.  
E-mail: drsharmark@yahoo.com

## ABSTRACT

**Background:** Displaced fractures of the zygomatic bone can result in significant functional and aesthetic sequelae. Therefore the treatment must achieve adequate and stable reduction at fracture sites so as to restore the complex multidimensional relationship of the zygoma to the surrounding craniofacial skeleton. Many experimental biophysical studies have compared stability of zygoma after one, two and three-point fixation with mini plates. We conducted a prospective clinical study comparing functional and aesthetic results of two-point and three-point fixation with mini plates in patients with fractures of zygoma.

**Materials and Methods:** Twenty-two patients with isolated zygomatic fractures over a period of one year were randomly assigned into two-point and three-point fixation groups. Results of fixation were analyzed after completion of three months. This included clinical, radiological and photographic evaluation.

**Results:** The three-point fixation group maintained better stability at fracture sites resulting in decreased incidence of dystopia and enophthalmos. This group also had better malar projection and malar height as measured radiologically, when compared with the two-point fixation group.

**Conclusion:** We recommend three-point rigid fixation of fractured zygoma after accurate reduction so as to maintain adequate stabilization against masticatory forces during fracture healing phase.

## KEY WORDS

Enophthalmos, fracture zygoma, malar height, malar projection, rigid internal fixation, vertical dystopia

The zygomatic bone is the principal buttress between the cranium and the maxilla. Its convex shape and protrusion makes it more vulnerable to fractures in facial trauma. Displaced zygomatic fractures can result in significant malar flattening, ocular dystopia and enophthalmos.<sup>[1]</sup> Thus, treatment of these fractures must achieve adequate and stable reduction at the fracture site. A number of clinical and experimental studies have found strong evidence of superiority and better long-term

fracture stability with the use of rigid plating system when compared with wire fixation in the treatment of zygomatic fractures.<sup>[2,3]</sup> However, the precise stability of the zygoma with reference to the number of fixation points as well as the sites of rigid fixation still remain a topic of debate.<sup>[4-6]</sup> A few experimental biophysical studies have been conducted to compare the stability of fractured zygoma after one, two and three-point fixation with mini plates. There has been no clinical study which compares the results of two-

point and three-point rigid plate fixation in patients with fractured zygoma. This study was conducted to address this particular aspect in the management of fractures of zygoma, so as to formulate an operative strategy that will achieve the surgical objective of stable fixation while minimizing the morbidity of the procedure.

## MATERIALS AND METHODS

The study was conducted at Department of Plastic Surgery, Postgraduate Institute of Medical Education and Research, Chandigarh, a tertiary referral hospital between 1<sup>st</sup> January 2002 and 30<sup>th</sup> July, 2003. Patients with isolated zygomatic fractures reporting to the Plastic surgery emergency OPD between 1<sup>st</sup> January 2002 and 31<sup>st</sup> December, 2002 were included in the study provided they satisfied the following exclusion and inclusion criteria:

### Inclusion criteria

1. Displaced fracture of the zygomatic bone as evidenced on radiography (Waters and Caldwell view)
2. Presentation within 72h of injury

### Exclusion criteria

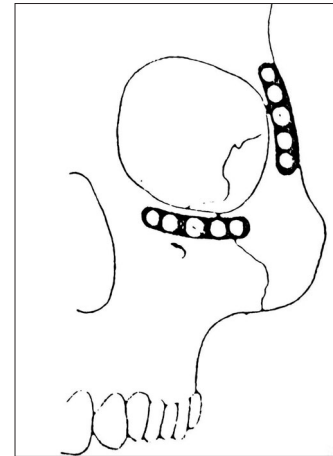
1. Associated fractures of other facial bones
2. Bilateral displaced fracture of zygoma
3. Associated injuries which are likely to delay early open reduction internal fixation of the zygomatic complex.

Informed consent was taken from all the patients before inclusion in the study. The study was also approved by Hospital Ethical Committee as it involved Open Reduction and Internal Fixation in accordance with standard treatment protocol being followed for fracture zygoma patients.

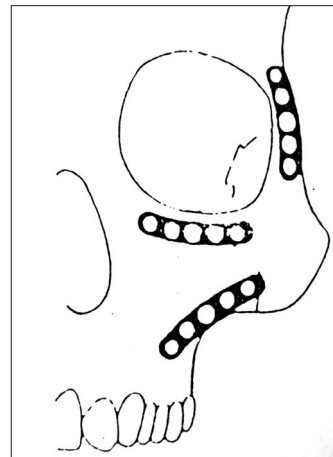
Clinical assessment included detailed history and physical examination of the patients. Visual acuity, extra-ocular movements and presence of diplopia were recorded. Stratification of patients was done using simple random sampling into following categories:

*Group I:* Patients to be treated with two-point fixation protocol (Fixation at fronto-zygomatic suture and inferior orbital rim) [Figure 1a].

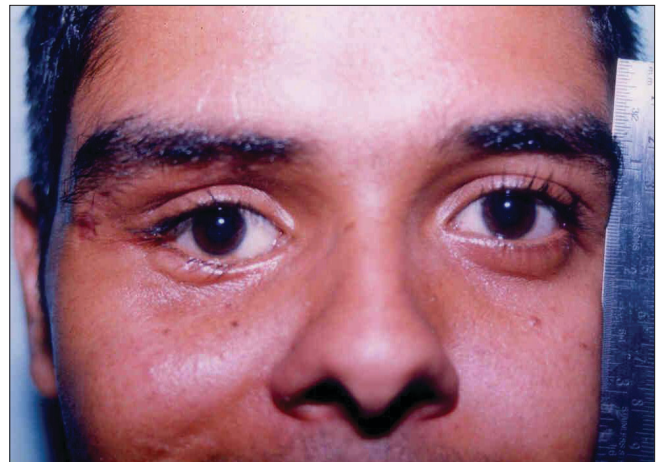
*Group II:* Patients to be treated with three-point fixation protocol (Fixation at fronto-zygomatic suture, inferior orbital rim and zygomatico-maxillary buttress) [Figure 1b].



**Figure 1a:** Two point fixation at Fronto-zygomatic suture and inferior orbital rim



**Figure 1b:** Three point fixation at Fronto-zygomatic suture, inferior orbital rim and zygomaticomaxillary buttress



**Figure 2:** Measurement of vertical dystopia

Computed tomography (CT) (axial and coronal) of midface was done to assess degree of displacement of the zygomatic bone. Numerical scoring of fracture zygoma (Cooter and David)<sup>[7]</sup> was done to document overall bony disruption among the two groups.

Operative management of these patients included open reduction and internal fixation with non compression titanium mini plates. All patients were operated under general anaesthesia. Exposure of the zygomatic bone was achieved with lateral brow incision, subciliary incision and upper gingivo buccal sulcus incision. The extent of exposure was the same irrespective of the number of fixation points. After ensuring reduction and satisfactory alignment at all three fracture sites, mini plates were applied at two points (fronto-zygomatic suture and inferior orbital rim) in Group I patients and at three points (fronto-zygomatic suture, inferior orbital rim and zygomatico-maxillary buttress) in Group II patients. Wounds were closed in two layers after thorough irrigation. Patients were kept on weekly follow-up for the first two weeks and on monthly follow-up thereafter.

After completion of three months patients were reassessed so as to record following parameters:

### Clinical functional assessment

1. *Vertical dystopia*: It was measured using photograph of the patient holding a centimetre ruler vertically within the same field. Level of the horizontal mid-pupillary line was recorded for each side to find out the discrepancy [Figure 2].
2. *Enophthalmos*: It was measured with Hertel exophthalmometry and compared with the opposite normal side.

### Aesthetic (photographic) assessment

Frontal and basal views of the patients at three-monthly follow-up visits were assessed for malar depression and globe abnormalities by an experienced independent clinical investigator who was blinded to the type of fixation method used and results of other clinical parameters assessed. Grading of malar asymmetry was done according to the classification system proposed by Holmes and Mathews.<sup>[8]</sup> Each patient was assigned to one of the following grades [Figures 3a, b and c].

*Grade I*: Excellent cosmetic result, no malar asymmetry

*Grade II*: Good cosmetic result, malar asymmetry on careful inspection

*Grade III*: Poor cosmetic result, noticeable malar asymmetry

*Grade IV*: Gross malar asymmetry.

Globe abnormalities (dystopia and enophthalmos) were also recorded by the same investigator.

### Radiological assessment

Post reduction displacement of zygoma was assessed radiologically for all the patients. CT scan of the midface was performed after three months of surgical rigid fixation. Zygomatic complex projection and zygomatic complex height (Furst *et al*)<sup>[9]</sup> were measured as follows:

1. *Zygomatic complex projection*: It was assessed using axial section of the complex. Anterior and posterior zygomatic complex width was recorded followed by measuring the distance between these two points (Dimension 'a' in Figure 4) Similar measurement was repeated on the contralateral normal side and any deficit recorded.
2. *Zygomatic complex height*: It required coronal section of zygomatico-maxillary complex. The distance between the horizontal reference line and the point at the most lateral aspect of curved surface of the complex was recorded (Dimension b' in Figure 5). Same dimension on the contralateral normal side was recorded to find out deficit in the height.

All the above data was tabulated and analyzed statistically. Unpaired 't'-test was used for quantitative data and Fischer's exact test was used for qualitative data.

### RESULTS

A total of 22 patients were included in the study. Twenty-one were males and one female with mean age of 28.45 years. The mode of injury was road traffic accident in 21 patients and fall from height in one patient. The average time lag between trauma and presentation was 1.18 days. The most common inspection finding was periorbital oedema (90.9%). Infra orbital sensations were diminished in 12 (68.18%) patients. The distribution of various signs and symptoms is shown in Figure 6. The numerical zygomatic score varied from 3 to 5 with mean of 4.63.

Twelve patients were treated with two-point fixation protocol and 10 patients were treated with three-point fixation protocol. Three patients developed infection at plating site. One patient belonged to Group II and two patients belonged to Group I. Location was zygomatico-frontal suture in all the patients and they responded to conservative treatment without the need for miniplate removal. Eighteen (81.81%) patients completed the three-month follow-up.

### Group I patients

*Clinical functional assessment*: Ten (out of the initial

twelve) patients reported for assessment at completion of three months. Vertical dystopia in this group ranged from 1mm to 3.5 mm with mean of 2.05 mm (SD 0.89). Enophthalmos ranged from 1 mm to 4 mm with mean of 2.4 mm (SD 0.96).

*Aesthetic (photographic) evaluation:* Seven patients (70%) had Grade II malar asymmetry and three (30%) had Grade III malar asymmetry. Seven patients had enophthalmos and five patients had dystopia appreciable on photographic evaluation.

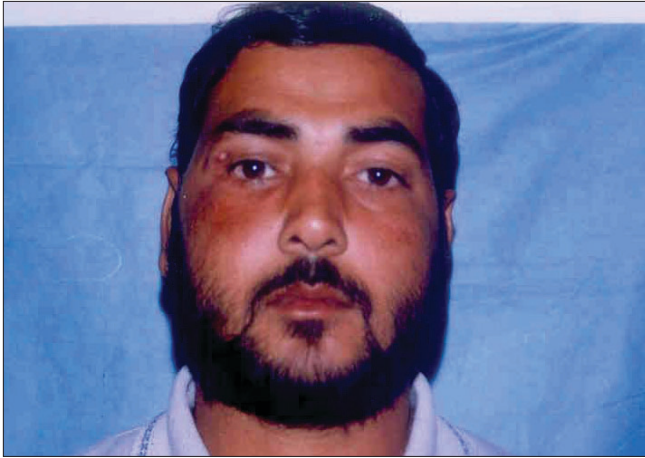

Figure 3a: Normal malar symmetry (Grade I)

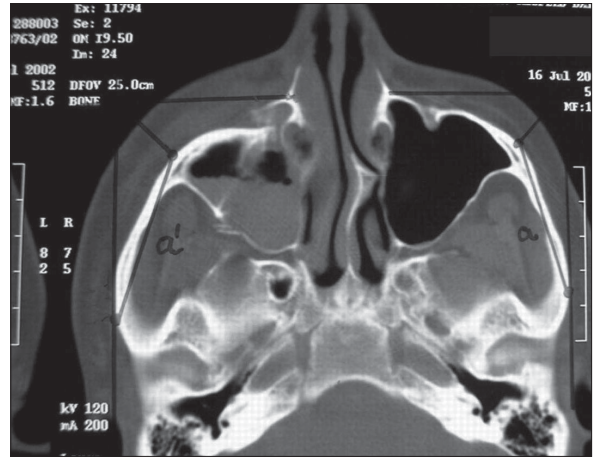


Figure 4: Zygomatic complex projection (Dimension 'a')

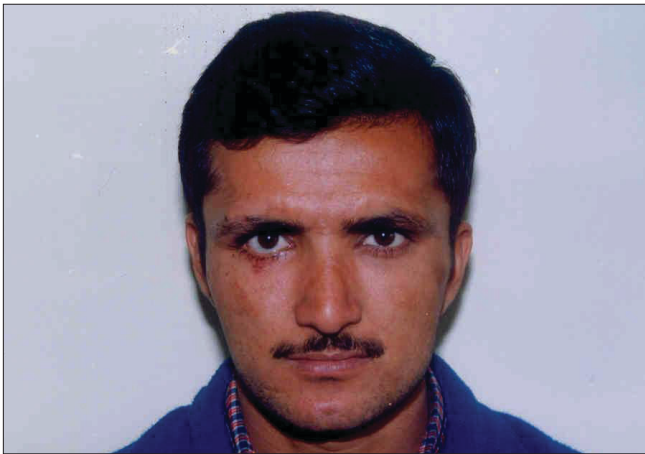


Figure 3b: Malar asymmetry on careful observation (Grade II)

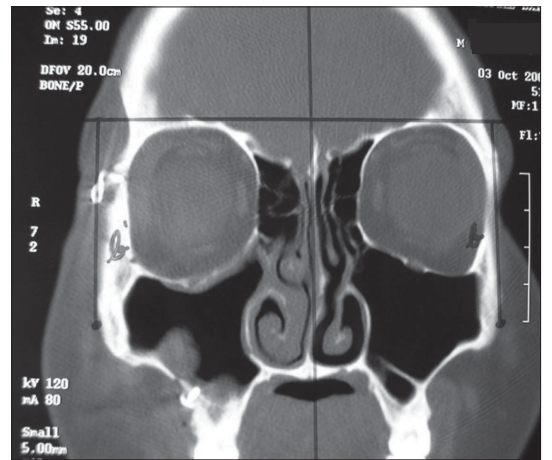


Figure 5: Zygomatic complex height (Dimension 'b')

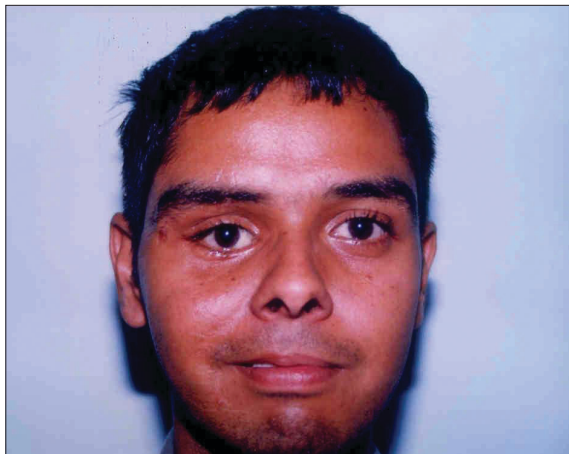


Figure 3c: Obvious malar asymmetry (Grade III)

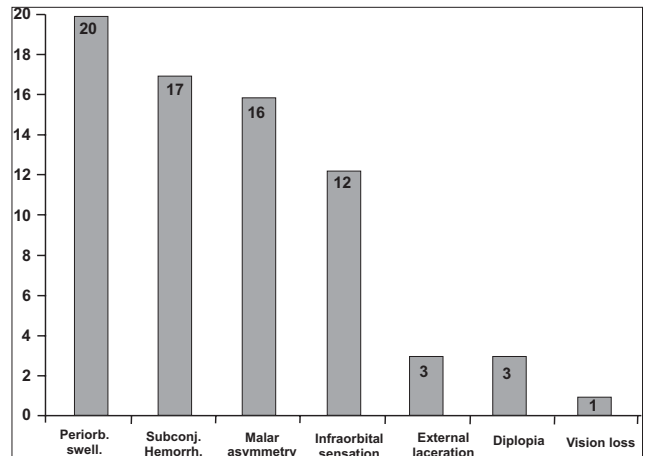


Figure 6: Distribution of signs and symptoms



**Radiographic evaluation:** Both malar projection and malar height were measured. The deficit in malar projection ranged from 2 mm to 6 mm with mean of 3.5 mm (SD1.35). The deficit in malar height ranged from 1.6 mm to 6.8 mm with mean of 3.74 mm (SD 1.76).

**Group II patients**

**Clinical functional assessment:** Eight patients (out of initial ten) reported for assessment at completion of three months. Vertical dystopia in this group ranged from 0 mm to 2 mm with mean of 0.81 mm (SD 0.75). Enophthalmos ranged from 0 mm to 3 mm with mean of 1.12 mm (SD 0.99).

**Aesthetic (photographic) evaluation:** Five patients (62.5%) had Grade II malar asymmetry and three (37.5%) had Grade I malar asymmetry. Three patients had enophthalmos and two patients had dystopia appreciable on photographic evaluation.

**Radiographic evaluation:** Both malar projection and malar

height were measured. The deficit in malar projection ranged from 0 mm to 3 mm with mean of 1 mm (SD1.06). The deficit in malar height ranged from 0 mm to 4 mm with mean of 1.68 mm (SD 1.33).

**Comparison and statistical analysis of Group I and Group II patients**

**Sampling variables:** The mean age of Group I patients was 29.5 years and of Group II patients was 27.7 years. The difference between the two groups was not statistically significant. Mean zygomatic score (David and Cooter)<sup>[7]</sup> in Group I patients was 4.166 and of Group II patients was 4.5. The difference between the two groups was not statistically significant.

**Clinical parameters: Dystopia:** The mean vertical dystopia in Group I patients was 2.05 mm and in Group II patients was 0.81 mm. The difference between the two groups was highly statistically significant ( $P < 0.01$ ).

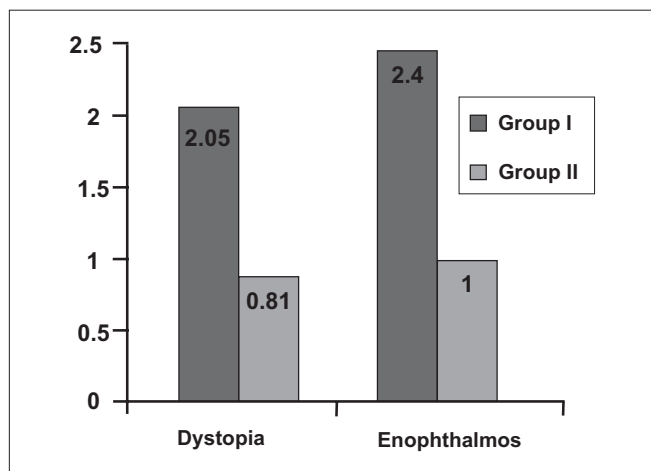
**Enophthalmos:** The mean enophthalmos in Group I patients was 2.4 mm and in Group II patients was 1 mm. The difference between the two groups was statistically significant ( $P < 0.02$ ). The findings are depicted in Figure 7.

**Aesthetic (photographic) evaluation:** In Group I seven patients (70%) had Grade II malar asymmetry and three (30%) had Grade III malar asymmetry. Among Group II patients five patients (62.5%) had Grade II malar asymmetry and three (37.5%) had Grade I malar asymmetry. The difference in the malar asymmetry profile of the two groups was not statistically significant ( $P > 0.1$ ).

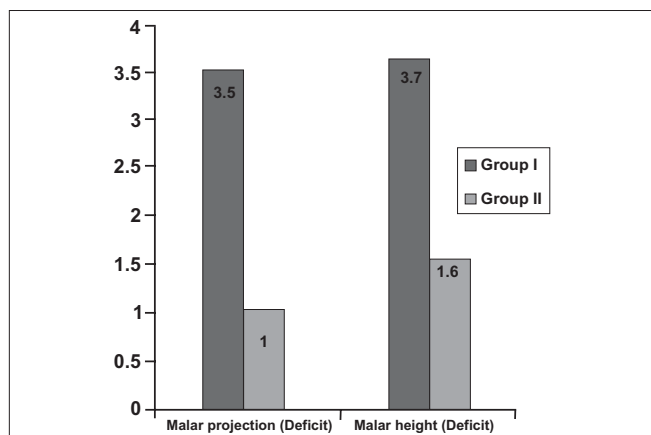
Seven patients (70%) in Group I and four patients (50%) in Group II had photographically obvious globe position abnormalities in the form of dystopia or enophthalmos. However, this finding was not statistically significant owing to small sample size (Fisher Exact Test,  $P > 0.1$ ).

**Radiological evaluation:** The mean deficit in malar projection in Group I patients was 3.5 mm (S.D. 1.35) and in Group II patients was 1 mm (S.D. 1.06). The difference was highly statistically significant ( $t = 4.26, P < 0.001$ ).

The mean deficit in malar height in Group I patients was 3.74 mm (S.D. 1.76), while this parameter in Group II patients was 1.68 mm (S.D. 1.33). The difference between the two groups was statistically significant ( $t = 2.73, P < 0.02$ ). The findings are depicted in Figure 8.



**Figure 7:** Comparison of clinical functional outcome among two groups



**Figure 8:** Comparison of deficit in radiological parameters among the two groups

## DISCUSSION

The zygomatic bone has pyramidal shape with frontal, maxillary, temporal and orbital processes articulating with corresponding bones. Displaced zygoma fractures are vulnerable to secondary malposition as a result of masticatory forces even after some kind of fixation.<sup>[10]</sup> These forces must be overcome at fracture sites for optimal stabilization.<sup>[11]</sup> Any post-reduction displacement of zygoma can result in delayed development of malar asymmetry, dystopia and enophthalmos. Therefore the goal of treatment of zygomatic fractures is to restore and maintain pre-injury facial skeletal configuration.

The biomechanics of the facial skeleton were investigated and discussed by Rudderman and Mullen.<sup>[12]</sup> According to them, fractured zygomatic segment has six possible directions of motion: translation across x, y and z axis; rotation about x, y and z axis. A miniplate applied across the fronto-zygomatic suture will resist translatory movement and also rotation along an axis perpendicular to the plane of miniplate because of the width of the plate. At the same time, it will offer little resistance to rotation along the linear axis of the plate. To improve stabilization, an additional plate is to be applied in a manner where the weak axis of both plates does not coincide with a line connecting them. A still more favorable situation can be created by choosing three fixation points that are not collinear. According to Pearl,<sup>[13]</sup> it is essential to reposition the zygoma at a minimum of three locations to achieve correction in three dimensions. He further opined that reduction at the fronto-zygomatic suture and inferior orbital rim can still leave persistent lateral rotation in the region of the anterior maxillary buttress leading to intra-orbital volume expansion behind the axis of globe.

Many experimental biophysical studies have been conducted to find out post-reduction rotational stability of zygoma fracture after miniplate fixation. Davidson *et al*<sup>[1]</sup> analyzed different combinations of miniplate fixation for stabilizing fractured zygoma in human skulls. This experimental study found that three-point fixation at fronto-zygomatic suture; inferior orbital rim and zygomatico-maxillary buttress conferred maximum stability against forces matching physiological stresses. Similar results were found by O'Hara *et al*<sup>[14]</sup> in another experimental biophysical study. Despite these experimental studies, there were no prospective clinical studies analyzing the results of different fixation points. We have analyzed two commonly used fixation methods

in an attempt to define the most appropriate method.

Both the groups in our study were comparable in terms of age and extent of injury. Analysis of clinical parameters (dystopia and enophthalmos) revealed statistically significant variation among the two groups with the three-point fixation group (Group II) showing lesser postoperative displacement. Similarly, the deficit in the malar projection and malar height was more in the two-point fixation group. This finding was also statistically significant. The findings of photographic assessment also reveal better malar symmetry and less globe position abnormalities in the three-point fixation group. However, the difference in the two groups was not statistically significant. This could be due to the subjective nature of assessment as well as secondary to incomplete projection of actual bony deficits because of thickness of skin and subcutaneous tissue.

Despite these apparent advantages, three-point fixation is associated with more extensive periosteal stripping, extreme retraction of bone edges and requirement of expert assistance for application of miniplate across the zygomatico-maxillary buttress. In addition, longer operative time, presence of more hardware and increase in cost of surgery are some disadvantages of fixation across an additional point. However, there were no additional complications (intra-oral suture line dehiscence, plate exposure) noticed in Group II patients.

The analysis of these findings suggests that three-point fixation using mini plates provides better post reduction stability of zygomatic fractures against normal physiological tractive forces. It is associated with lesser incidence of vertical dystopia and enophthalmos while providing better malar projection and height.

## CONCLUSION

Assessment of objective post fixation variables, viz. vertical dystopia, enophthalmos, malar projection and malar height show statistically significant enhancement in outcome attesting to better inherent stability of three-point fixation. Subjective assessment of aesthetic sequelae shows better results with three-point fixation though they do not achieve statistical significance in the present study, this could be because of the sample size of this study. We recommend three-point fixation with mini plates for management of displaced zygomatic fractures.

## REFERENCES

1. Davidson J, Nickerson D, Nickerson B. Zygomatic fractures: Comparison of methods of internal fixation. *Plast Reconstr Surg* 1990;86:25-32.
2. Hoster W. Experience with functionally stable plate osteosynthesis after forward displacement of upper jaw. *J Maxillofac Surg* 1980;8:176-81.
3. Schilli W, Ewers R, Niederdellmann H. Bone fixation with screws and plates in maxillofacial region. *Int J Oral Surg* 1981;10: 329-35.
4. Ellis E 3<sup>rd</sup>, Kittidumkerng W. Analysis of treatment for isolated zygomaticomaxillary complex fractures. *J Oral Maxillofac Surg* 1996;54:386-92.
5. Zachariades N, Mezitis M, Anagnostopoulos D. Changing trends in treatment of zygomaticomaxillary complex fractures: A 12-year evaluation of methods used. *J Oral Maxillofac Surg* 1998;56:1152-6.
6. Fonsceca RJ. Discussion-Changing trends in treatment of zygomaticomaxillary complex fractures: A 12-year evaluation of methods used. *J. Oral Maxillofac Surg* 1998;56:1156-7.
7. Cooter RD, David DJ. Computer based coding of fractures in craniofacial region. *Br J Plast Surg* 1989;42:17-26.
8. Holmes KD, Matthews BL. Three-point alignment of zygoma fractures with miniplate fixation. *Arch Otolaryngol Head Neck Surg* 1989;115:961-3.
9. Furst IM, Austin P, Pharaoh M, *et al.* The use of Computed Tomography to define zygomatic complex position. *J Oral Maxillofac Surg* 2001;59:647-54.
10. Manson PN, Crawley WA, Yaremchuk MJ, *et al.* Midface fractures: Advantages of immediate extended open reduction and bone grafting. *Plast Reconstr Surg* 1985;76:1-9.
11. Rohrich RJ, Hollier LH, Watumull D. Optimizing the management of orbitozygomatic fractures. *Clin Plast Surg* 1992;19:149-65.
12. Rudderman RH, Mullen RL. Biomechanics of facial skeleton. *Clin Plast Surg* 1992;19:11-29.
13. Pearl RM. Treatment of enophthalmos. *Clin Plast Surg* 1992;19:99-111.
14. O'Hara DE, Delvecchio DA, Bartlett SP, *et al.* The role of microfixation in malar fractures: A quantitative biophysical study. *Plast Reconstr Surg* 1996;97:345-53.

**Source of Support:** Nil, **Conflict of Interest:** None declared.

## Announcement

This ISAPS and EURAPS endorsed international Facial Plastic Surgery Meeting with live surgery is to be held in Gent, Belgium on September 21-23, 2007.

For details on faculty, program and hotels, please visit the website: [www.CATFAS.be](http://www.CATFAS.be)

Dr. Patrick Tonnard & Dr. Alexis Verpaele  
Coupure Centrum voor Plastische Chirurgie  
Coupure Rechts 164 C-D  
B-9000 Gent

Belgium

Tel: +32/9 269 94 94

Fax: +32/9 269 94 95

E-mail: [seminars@coupurecentrum.be](mailto:seminars@coupurecentrum.be)

web: [www.coupurecentrum.be](http://www.coupurecentrum.be)