

Original Article

Early experience with the use of prosthetic mesh as fascia replacement in structural abdominal wall reconstruction

I. A. Adigun¹, J. K. Olabanji², A. O. Oladele², O. O. Lawal², G. H. Alabi³

¹Plastic Surgery Unit, Department of Surgery, University of Ilorin, Ilorin, Nigeria, ²Department of Surgery, Obafemi Awolowo University, Ile-Ife, Nigeria, ³Department of Surgery, Obafemi Awolowo University Teaching Hospitals Complex, Ile-Ife, Nigeria

Address for correspondence: Dr A O Oladele, Plastic Surgery Unit, Department of Surgery, Obafemi Awolowo University, Ile-Ife, Nigeria.
E-mail: ayodejiolarewaju@yahoo.com

ABSTRACT

Background: Abdominal wall defects occur from various causes and require reconstruction. Autogenous tissue is often insufficient and incisional hernia often results. Prosthetic mesh is a proven substitute to autogenous tissue but reports on its use is uncommon in our practice environment. **Aim:** The aim is to report our early experience with the use of prosthetic mesh in black patients in our practice environment. **Materials and Methods:** The summaries of three patients with anterior abdominal wall defects which were managed with the use of a prosthetic mesh are presented as well as their intraoperative and postoperative photographs. One patient had intraperitoneal placement of the mesh and developed no complications. **Results:** One patient who had bowel resection developed a postoperative enterocutaneous fistula away from the site of the mesh and was managed conservatively. Other patients had no complications. **Conclusions:** The use of prosthetic mesh is recommended.

KEY WORDS

Abdominal wall, mesh, reconstruction

The abdominal wall provides protection for the abdominal viscera and serves as the centre of balance in the erect position. It is, however, prone to defects from various causes which impair its performance of these roles. Defects in the abdominal wall could be partial or total and can arise from congenital and acquired causes. The congenital causes are exemplified by omphalocele, gastroschisis, prune belly syndrome and pentalogy of Cantrell. The acquired causes can arise from trauma, infections and systemic diseases or from ventral hernias. When the abdominal wall defects are very large, they usually cannot be closed by the patients' own tissues and attempts at forceful closure of the fascia causes excessive tension and is almost invariably followed by dehiscence, thus the need for tissue to bridge the gap and ensure tension-free repair.^[1]

Earlier surgeons have used fascia lata for the repair of hernia and other abdominal wall defects.^[1] Lateral and posteriorly based composite flap of the external oblique muscle, anterior rectus fascia and the overlying skin which have a limited arc of rotation have been used to repair defects of the upper or lower abdominal wall.^[2]

The use of prosthetic mesh in structural abdominal wall reconstruction provides a viable option. This dates back to 1900 with the use of silver wire.^[3] Since then many other prosthetic materials such as nylon[®], dacron[®], polypropylene, silastic and polytetrafluoroethylene have been used.^[4-6]

The use of prosthetic materials has not been common in our practice environment; consequently there is paucity of information on its use. Nonavailability, high cost of

procurement and possibly low level of awareness among surgeons may account in part for this.

We report the use of prosthetic mesh as fascia replacement in large abdominal wall defects in three of our patients. The challenges of managing these patients and the potential complications that may ensue are also discussed.

MATERIALS AND METHODS

Over a 12-month period, anterior abdominal wall reconstruction was performed on three patients who had extensive fascial defects, using mersilene® mesh. All surgeries were performed under general anaesthesia with endotracheal intubation and muscle relaxation. Two patients had post excision defects for recurrent trunk fibromas. One had a congenital anterior abdominal wall defect for which a previous attempt at surgery had failed.

The summary of their cases and their photographs are presented.

Case 1

A 29-year-old man presented with an irreducible anterior abdominal wall protrusion in the left periumbilical area from birth. He also had bilateral undescended testes for which orchidopexy was done at six years of age. An earlier attempt at repair of the abdominal wall defect when he was five years old led to a recurrence three months after surgery. The mass had increased progressively in size and was associated with sporadic episodes of colicky abdominal pain, abdominal distension and vomiting that resolved with conservative management.

Examination revealed a healthy young man with normal vital signs.

He had an irreducible anterior abdominal wall hernia measuring 25 × 10 × 8 cm located in the periumbilical and left lumbar region. It had an overlying scar and had visible peristalsis in it. The neck of the defect was 15 × 8 cm. The abdomen was rather hypoplastic with most of the contents lying in the sac [Figure 1].

A diagnosis of congenital anterior abdominal wall defect with failed attempt at repair was made. He had surgical exploration and findings at surgery included, about 70% of the bowel residing in the hernia sac

outside the abdominal cavity, intestinal malrotation and Ladd's bands as well a floating ascending colon. A right hemicolectomy with ileotransverse anastomosis was performed to reduce the bowel mass. An onlay mesh prosthetic replacement of the fascia defect was done and skin closure achieved with local skin flaps [Figures 2 and 3].

Postoperatively, he developed an enterocutaneous fistula away from the site of the mesh repair, which was managed conservatively [Figures 4 and 5].

Case 2

A 20-year-old secondary school student presented with two months history of recurrent right-sided anterior abdominal wall swelling. The initial swelling had been excised five years before and the current swelling arose on the previous scar. There was no histopathology report of the first excised specimen. The swelling was initially painless but later developed dull intermittent aching pain with progressive increase in size. There was neither associated fever nor difficulty in breathing. No bowel or urinary symptoms and no history of similar swelling in the family. There was no history of smoking and alcohol consumption.

Examination revealed a young man with normal vital signs. Abdominal examination revealed a right hypochondrial mass measuring 6 × 10 cm, tender and fixed to the seventh and eighth ribs as shown in Figure 6.

He was scheduled for surgical extirpation. Intraoperative findings were a tumour attached to the seventh and eighth ribs but sparing the pleura. The tumour was resected along with the adjoining ribs [Figure 7]. An inlay of mersilene mesh was sutured into the defects and skin flaps advanced to close the overlying skin defect as shown in Figures 8 and 9. The late postoperative pictures are shown in Figures 10 and 11.

Case 3

A 39-year-old woman presented with four-year history of recurrent anterior abdominal wall mass in the epigastric region. She had a similar mass excised a year before the onset and histopathology diagnosed a fibroma. The mass increased slowly in size and became painful and ulcerated four months prior to presentation, was associated with a sero purulent discharge, weight loss and anorexia.

Examination revealed a wasted patient, pale, anicteric,

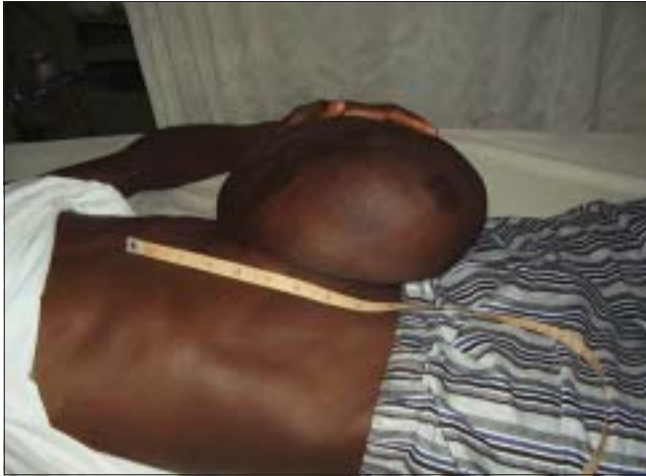

Figure 1: Preoperative photo of Case 1

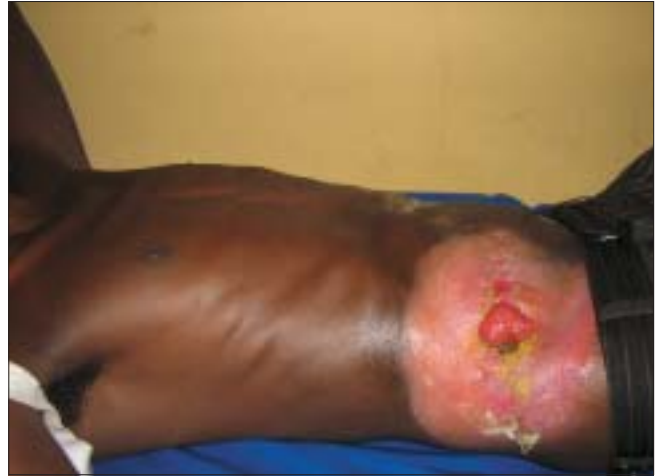

Figure 4: Late post operative photo of case 1

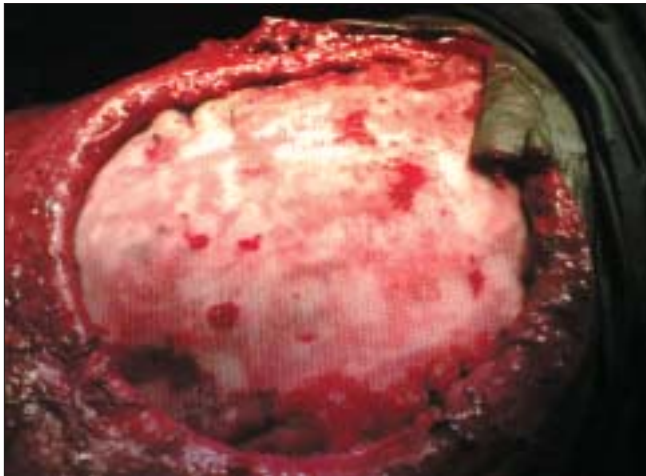


Figure 2: Mesh *in situ* intraoperatively Case 1

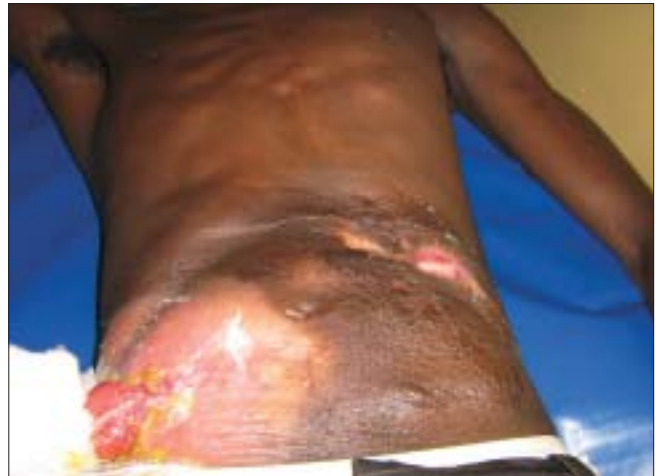

Figure 5: Late post operative picture of case 1

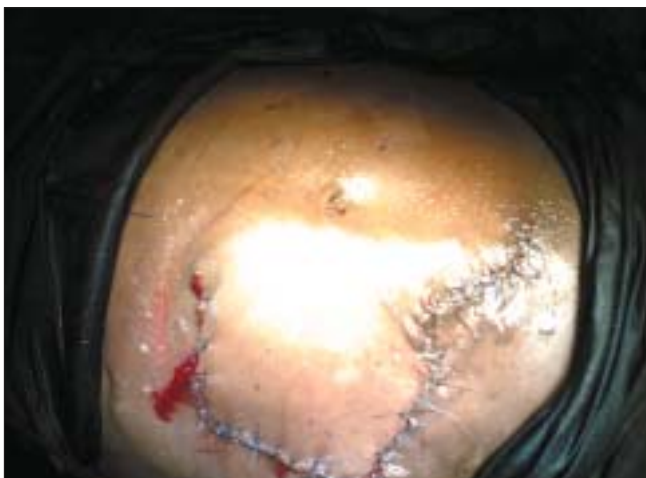

Figure 3: Immediate post operative photo of case 1

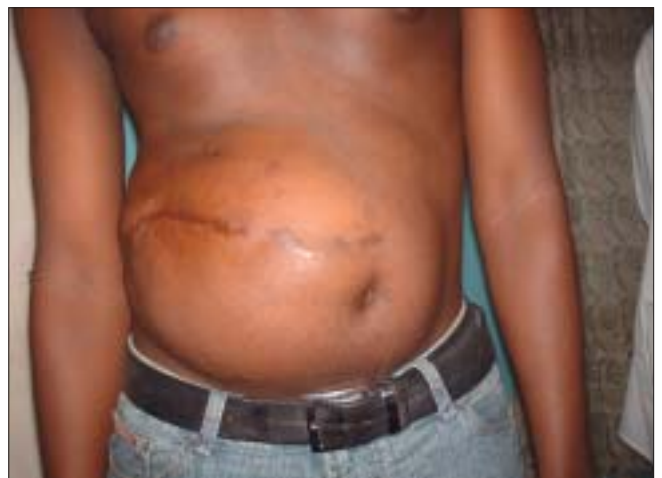

Figure 6: Preoperative photo of case 2

well-hydrated and no significant peripheral lymph node enlargement. The abdominal examination revealed an ulcerated nodular mass in the epigastric region on the

anterior abdominal wall measuring 25 × 10 cm and it was attached to the rectus abdominis muscle. There was no palpable organomegaly and no ascites.

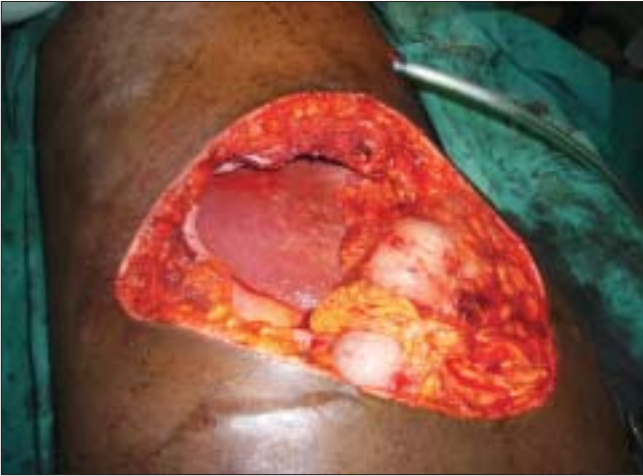

Figure 7: Intraoperative photo of case 2

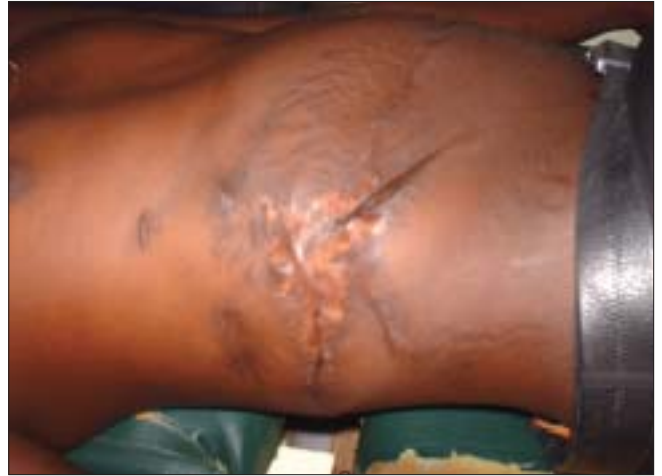

Figure 10: Late postoperative photo of Case 2

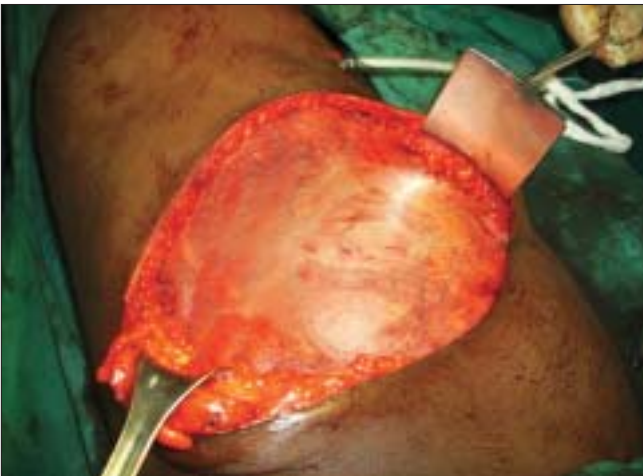

Figure 8: Mesh insitu case 2

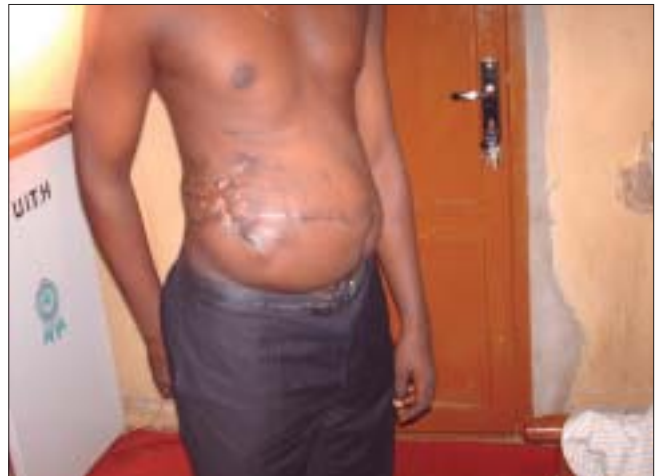

Figure 11: Late postoperative photo of Case 2 erect

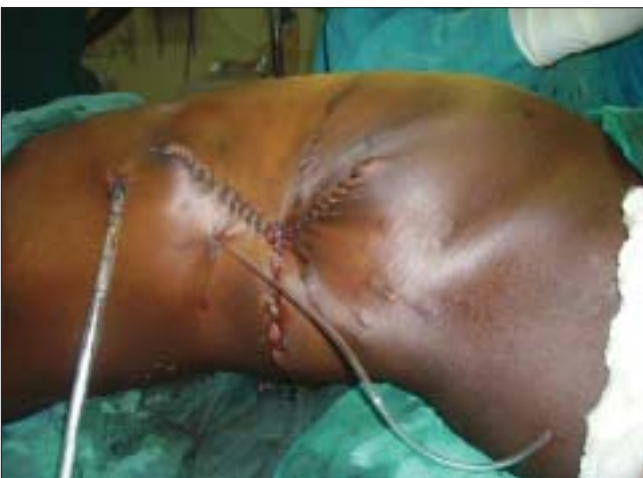

Figure 9: Immediate postoperative photo of Case 2

The patient had surgical resection leaving a defect 30 cm × 25 cm. This was repaired using mersilene mesh followed by skin coverage with local skin flaps.

DISCUSSION

The reconstructive goals in the repair of abdominal defects are to re-establish the structural integrity of the abdominal wall. The decision to use a particular technique is based on the patient's age, health status, the availability of adequate amounts of local tissue and the layers of the abdominal wall which have a defect. There is no single method of reconstruction of abdominal wall defects that will suffice in all patients.^[7]

The use of prosthetic mesh replacement in the reconstruction of abdominal wall is a viable option in large post excision defects as in two of the cases presented but it is by no means limited to large defects alone. Its use in all patients requiring some form of reconstruction of the abdominal wall has been advocated.^[8-10]

The use of prosthetic mesh ensures a tension-free closure and thereby prevents increase in the intraabdominal pressure following abdominal wound closure, especially when there is tissue loss.^[11] When the patient's fitness for anaesthesia is suboptimal, the use of these meshes helps to avoid use of distant muscle or musculocutaneous flaps or other more extensive surgeries that prolong anaesthesia. The use of the latissimus dorsi musculocutaneous flap and tensor fascia lata can cover very large anterior abdominal wall defects. However, these procedures entail lots of tissue dissection and mobilization by well-trained reconstructive surgeons to achieve success and reduce operating time. They may also be complicated by flap necrosis. The use of prosthetic mesh also avoids donor site morbidity that invariably accompanies the use of autogenous flaps or fascia and the supply is unlimited.

The placement of the mesh is essential to successful repair. All biomaterials cause adhesion to intestines except for polypropylene mesh and silastic composites.^[4,12] Such an adhesion is the first stage of development of biomaterial-related intestinal fistula,^[4] therefore intraperitoneal placement of mesh is not recommended.^[13]

Some surgeons however believe that the technique of placement has no influence on the development of enterocutaneous fistula.^[14]

Extraperitoneal placement can either be between the peritoneum and the muscle^[15] or as an onlay. The body generates an intense inflammatory response to the mesh with fibroblastic ingrowth. This leads to scar plate formation, leading to increasing stiffness of the abdominal wall and shrinkage of the biomaterial.^[15,16]

In using prosthetic mesh, the mesh may be applied and granulation tissue left to growing over it, following which a split-thickness skin graft is applied. The mesh may also be overlaid with omentum and an immediate split-thickness skin graft applied.^[17,18]

With the mesh *in situ* postoperative monitoring can be done with the use of ultrasonography or CT scans.^[19] These enable early detection of collections around the mesh.

Some complications may arise from the use of mesh such as extrusion, ulceration, recurrent herniation and development of fistula.^[20-22] In our environment where reconstructive surgeons are still very few in number the use of prosthetic mesh may be an advantage and a

better option in the management of very large anterior abdominal wall fascia defects. Even though it is expensive and not available freely now, we believe that with time when the demand increases it will become more readily available and affordable in our environment.

REFERENCES

1. Mayo WJ. Further experience with the vertical overlapping operation for the radical cure of umbilical hernia. *JAMA* 1903;41:225.
2. Hershey FB, Butcher HP. Repair of defects after partial resection of the abdominal wall. *Am J Surg* 1964;107:586-90.
3. Aston SJ, Pickrell KL. Reconstructive surgery of the abdominal wall. In: Converse JM, editor. *reconstructive plastic surgery*. Vol 7 Philadelphia; 1977.
4. Amid PK, Shulman AG, Lichtenstein IL, Sostrin S, Young J, Hakakha M. Experimental evaluation of a new composite mesh with the selective property of incorporation to the abdominal wall without adhering to the intestines. *J Biomed Mater Res* 1994;28:373-5.
5. Liakakos T, Karanikas I, Panagiotidis H, Dendrinou S. Use of Marlex mesh in the repair of recurrent incisional hernia. *Br J Surg* 1994;81:248-9.
6. Amid PK, Shulman AG, Lichtenstein IL, Hakakha M. Biomaterials for abdominal wall hernia surgery and principles of their applications. *Langenbecks Arch Chir* 1994;379:168-71.
7. Joel CS, Vanderveer AS, Newcomb WL, Lincourt AE, Polhill JL, Jacobs DG, *et al.* Abdominal wall reconstruction after temporary abdominal wall closure: A 10 year review. *Surg Innov* 2006;13:223-30.
8. Janes A, Cenigiz Y, Israelsson LA. Preventing parastomal hernia with a prosthetic mesh: A randomized study. *Arch Surg* 2004;139:1356-8.
9. Vrijland WW, Jeekel J. Prosthetic Mesh Repair Should Be used for any defect in the abdominal wall. *Curr Med Res Opin* 2003;19:1-3.
10. Luijendijk RW, Hop CW, van den Tol MP, de Lange DC, Braaksma MM, IJzermans JN, *et al.* A comparison of suture repair with mesh repair for incisional hernia. *N Engl J Med* 2000;343:392-8.
11. Voyles CR, Richardson JD, Bland KI, Tobin GR, Flint LM, Polk HC Jr. Emergency abdominal wall reconstruction with polypropylene mesh. *Ann Surg* 1981;194:219-23.
12. Vrijland WW, Jeekel J, Steverberg EW, *et al.* Intraperitoneal polypropylene mesh repair of incisional hernia is not associated with enterocutaneous fistula. *Br J Surg*. 2000;87:348-52.
13. Kaufman Z, Engelberg M, Zager M. Fecal fistula: A late complication of Marlex mesh repair. *Dis Colon Rectum* 1981;24:543-4.
14. Leber GE, Garb JL, Alexander AI, Reed WP. Long term complications associated with prosthetic repair of incisional hernia. *Arch Surg* 1998;133:378-82.
15. Wantz GE. Incisional hernioplasty with mersilene. *Surg Gynecol Obstet* 1991;172:129-37.
16. Cobb WS, Kercher KW, Heniford BT. The argument for lightweight polypropylene mesh in hernia repair. *Surg Innov* 2005;12:63-9.
17. Barret BM, Millard DR Jr, Rilly WB Jr. Treatment of full thickness abdominal and chest losses with split thickness skin grafting. *Arch Surg* 1977;112:217-9.
18. Beveraggi EM, Bonades G, Santibanes E. Use of polypropylene mesh in surgical abdominal emergencies. *Plast Reconstr Surg*

1982;70:282.

19. Parra JA, Revuelta S, Gallego T, Bueno J, Berrio JI, Fariñas MC. Prosthetic mesh used for inguinal and ventral hernia repair: normal appearance and complication in Ultrasound and CT. *Br J Radiol* 2004;77:261-5.
20. Calderon W, Chang N, Mathes SJ. Comparison of the effect of bacterial inoculation in musculocutaneous and fasciocutaneous flaps. *Plast Reconstr Surg* 1986;77:785-94.
21. Mathes SJ, Stone HH. Acute traumatic losses of abdominal wall substance. *J Trauma* 1975;15:386-91.
22. Molloy RG, Moran KT, Waldron RP, Brady MP, Kirwan WO. Massive incisional hernia: Abdominal wall replacement with marlex mesh. *Br J Surg* 1991;78:242-4.

Support: No grant or funding was made available for this work by any organization.

Author Help: Choosing an appropriate category of article for faster publication

The manuscript system (www.journalonweb.com) allows the authors to check a likely publication date for a newly submitted article. Based on number of articles in review, number of accepted articles and acceptance rate, the system estimates the likely publication date for an article submitted on a given date.

If there are too many articles in a category e.g., case report, a newly submitted case report if accepted may have to wait for a long period before publication. Hence, the author can check other categories e.g. letter to editor or images, for such paper and submit to another category of articles.