

CME

Reconstruction of nose in leprosy

S. Husain

Department of Plastic and Reconstructive Surgery, National JALMA Institute of Leprosy, Taj Ganj, Agra - 282 001, UP, India

Address for correspondence: S. Husain, Department of Plastic and Reconstructive surgery, National JALMA Institute of Leprosy, Taj Ganj, Agra - 282 001, U.P. India. E-mail shusain@mail.com

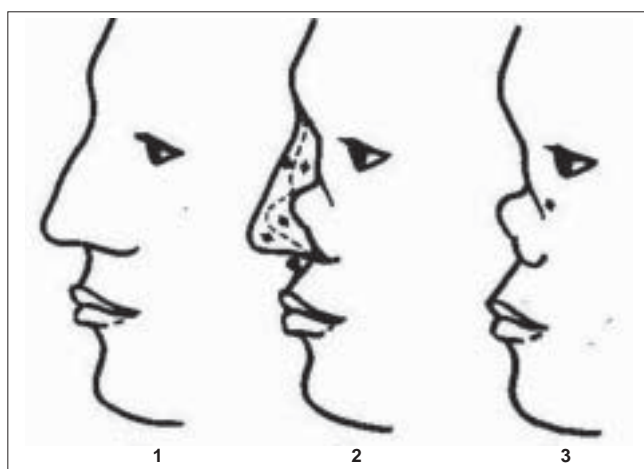
The stigma of leprosy is due to the sinister connotation attached to visible deformities. The deformities of the face are the most visible from all other deformities that occur in leprosy. The face is also the most common site of deformity.^[1] The reconstruction of face is therefore one of the major challenges facing the reconstructive surgeon for leprosy. This article discusses the causes and treatment of nasal deformity.

PATHOANATOMY

The collapsed nose is a typical residual deformity of lepromatous leprosy. This occurs due to the direct infiltration of bacteria into the mucous membrane, followed by cellular infiltration, edema and thickening of the mucous membrane. The involved mucosa is subject to secondary infections with subsequent ulceration, in which the exposed cartilage and nasal bone undergo necrosis due to secondary infection and loss of blood supply.

The destruction of cartilage and bone starts in the septum and turbinate, which are covered on both sides with the mucous membrane. The lateral cartilages and nasal bones having mucosal lining on one side only are the next to undergo destruction. The tip of the nose (alar cartilage and columella) is hardly affected because it is covered on both surfaces with skin. The alae often become folded because of scar contractures in the adjacent mucous lining [Figures 1-3].

The scar contracture of mucosal lining, collapse of cartilaginous framework in the mid part of the nose and the destruction of nasal bone and maxillary spine leads to a depressed nose deformity in leprosy. A large perforation



Figures 1-3: (1) Normal nose. (2) Destruction of mucosal lining due bacterial infiltration. (3) Depressed nose

in the nasal septum and loss of turbinates result in a large common cavity in the interior of the nose.

PRINCIPLES OF REPAIR

The basic procedures aim in achieving the following:

1. To provide new lining for the nose
2. To provide a new support for the bridge of the nose and the columella
3. To fill in the space at the upper end of nose in front of the nasal bones

To provide new lining for the nose: We use free skin grafts or local nasolabial flaps to provide the new lining. Distant flaps are not advised for lining as they are very thick and can obstruct the airway.

The restoration of new support: It poses the same problems as in total nose reconstruction. Methods and

materials depend on the choice of lining if a split skin graft is used for lining; secondary bone grafting is always difficult due to problems in finding a space in between the lining and the cover. The combined bone grafting and skin grafting seems to be safe if a very thin bone graft is used; however, the risk of failure is higher using autograft after split skin grafting.

For the shape of bone graft, the cantilever principle, as proposed by Antia,^[2] has the advantage of avoiding the columellar strut. Antia devised a spearhead-shaped graft taken from the olecranon and fixed it to the nasal bones by using a wire. The angle of the short oblique plane at the base of the graft has to be selected carefully in order to obtain the correct lift to the cantilever.

TYPES OF OPERATIONS FOR NASAL RESTORATIONS

1. Simple bone cartilage graft
2. Postnasal skin graft inlay by Gilles
 - (A) With permanent removable prosthesis
 - (B) With secondary bone grafting
3. Crockett's operation
4. Farina's nasolabial or frontal flaps with primary or secondary bone grafting

SIMPLE BONE OR CARTILAGE GRAFT^[3] (BRAND, 1959)

This is indicated in moderately depressed noses where the mucus membrane destruction is not extensive and loss of septum is restricted to the dorsal line alone. The graft can be taken from the iliac crest or the eighth rib and introduced through the columella or in a retrograde manner. An L-shaped graft is used when columellar support is required.

Husain *et al.*^[4] modified this procedure. Taking the graft from iliac crest or the eighth rib was a complicated procedure. They successfully used the second metatarsal bone graft without much morbidity to the donor site. This is a total cortical bone graft, which is stronger than the pure cartilage grafts.

POSTNASAL SKIN GRAFT INLAY^[5] (GILLES, 1923)

This is the most commonly used procedure. Most of

the cases of nasal collapse occur when the nose is fully developed and the skin and nasal tip are present almost in toto. They are freed from the attachments to the bony margins and the raw area representing the destroyed mucous membrane lining is covered with the split skin graft carried on a mould. The mould is retained as a dilator until the graft ceases to contract. Support is then provided in the form of bone graft or prosthesis.

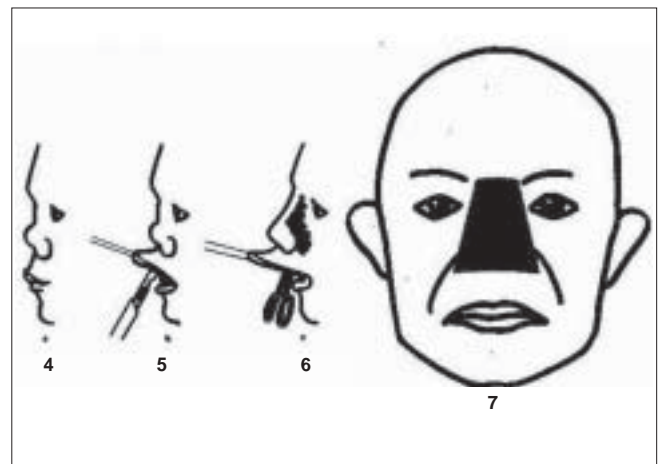
Preoperative care: It starts two weeks prior to surgery. Careful dental toilet is essential; cleaning of the nasal cavity with 1% cetramide is performed twice daily.

Anesthesia: General anesthesia by oral endotracheal tube and a throat pack or local infiltration anesthesia with 2% lignocaine with adrenaline 1:80000 can be used.


Procedure: An incision is made horizontally in the upper labial sulcus, slightly wider than the width of the nostril. From the incision, the knife is made to enter the common nasal cavity and it is allowed to move near to the margin of the piriform aperture. In some cases, the septum is dissected in the plane of piriform aperture.

The soft tissues are detached from nasal bone leaving the periosteum attached. In this plane, the bleeding is minimal. We have to undermine the midline up to the level of the eyebrows. The side edges converge slightly towards the root of the nose. The widest part of the cavity must be at the upper labial sulcus. This is to ensure that the prosthesis does not get trapped [Figures 4-10].

Gutta-percha (latex dental impression compound) or dental wax is used to make a mold of the cavity. It is



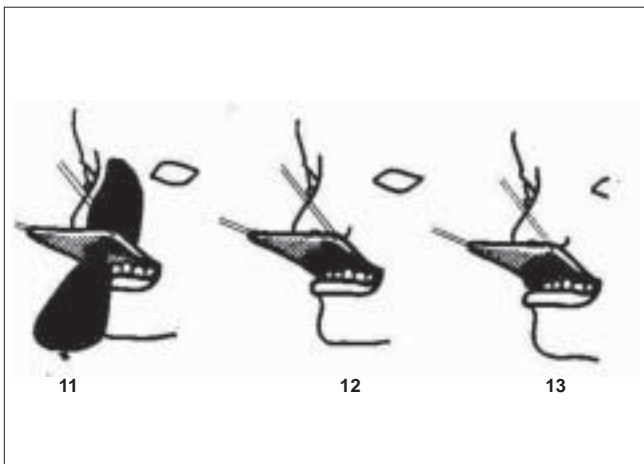
Figures 4-7: (4) Depressed nose. (5) Incision in the upper labial sulcus (6 and 7) Dissection in nasal cavity



Figures 8-10: Lifting of the skin over the nasal cavity (Exposure of the nasal cavity)

softened in warm water (50°C) and then moulded into a slightly flattened pear-shaped mould. The mold is introduced into the cavity, and the desired shape of nose is achieved while the mould is still soft. The mold is then hardened by cooling with sterile chilled saline water. A steel wire loop is embedded in its lower end in the midline; an eyelet wire loop is anchored to the incisor teeth. When the mold is completely hardened and of required shape, it is withdrawn from the nasal cavity [Figures 11-13].

A medium thickness split skin graft is taken from the non-hairy part of the body. The mold is coated with mastic gum (Mastisol) glue and covered completely with the graft, taking care that the raw surface should be outwards. The mold is introduced in a newly dissected cavity. It is held in place by tying the wire loop on the mold to the eye let with a piece of thread. This is to prevent the extrusion



Figures 11-13: Use of Gatta dercha to make of mold of nasal cavity

of the mold that could happen from contracture of the split skin graft.

Postoperative care: The mold is removed for the first time after 5-7 days, and the cavity is cleaned with dilute hydrogen peroxide solution. The part of the graft that covers the airway both in the front and behind, i.e., just inside the nostrils and on the piriform aperture, respectively, is perforated and excised. Then, the mould is replaced back in the cavity. This procedure is repeated daily for a week. Two perforations are made around the tenth day through the mold to connect the airway to allow for free breathing.

After 2 weeks, patient is taught to remove and replace the mould by himself. He has to do it twice daily for cleaning after 6-9 months. When the skin graft has passed the phase of contracture, that mold is replaced by a permanent prosthesis.

The permanent prosthesis may be any one of the following:

- (A) a denture carrying an extension into the nasal cavity
- or
- (B) an acrylic mould to be worn without dental fixation

Cantilever retrograde bone graft with closure of oronasal fistula: As proposed by Antia, this must be in the form of the bone graft introduced along the dorsal line between the skin and new graft lining. In order to obtain a good shape, the graft must be broad at its base over the nasal bones and tapering over the tip. The normal columellar approach is not practical due to the difficulty in tunneling.

Operative details: Local infiltration anesthesia is used. A curved incision is made between the eyebrows and the nasal bone is exposed. The skin graft lining the postnasal cavity is detached at its upper part from the nasal bone and from the skin cover. Under the ridge of nose, a tunnel is made between the dorsal skin and the skin graft lining. A careful blunt dissection is necessary for this part. The tunnel must be sufficiently large to accommodate the bone graft without tension. The bone graft is introduced into the prepared tunnel. Two fine holes are transversely drilled through the nasal bone to hold the bone graft with 0.6 mm steel wire. The retrolabial opening into the postnasal cavity can be closed now by dissecting the skin graft from the labial mucosa and it is turned down to meet the free border

of the skin graft on the maxilla. The incision of upper labial sulcus is also closed by suturing.

Harvesting of the bone graft: The bone graft can be harvested from the olecranon through a curved incision below the elbow. The proximal subcutaneous part of the ulna is exposed, and a spearhead-shaped graft is removed. It is made up of the superficial layer of compact bone with the cancellous bone underneath. The graft is shaped according to the nasal cavity.

Postoperative care: After the wound has healed, the patient should be trained to clean the nasal cavity regularly.

COCKETT OPERATION

The operation was devised by Cockett⁽⁶⁾ when he was working at Mysore and Dichpalli in 1959. This is a one-stage procedure using the posterior nasal epithelial inlay and a bone graft for the bridge of nose and columella. The graft was obtained from the iliac crest. The additional innovation is the filling up of the space at the upper end of the nose in front of the nasal bone with minute chips of the cartilage obtained from the costal bone margin. This is considered to assist in the aesthetic result.

Procedure: The patient requires thorough dental toilet for a few weeks before the surgery.

Anesthesia: General anesthesia is better: 2% lignocaine with adrenaline must be used for infiltration while taking the iliac crest graft. A sand bag is placed behind the right buttock to elevate the iliac crest.

Taking a Bone graft: A 6 × 2.5 cm graft is taken from the inner table of the iliac crest with an osteotome, the bone is sectioned below the iliac crest, after the muscle insertion is reflected. The cancellous bone with the cortical surface is removed. 1/0 catgut suture is used to close the external periosteum along with its muscle insertions.

The cartilaginous graft is taken from the costal rib exposed by transverse incision. The perichondrium is incised and detached to expose two pieces of costal cartilage, each approximately 2-3 cm long, and placed in saline for later use.

Skin graft: A split skin graft 6 × 3 cm is taken from the thigh and placed in saline.

Freeing the nose: An incision is made in the nasolabial sulcus in front of the maxilla to leave sufficient mucosa posteriorly to hold the sutures. The nose is freed from its skeletal attachments as far up as the glabella and pulled out to its original shape. The attachments of the bridge of nose should be freed. The upper part of the perforated septum is divided as far superiorly as possible where it joins the nasal bone leaving a small portion attached anteriorly. The free nasal cavity is packed with adrenaline saline wet gauze to achieve hemostasis.

Preparation and insertion of cartilaginous graft: The cartilage is cut into match-stick-like strips that are cut across into tiny cubes, keeping the perichondrium intact.

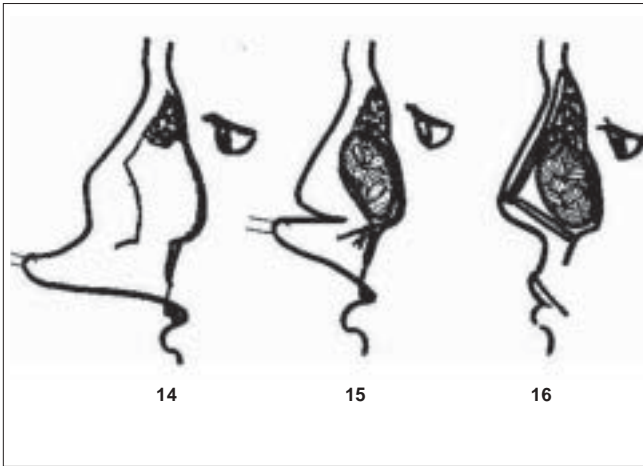
The skin graft is folded in half on itself to create a bag of skin lining the new raw area with the epithelial surface inside. The two sides are sewn up with a continuous fine suture leaving the end open. The gauze pack is removed from the nasal cavity, and the nose tip is held forward so that the nasal cavity becomes visible. The cartilage cubes are packed in the nose on the nasal bone. The skin bag is put into the lower part of the postnasal space with its open end towards the nostrils. The skin graft that is slightly bigger in size should be taken so that it can fill the nasal cavity, thereby leading the nose to assume the desired shape. The free edges of open end of skin bag are folded over one another; the nasolabial sulcus incision is closed with catgut.

Preparation and insertion of bone graft: A columellar incision is made using enucleating scissors. A tunnel is created along the crest of the nose up to the glabella and another small tunnel downwards along the columella as far as the anterior nasal spine of the maxilla.

A graft is placed in the prepared tunnel below the crest of the nose keeping the cortical part facing anteriorly. A smaller graft is now cut for the columella and placed into the tunnel. The incisions are closed with fine 3/0 nylon.

The anterior nasal cavity is packed with cotton gauze soaked in paraffin. This helps in holding the skin bag and cartilage chips in place [Figures 14-16].

Postoperative management: Higher dose of broad spectrum antibiotics with anti-inflammatory drugs should be continued for 7 days. The first pack is changed on the sixth day. If there is any discharge, it may be changed



Figures 14-16: Cockett operation : 14. Carilage cubes packed in cavity over nasal bone 15. Folded skin graft's bag put in to nasal cavity 16. Bone graft introduced from crest of the nose of glabella

before this. After the fifteenth day, if there is no discharge, the pack is removed and the skin bag (graft) is perforated at the anterior nostril level; the posterior wall of the skin bag (graft) is also perforated to establish the airway. The graft is usually found to have taken over the cartilage chips. The patient is advised nasal toilet.

FARINA'S NASOLABIAL FLAPS^[7,8]

For repairing the lost lining, Farina used a median forehead flap and nasolabial flaps on subcutaneous pedicles. As the gap in the nasal lining runs transversely along the bony rim, the median forehead flap could only cover the part of defect; therefore, the use of nasolabial flaps seems to be more logical. The scar of nasolabial flaps are not only better placed but it helps in the closure of donor sites and provides a face-lifting effect.

Procedure: The columella is detached from the lip and elevated. It provides a clear view into the common nasal cavity. If the septum is still present; its middle part should be resected to ensure free breathing. The alae are detached, leaving a lateral small triangular flap attached to the muco labial junction. The incision for the lining is continued following the margin of the piriform aperture. Undermining is done close to the bone upto the glabella. The cavity is packed with saline adrenaline gauze for hemostasis.

Both the nasolabial flaps are raised on a subcutaneous pedicle. The skin edge at the base of flap is trimmed to fit the lining edge at the piriform aperture and then sutured to the latter, where the two flaps meet. The tips

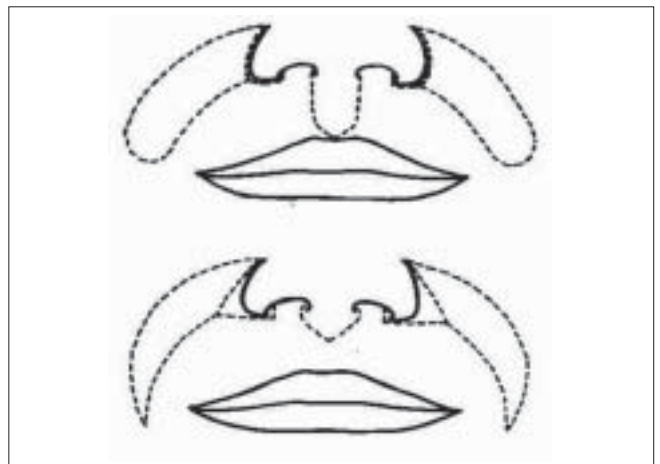
are cut and the flaps are sutured together. The suture line should be on one side of the midline so that it will not lie directly over the bone graft. For bone grafting, a straight piece of rib, 5 cm in length, is harvested and placed in the dissected nasal cavity in an L-shaped manner.

Now, the soft parts of the nose are pulled down over the bone graft. The lining of the tip and alae is sutured to the skin of the inverted nasolabial flaps. After the undermining of the skin edges, the donor area of nasolabial flaps can be closed directly. The alae with triangular skin flap and the columella are sutured back to the upper lip. The nasal cavity is packed with paraffin-soaked gauze. A plaster of Paris splint is applied over nose to keep the bone graft in position. The antibiotics are used for 5-7 days. After the tenth day, the patient asked to use liquid paraffin nasal drops three times a day and use the splint at night [Figure 17].

REPAIR OF NASAL FISTULA IN LEPROSY

Nasal myiasis is not uncommon in bacilliferous leprosy; poor hygiene, nasal ulcers and atrophic rhinitis secondary to nasal involvement predispose these patients to nasal myiasis.^[9] At times, the infestation is very extensive that if sufficient care is not provided, extensive damage can be caused to the nasal tissue, producing nasal fistula.^[6] These fistulae vary in size from 50 to 400 mm².

For covering these types of nasal defects, the immediate adjacent healthy skin is preferred as the donor site of local flaps because it gives better color match and heals well. The skin of the nasion and the adjacent portion of dorsum of nose is thin and mobile; therefore, it can



Figures 17: Farina's nasolabial flaps

be easily transferred. The resulting donor defect can be primarily closed because of the laxity of glabellar skin.

For closure of fistula, we have adapted the procedures on the basis of the size of the fistula.

For minor defects

The lining was obtained by mobilizing the surrounding tissue after making a circumferential incision around the defect about 5-8 mm away from its center. The skin edges were sutured together with chromic catgut, inverting the edge in the processes. Cover was provided with the nasolabial flaps, mobilizing the local tissue or V-Y advancement of glabellar skin.

For moderate-size defects

The nasolabial flaps based on a subcutaneous pedicle are used for both the lining and cover. The nasolabial flap of one side is used as lining and the other side as a cover or a median forehead flap on the subcutaneous pedicle is used to provide the cover.

The V-Y advancement flap from glabella is developed by undermining the skin in the loose connective tissue plane. The flap is moved downwards and inwards to the side of the defect. The donor area is easily closed because of the laxity of skin of the glabellar region. The nasolabial flap is designed with its medial marginal line in the nasolabial fold. The flap is superiorly based and after elevation, it is rotated on its subcutaneous pedicle to cover the defect.

For large-size defects

The nasolabial flaps are used for lining, and the median forehead flap is used to cover the defect [Figure 18].

CHOICE OF METHOD

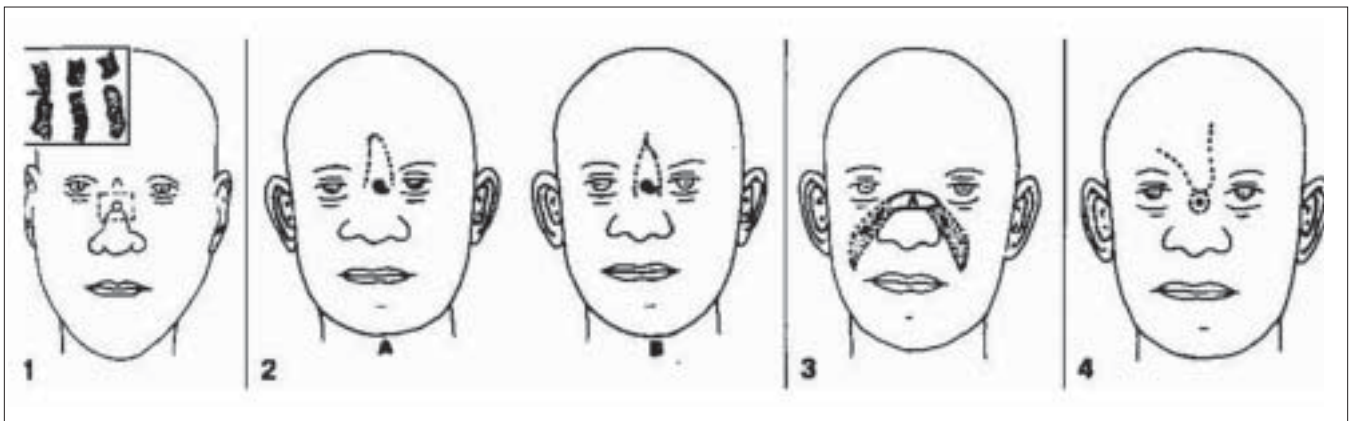
The choice will greatly depend upon the surgeon; Farina's operation^[9] requires experience with nasolabial flaps in terms of the thickness of the flap that should be cut and the width for which a donor gap will allow for direct closure.

The most popular procedure for the correction of leprosy nose has been described by Antia.^[2] This is a two-stage procedure, where a split thickness skin graft is applied to the cavity of a nose to replace the lost mucosa. The acrylic prosthesis is inserted in to give shape to the nose. At the second stage, bone graft is placed into the pocket dissected between the outer skin and mucosa. The acrylic prosthesis that is used to support the nose has to be introduced through the mouth. It requires removal for cleaning, and this is a cumbersome procedure for the patients. If the prosthesis breaks, it is difficult to obtain a replacement. Moreover, the patients do not like the oronasal fistula.

Brand^[3] operated on nasal deformities at a stage when it was not extensive by inserting a rib or iliac crest bone graft. The graft was introduced between two layers of nose either through columella or in a retrograde manner. This is also used as a prophylactic manner to prevent severe nasal deformities.

Nornon Cockett^[6] described a one-stage operation using the posterior nasal epithelial inlay and bone grafts (for the bridge of the nose and columella) obtained from the iliac crest and the filling in of the space at the upper end of nose in front of the nasal bone with minute chips of cartilage and a skin bag (free skin graft).

Severe nasal contractures are now rare due to the



Figures 18: Various nasolabial flaps to cover nasal fistula

availability of multidrug therapy and better care early in the course of the disease. Simple rhinoplasty procedures have considerably helped those patients who have the mild to moderate nasal collapse, which is more common these days.

Husain^[4] described the modified Brand's procedure of nose correction using a corticoperiosteal graft from second metatarsal bone. The graft is placed in a pocket created between lining and the skin cover of the nose.

The graft from the second metatarsal is sufficiently long and can be easily sculptured into the desired shape. The donor site problems have been considerably less as compared to iliac crest, rib or ulnar olecranon graft. The periosteum is retained on the graft to ensure better take. This is a one-stage procedure and gives satisfactory contour for the depressed nose and can be recommended for mild and moderate saddle nose deformities that are more frequently seen these days.

REFERENCES

1. Diwan VS. A survey of deformities in leprosy (With special reference to face). *Lepr Rev* 1962;33:255-62.
2. Antia NH, Daver BM. Reconstructive surgery for nasal defects. *Clin Plast Surg* 1981;8:253-63.
3. Brand PW. Deformities in leprosy. *In: Cochrane RG, editor. Leprosy in theory and practice. John Wright: Bristol; 1959. p. 314-6.*
4. Husain S, Malaviya GN. Correction of mild and moderately collapsed nose in leprosy patients. *Eur J Plast Surg* 1994;17:111-3.
5. Gillies HD. Deformities of syphilitic nose. *Br Med J* 1923;2:977.
6. Tovey FI. Reconstruction of nose in leprosy patients. *Lepr Rev* 1965;36:215-20.
7. Farina R. Deformity of nasal dorsum through loss of substance: Correction by bone grafting. *Plast Reconstr Surg* 1951;8:320-7.
8. Farina R, Villano JB. Follow up bone grafting. *Plast Reconstr Surg* 1971;48:977.
9. Husain S, Malaviya GN. Repair of nasal fistulae in leprosy. *Eur J Plast Surg* 1991;14:229-31.

Source of Support: Nil, **Conflict of Interest:** None declared.