

## Case Report

# Single stage reconstructions in head and neck surgery using deltopectoral and pectoralis major myocutaneous flaps

**Bibhuti B. Nayak, Mohanty Nilamani**

Department of Plastic Surgery, S.C.B. Medical College, Cuttack, Orissa, India

**Address for correspondence:** Dr. Bibhuti Bhusan Nayak, Associate Professor in Plastic Surgery, Qrs No-4R/9, Near AH Cancer Hospital, Mangalabag, Cuttack 753001 Orissa, India. E-mail: bibhutinayak@yahoo.com

### ABSTRACT

Even though free tissue transfers are a routine in many centres, pedicle flaps still have a huge roll to play in our country. There are many centres in the country where pedicle flaps are in use because of logistic problems. Deltopectoral and pectoralis muscle flaps are usually preferred for composite cheek defects. When both these flaps are used in combination it is a two-staged procedure. We describe a single-stage procedure to reconstruct a composite cheek defect with pectoralis major myocutaneous flap for lining and single-stage deltopectoral flap for cover. In the available literature search, single-stage DP and PMMC have not been described for management of composite cheek defect.

### KEY WORDS

Cheek defect; pectoralis major myocutaneous flap; platysma myocutaneous flap; single-stage deltopectoral flap

### INTRODUCTION

Oral cancer is the most common malignancy in India. Patients presenting with carcinoma buccal mucosa with skin involvement is not very uncommon. The reconstruction of such composite defects is always challenging. The ideal modality of reconstruction of such defects is by free tissue transfer. When microvascular option is not available or contraindicated the pedicle options are usually pectoralis major myocutaneous (PMMC) flap<sup>[1]</sup> for lining

and deltopectoral (DP) flap<sup>[2]</sup> for cover. Cover may also be achieved by cervicofacial and cervicothoracic flaps.<sup>[3,4]</sup> Conventionally, DP with PMMC flap is a two-staged procedure. If this procedure can be done in a single stage it becomes advantageous both for the patient in terms of reducing the morbidity, total cost, hospital stay and to the surgeon with no microvascular expertise.

### CONCEPT

The idea is to transpose a medially based platysma myocutaneous neck flap,<sup>[5,6]</sup> to cover the cheek defect after it has been lined by PMMC flap. The resultant neck defect after elevation of neck flap is covered by transposing a DP flap to the neck. The residual raw areas in the chest are skin grafted. This essentially becomes a single-stage procedure.

#### Access this article online

Quick Response Code:



Website:

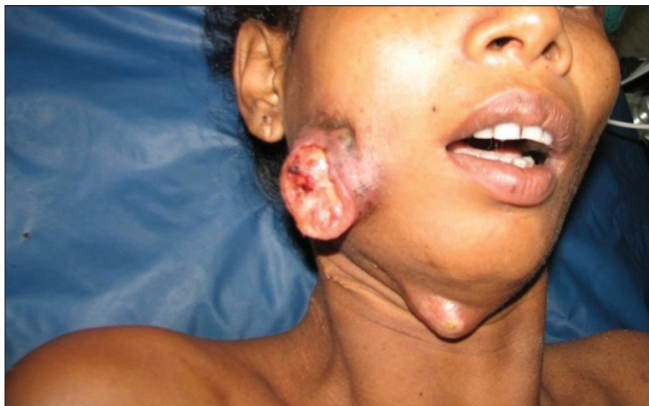www.ijps.org

DOI:

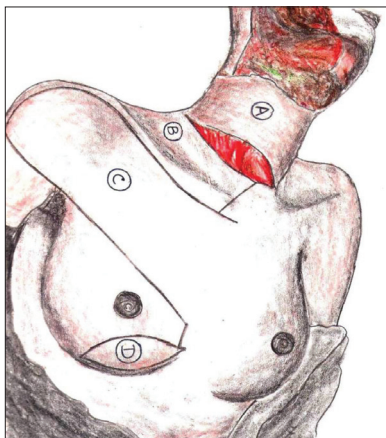
10.4103/0970-0358.96611

## SURGICAL PROCEDURE

We are describing the procedure in a 43-year-old female patient with squamous cell carcinoma of right side buccal mucosa with skin involvement and ulcerating neck node [Figure 1]. After the patient was anaesthetised, the extent of skin excision was marked. A medially based platysma myocutaneous flap was planned so as to cover the skin defect of cheek comfortably. This flap was then elevated till the midline. The Onco Surgeon then proceeded with the neck dissection, which was already bare after elevation of the platysma myocutaneous flap followed by excision of the tumour. PMMC flap and DP flaps were planned [Figures 2 and 3]. Deltopectoral flap was elevated followed by pectoralis myocutaneous flap. The pectoralis myocutaneous flap was transferred to line the mucosal defect. The DP flap was transposed to the neck. The residual neck skin over which the DP flap is going to sit was marked and elevated as a laterally based platysma myocutaneous flap and transposed to the DP area. The residual raw areas were skin grafted [Figures 4 and 5].



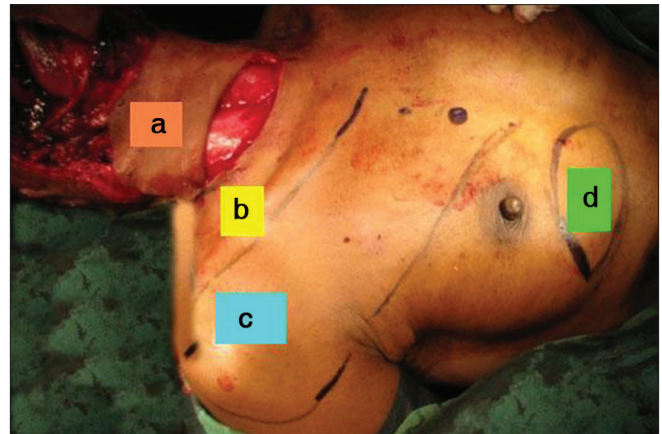
**Figure 1:** Preoperative photograph showing ulcerated carcinoma cheek with ulcerating neck node



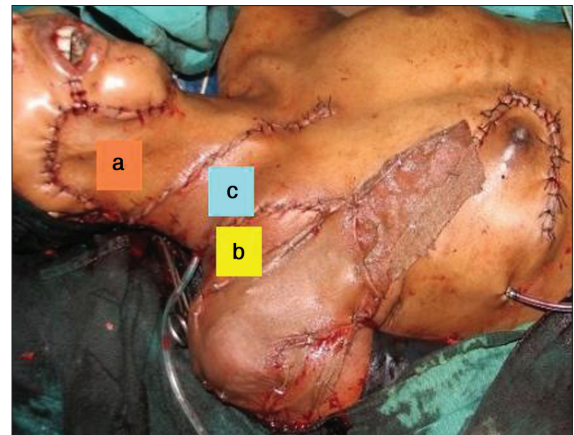
**Figure 3:** Showing planning of flaps (a) medially based platysmal myocutaneous flap (b) laterally based platysmal myocutaneous flap (c) deltopectoral flap and pectoralis major (d) myocutaneous flap

## DISCUSSION

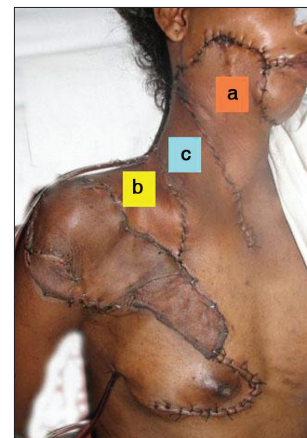
The biggest advantage of this procedure is that its a single-stage procedure.<sup>[7]</sup> One more stage and associated



**Figure 2:** Intraoperative photograph showing planning of the flaps - medially based platysmal myocutaneous flap (a), laterally based platysmal myocutaneous flap (B), deltopectoral flap (c) and pectoralis major myocutaneous flap (d)



**Figure 4:** Intraoperative photograph showing the inset of the flaps into their respective positions with skin-grafted chest wall (flap D is used for lining and hence not seen in the picture)



**Figure 5:** Eighth day postoperative photograph of the same patient, showing well settled medially based platysmal myocutaneous flap (a), laterally based platysmal myocutaneous flap (b) and deltopectoral flap (c)

morbidity is totally avoided. The patients with conventional DP flap usually do not leave the hospital till flap detachment and final inset. Hence the hospital stay is significantly reduced with this procedure. During the second stage, elevating the skin graft from its bed is bloody and at times messy. Some surgeons prefer to excise the bridge segment, which leaves a large skin grafted area on chest which is not aesthetic. The inset difficulties are also taken care of in this technique. Skin graft requirement is less (approximately 20%) than a conventional DP since part of the pectoral area is covered by the laterally based cervical flap. By the same logic it is aesthetically superior to conventional DP. Overall cost associated with a double procedure and longer stay is also avoided. For the Onco Surgeon, the neck dissection is easier with an elevated platysma myocutaneous flap leaving a bare neck. Since the length of the DP flap to reach the neck is shorter than a cheek defect, it is more reliable.<sup>[8]</sup> There is no necessity to raise an extended DP flap.<sup>[9]</sup>

There is no doubting the fact that free tissue transfer is superior to this technique. But this flap comes in the armamentarium when the logistics do not favour a free flap. This is aesthetically superior to a double paddle PMMC and more so in a female patient where the flap is very bulky. Forehead flap is also an option where lining and cover can be provided but it is aesthetically not appealing for obvious donor site deformity. Providing cover with a cervicothoracic flap is another option but it is cumbersome to raise such a huge flap as a single unit. Our technique splits this single cervicothoracic<sup>[4]</sup> unit into three units which allows a better positioning of regional tissue units.

However there are certain minor disadvantages with this procedure. The duration of surgery under anaesthesia is little prolonged. The extent of dissection is also relatively more. The plastic surgeon has to precisely plan and raise

the neck flap prior to the Onco procedure so as allow the Onco Surgeon access to the neck. In patients with normal neck skin, a part of it is sacrificed near its base to avoid dog ear, which was not the case with this patient since she had an ulcerating neck node.

## CONCLUSION

This technique offers an alternative to single-staged microvascular procedure and is superior to double-paddle PMMC or conventional DP with PMMC for classical lining and skin defects.

## REFERENCES

1. Ariyan S, Cuono CB. Myocutaneous flaps for Head and Neck Reconstruction. *Head Neck Surg* 1980;2:321-45.
2. Bakamjian VY, Long M, Rigg B. Experience with the medially based deltopectoral flap in reconstructive surgery of the head and neck. *Br J Plast Surg* 1971;24:174-83.
3. Becker FF, Langford FP. Deep-plane cervicofacial flap for reconstruction of large cheek defects. *Arch Otolaryngol Head Neck Surg* 1996;122:997-9.
4. Moore BA, Wine T, Netteville JL. Cervicofacial and Cervicothoracic rotation flaps in head and neck reconstruction. *Head Neck* 2005;27:1092-101.
5. Su T, Zhao Y-F, Liu B, Hu Y-P, Zhang W-F. Clinical review of three types of platysma myocutaneous flap. *Int J Oral Maxillofac Surg* 2006;35:1011-5.
6. Kocer U, Ozdemir R, Ulusoy MG, Uysal A, Sungur N. Anatomy of the platysma muscle and the evaluation of it for the reconstruction of facial defects. *J Craniofac Surg* 2005;16:463-70.
7. Purkayastha J, Hazarika B. Single stage delto-pectoral flap cover for large defects following extensive neck dissection. *Indian J Otolaryngol Head Neck Surg* 2006;59:33-4.
8. Daniel RK, Cunningham DM, Taylor GI. The deltopectoral flap: An anatomical and hemodynamic approach. *Plast Reconstr Surg* 1975;55:275-82.
9. McGregor IA, Jackson IT. The Extended role of the deltopectoral flap. *Br J Plast Surg* 1970;23:173-85.

**How to cite this article:** Nayak BB, Nilamani M. Single stage reconstructions in head and neck surgery using deltopectoral and pectoralis major myocutaneous flaps. *Indian J Plast Surg* 2012;45:151-3.

**Source of Support:** Nil, **Conflict of Interest:** None declared.