

Emoticons for radiologist

Dear Sir,

An emoticon is a pictorial representation of a facial expression using punctuation marks and letters, usually written to express a person's mood. The use of emoticons can be traced back to the 19th century, and they were commonly used in casual and humorous writing. In the current digital world, these representations are automatically converted into small facial images, thereby easing the difficulty in interpretation. The odontoid process is the protuberance of the axis. Variations in the trabecular meshwork of bone result in the creation of various expressions. Postprocessed CT images showing happy odontoid along with other emoticons. Postprocessed CT images showing happy

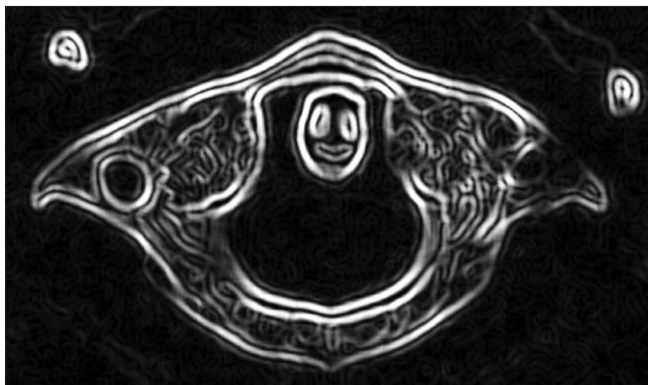


Figure 1: Happy odontoid

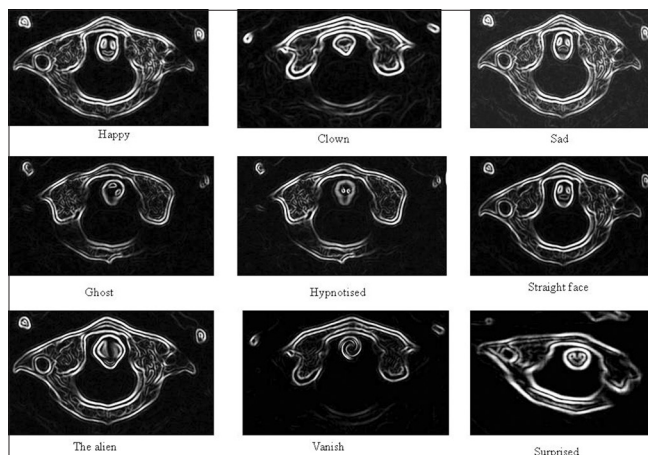


Figure 2: Various emoticons

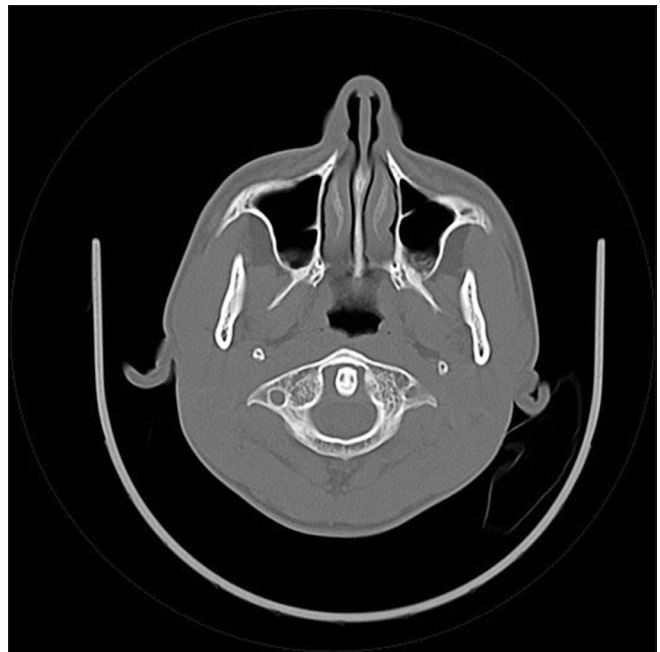


Figure 3: Original axial CT image

odontoid [Figure 1] and other emoticons [Figure 2] along with one of the original image [Figure 3].

Acknowledgement

I would like to extend my sincere thanks to Dr Regi George A N, Jubilee Mission Medical College for his excellent support.

Navdeep Singh

Department of Radiodiagnosis, Jubilee Mission Medical College, Thrissur-680 005, India.
E-mail: navdeepshah01@gmail.com

Access this article online

Quick Response Code:



Website:
www.ijri.org

DOI:
10.4103/0971-3026.101093