

Acute pulmonary melioidosis in a child: A case report and review of literature

Deb K Boruah, Arjun Prakash, Reeta Bora¹, Lemanstar Buragohain²

Departments of Radiodiagnosis, and ¹Paediatrics, Assam Medical College and Hospital, Dibrugarh,

²Department of Paediatrics, Aditya Diagnostics and Hospital, Dibrugarh, Assam, India

Correspondence: Dr. Deb K. Boruah, Department of Radiodiagnosis, Assam Medical College and Hospital, Dibrugarh, Assam - 786 002, India. E-mail: drdeb_rad@yahoo.co.in

Abstract

Melioidosis is a rare potentially fatal infection caused by the bacterium *Burkholderia pseudomallei*, which is endemic in Southeast Asia and Northern Australia and an emerging pathogen in India. It is a largely under-diagnosed disease and an imitator of tuberculosis, both clinically and radiologically.

Key words: *Burkholderia pseudomallei*; ecthyma gangrenosum; melioidosis; septicemia

Introduction

Melioidosis is a rare but life-threatening infection caused by the bacterium *Burkholderia pseudomallei*, with an estimated incidence of 4.4 in 100,000 people in northeastern Thailand and 1.7 in 100,000 people in Singapore, which are high endemic zones.^[1] In India, only sporadic cases have been reported,^[2,3] but the exact incidence is not known, largely because it is an under-recognized and under-reported disease^[2] and its imaging manifestations are poorly understood. It is called a mimicker of maladies and can mimic any community-acquired bacterial sepsis, pneumonia, abscess (especially that produced by *Staphylococcus*) or tuberculosis.^[1,4]

Case Report

A 16-month-old girl child from North east district of India presented to the emergency department with multiple erythematous nodules and ulcers in the skin [Figure 1A and B], difficulty in breathing, and fever

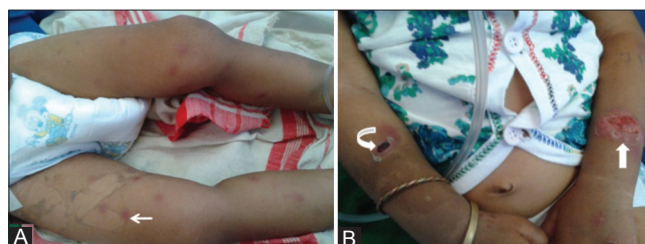


Figure 1 (A, B): Photographs of the child reveal eschar over extensor aspect of right forearm (curved arrow) with healing ulcer over left forearm (block arrow) and multiple erythematous nodules over both thighs and legs (thin straight arrow)

since 5 days. The parents gave history of near drowning in drain water 7 days prior to the onset of illness. The birth history was unremarkable.

On general physical examination, the child was conscious, irritable, febrile with toxic look, had tachypnea and tachycardia, and weighed 8 kg (Grade I malnutrition for age). Multiple erythematous nodules and ulcers (ecthyma gangrenosum) were noted in the skin, with few eschars [Figure 1A and B]. Her pulse was 100/min and BP 90/56 mm Hg. Routine blood examinations revealed raised leukocyte count (14,500/mm³), neutrophilia (89%), elevated C-reactive protein (CRP; 68 mg/l) and procalcitonin (2.56 ng/dl) levels. The liver enzymes were mildly elevated [aspartate transaminase (AST) 138 IU/l; alanine transaminase (ALT) 99 IU/l; alkaline phosphatase (ALP) 363 IU/l] and renal function tests were unremarkable. The blood sugar level was within normal limits. ELISA test for the qualitative

Access this article online

Quick Response Code:



Website:
www.ijri.org

DOI:
10.4103/0971-3026.125576

determination of antibodies to human immunodeficiency virus (HIV) type 1 and 2 viruses was non reactive. On examining the respiratory system, coarse crepitations and rhonchi were noted bilaterally.

Initial empirical antibiotic therapy was initiated with intravenous (IV) injections of Piperacillin + Tazobactam and Netilmicin. However, there was progressive deterioration of the patient's general condition with appearance of new skin lesions during the course of treatment.

An anterior–posterior (AP) view of chest radiograph [Figure 2] revealed multiple patchy consolidations with air bronchogram in the left upper-mid zone and right mid and lower zones, with cavitations in few of them.

High-resolution computed tomography (HRCT) and contrast-enhanced computed tomography (CECT) of the thorax was done on 64 slice MDCT scanner, (Aquilion 64, Toshiba Medical Systems Corporation, Japan) [Figures 3A-F] which revealed multiple variable-sized segmental and subsegmental air-space consolidations scattered in bilateral lung parenchyma, more on the right side where few of them showed areas of eccentrically located breakdown and cavitations. Multiple relatively larger nodular lesions were also noted in parenchyma of both the lungs. Most of the cavitory lesions showed dependant intracavitary low-density collections. No mediastinal lymphadenopathy was noted. Based on the imaging findings, an initial diagnosis of septic pyogenic pneumonic abscesses with differential diagnosis of pulmonary tuberculosis was given.

However, a diagnosis of tuberculosis did not correlate well with the atypical skin lesions, the acute presentation, and the rapidly progressing clinical deterioration of the child. A fine-needle aspiration cytology (FNAC) from a nodule in the left forearm revealed frank pus [Figures 4A and B]. A blood culture was done which showed growth of colonies of *B. pseudomallei* within 3 days, which established the diagnosis of melioidosis.

Based on the culture and sensitivity reports, specific antibiotic therapy was started with IV Meropenam, along with nebulization. However, despite intensive care and antibiotic therapy unfortunately, the child died 2 days later due to septicemic pneumonia (1 week since admission).

Discussion

Alfred Whitmore and C S Krishnaswami first described melioidosis as a “glanders-like disease,” which was recognized from autopsies in morphine addicts and vagabonds found dead in the streets of Rangoon, Myanmar in 1911.^[5] Tanton and Fletcher in 1932 proposed the name “melioidosis,” derived from the Greek *melis* meaning “a distemper of asses.”^[6] It is endemic in Southeast Asia and

Northern Australia, mainly in Thailand, Malaysia, Singapore, Myanmar, and Vietnam.^[1,7] In India, sporadic cases have been reported mainly from the southern states of Kerala, Tamil Nadu and Karnataka.^[2,7,8] To the best of our knowledge, only two other cases of melioidosis have previously been reported in literature from Northeast India.^[2,3]

B. pseudomallei is a natural inhabitant of soil and water and mainly confined to tropical and subtropical regions.^[7] The disease is acquired by inoculation through abraded skin, inhalation, or ingestion, and majority of cases present during rainy season.^[8,9] Localized form of melioidosis presents as pneumonia, skin ulcers, and subcutaneous abscesses, whereas disseminated form presents as multifocal pneumonia, subcutaneous abscesses, abscesses in solid abdominal visceral organs, septic arthritis, osteomyelitis, and septicemia.^[8,10] Other rare manifestations include parotid abscess, cerebral abscess and focal encephalitis.^[11,12] It occurs more frequently in patients with conditions associated with immunosuppression such as diabetes mellitus, chronic renal failure, alcoholism, malignancy, or hematological disorders.^[1,9,11]

The lung is reportedly the most commonly affected organ.^[11] Aspiration after near-drowning is a possible pathway of infection.^[1] The disease can present in acute, subacute or chronic forms. The clinical findings and imaging features of pulmonary melioidosis can follow a spectrum varying from mild respiratory illness and simple pneumonitis to multiple pulmonary masses, cavitations and severe septicemia. The radiological findings in acute form include focal consolidation or multiple small pulmonary nodules

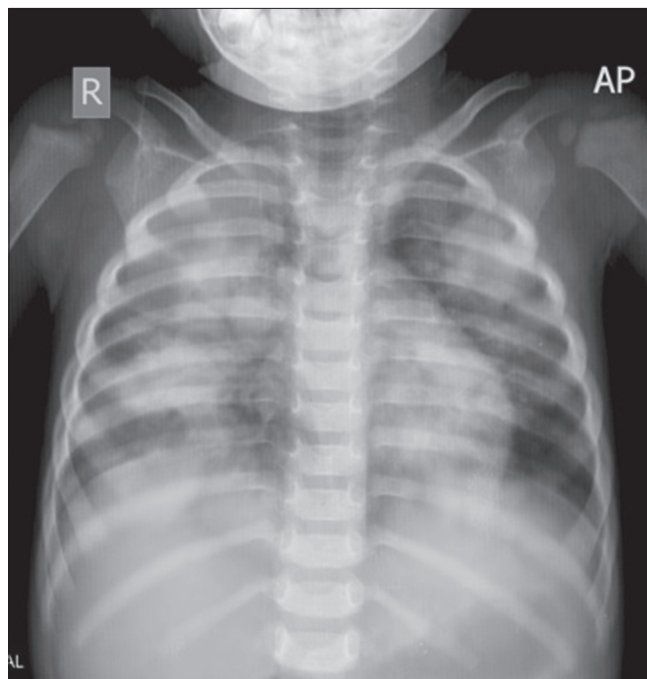


Figure 2: Plain chest radiograph AP view of the child shows patchy consolidations with air bronchogram in both lung fields with areas of cavitation in right lower lobe lesion

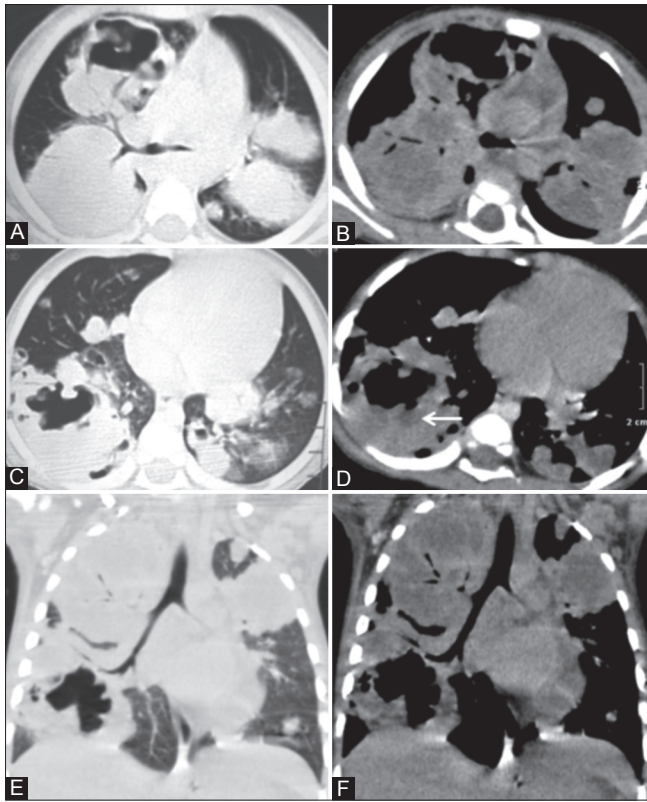


Figure 3 (A-F): Axial (A-D) and coronal reformatted (E, F) high-resolution computed tomography (HRCT) and contrast-enhanced (CECT) thorax images show multiple large nodular and cavitary lesions, with some of them showing fluid levels (straight arrow) randomly distributed in bilateral lung parenchyma representing pneumonic consolidations as well as disseminated abscesses. Few infiltrative peri-cavitary nodules are also noted

that start at the upper lobes and may progress to cavity or abscess formation.^[1,12] In the chronic form, mixed patchy, mottled, and streaky infiltrates are common.^[13] Sometimes, it might be difficult or nearly impossible to differentiate it from tuberculosis or other pyogenic infections like that of *Staphylococcus* or even from malignancy.^[2,4,13] However, it usually spares the apices with less fibrosis in the chronic form.^[1] Pneumothorax, pleural effusion and empyema are rare unless associated with rupture of a cavity or lung abscess.^[1,11,13] The presence of air-fluid level in a cavity and mediastinal lymphadenopathy are also uncommon.^[11]

Conclusion

Melioidosis is a very rare, but emerging disease in India. Our patient probably acquired the infection through near drowning in drain water. Although the imaging findings may mimic tuberculosis or other bacterial infections, the clue to diagnosis could be disseminated abscesses in skin and lung, history of near drowning and rapidly progressive clinical deterioration of the child. However, confirmatory diagnosis is blood culture. Acute pulmonary melioidosis, although a rare disease, should be kept in mind by radiologists and clinicians whenever a patient of acute clinical deterioration presenting

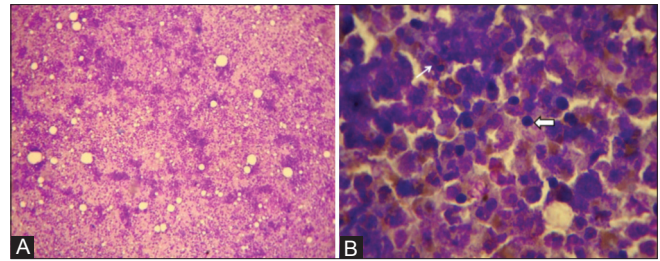


Figure 4 (A, B): Fine needle aspiration cytology (FNAC) showing both intact and degenerating inflammatory cells comprising mainly neutrophils (thin straight arrow), lymphocytes (block arrow), and some macrophages (not in pic) in a hemorrhagic background, suggestive of pyogenic abscess [May Grunwald Giemsa stain, x10 (A) and x100 (B)]

with multifocal lung parenchymal consolidations, cavitations, and intracavitary fluid collections along with multiple abscesses in skin and/or visceral organs is encountered.

References

- Muttarak M, Peh WC, Euathrongchit J, Lin SE, Tan AG, Lerttumnongtum P, *et al.* Spectrum of imaging findings in melioidosis. *Br J Radiol* 2009;82:514-21.
- Saravu K, Mukhopadhyay C, Vishwanath S, Valsalan R, Docherla M, Vandana KE, *et al.* Melioidosis in Southern India: Epidemiological and clinical profile. *Southeast Asian J Trop Med Public Health* 2010;41:401-9.
- Mathew S, Perakath B, Mathew G, Sitaram V, Nair A, Lalitha MK, *et al.* Surgical presentation of Melioidosis in India. *Natl Med J India* 1999;12:59-61.
- Vidyalakshmi K, Chakrapani M, Shrikala B, Damodar S, Lipika S, Vishal S. Tuberculosis mimicked by Melioidosis. *Int J Tuberc Lung Dis* 2008;12:1209-15.
- Whitmore A, Krishnaswami CS. An account of the discovery of a hitherto undescribed infective disease occurring among the population of Rangoon. *Indian Med Gaz* 1912;47:262-7.
- Stanton AT, Fletcher W. Melioidosis, a new disease of the tropics. *Trans 4th Congress Far East. Assoc Trop Med* 1921;2:196-8.
- Barman P, Sidhwa H, Shirkhande PA. Melioidosis: A Case Report. *J Glob Infect Dis* 2011;3:183-6.
- Saravu K, Mukhopadhyay C, Eshwara VK, Shastry BA, Ramamoorthy K, Krishna S, *et al.* Melioidosis presenting with mediastinal lymphadenopathy masquerading as malignancy: A case report. *J Med Case Rep* 2012;6:28.
- White NJ. Melioidosis. *Lancet* 2003;361:1715-22.
- Lee YL, Lee SS, Tsai HC, Chen YS, Wann SR, Kao CH, *et al.* Pyogenic liver abscess caused by *Burkholderia pseudomallei* in Taiwan. *J Formos Med Assoc* 2006;105:689-93.
- Ip M, Osterberg LG, Chau PY, Raffin TA. Pulmonary melioidosis. *Chest* 1995;108:1420-4.
- Dhiansiri T, Puapairoj S, Susaengrat W. Pulmonary melioidosis: Clinical-radiologic correlation in 183 cases in northeastern Thailand. *Radiology* 1988;166:711-5.
- Reechaipichitkul W, Prathanee S, Chetchotisakd P, Kularbkaew C. Pulmonary melioidosis presenting with a lung mass undifferentiated from cancer: A case report. *J Infect Dis Antimicrob Agents* 2000;17:35-8.

Cite this article as: Boruah DK, Prakash A, Bora R, Buragohain L. Acute pulmonary melioidosis in a child: A case report and review of literature. *Indian J Radiol Imaging* 2013;23:310-2.

Source of Support: Nil, **Conflict of Interest:** None declared.