

Multimodality imaging in cranial blastomycosis, a great mimicker: Case-based illustration with review of clinical and imaging findings

Puneet S Kochar, Chinar O Lath, Andrew P Klein, John L Ulmer

Department of Radiology, Division of Neuroradiology, Medical College of Wisconsin, Milwaukee, Wisconsin, USA

Correspondence: Dr. Puneet S Kochar, Department of Radiology, Division of Neuroradiology, Medical College of Wisconsin, Milwaukee, Wisconsin, USA. E-mail: drkochar.puneet@gmail.com

Abstract

We describe the clinical, laboratory, and imaging data of three patients who are proven cases of blastomycosis with cranial involvement. In this review, we discuss the imaging features of cranial blastomycosis with relevant clinical case examples including computed tomography (CT), magnetic resonance imaging (MRI), and advanced MR imaging techniques like magnetic resonance spectroscopy (MRS) and MR perfusion. Literature is reviewed for modern-day diagnosis and treatment of this fatal intracranial infection, if not diagnosed promptly and managed effectively.

Key words: Blastomycosis; cranial; magnetic resonance imaging

Introduction

Blastomyces dermatitidis is a thermally dimorphic fungus that thrives in nature in septate hyphal (mycelium) phase and changes into broad-based budding yeast at body temperature. Blastomycosis is endemic in certain areas of US and Canada. In contrast to many other fungal infections, it can affect immunocompetent individuals, especially people who do farming and engage in outdoor activities. Cranial involvement in blastomycosis is uncommon, as compared to pulmonary and skin involvement. In endemic areas and in the appropriate clinical setting, blastomycosis should be considered in the differential diagnosis of unusual intracranial lesions.

Case Reports

Case 1

An 18-year-old male with past medical history of successfully treated pulmonary and cutaneous blastomycosis presented with right-sided partial seizures. Computed tomography (CT) head without contrast revealed a subtle, ill defined, hyperdense ring configuration lesion in the left frontoparietal region with surrounding vasogenic edema [Figure 1A and B]. Subsequent magnetic resonance imaging (MRI) brain with and without contrast revealed an irregular, crenated, thick walled, round rim-enhancing lesion in the left postcentral gyrus [Figure 2F]. There was perilesional edema expanding

This is an open access article distributed under the terms of the Creative Commons Attribution-NonCommercial-ShareAlike 3.0 License, which allows others to remix, tweak, and build upon the work non-commercially, as long as the author is credited and the new creations are licensed under the identical terms.

For reprints contact: reprints@medknow.com

Cite this article as: Kochar PS, Lath CO, Klein AP, Ulmer JL. Multimodality imaging in cranial blastomycosis, a great mimicker: Case-based illustration with review of clinical and imaging findings. Indian J Radiol Imaging 2016;26:120-5.

Access this article online

Quick Response Code:



Website:
www.ijri.org

DOI:
10.4103/0971-3026.178360

the postcentral gyrus [Figure 2A and B]. Small area of restricted diffusion [Figure 2C and D; white arrow in C] and T1 shortening [Figure 2E] was seen within the lesion. No hemorrhage or hemosiderin was noted. Single- and multi-voxel magnetic resonance spectroscopy (MRS) was performed. Choline-to-N-acetylaspartate (NAA) ratio did not meet the criteria for neoplasm on either the short or long TE images [Figure 3A and B]. Multiple peaks at 0.9–1.3 ppm were consistent with lipid/lactate. Note was made of peaks between 3.6 and 3.8 ppm, which may represent disaccharide trehalose. Follow-up after 9 months of treatment revealed marked reduction in the size of the lesion and perilesional edema (image not shown) with complete resolution after 12 months [Figure 4A and B]. Contrast enhanced CT chest demonstrated consolidation in the right lower lobe [Figure 5A and B]. Blastomycosis was confirmed at bronchoalveolar lavage and in the urine. Follow up chest X-rays showed gradual and complete clearing of consolidation with antifungal treatment.

Case 2

A 72-year-old female presented with a 3 weeks history of progressively worsening vertigo, ataxia, and preexisting

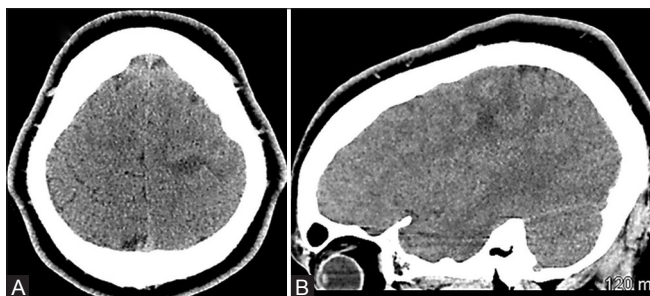


Figure 1 (A and B): Axial (A) and sagittal (B) unenhanced CT head done in case 1 shows ill-defined hyperdense ring configuration lesion in the left frontoparietal region with surrounding vasogenic edema

left sided hearing loss. CT of the head showed a slightly hyperdense peripheral left cerebellar mass lesion with edema (image not shown). Bone windows did not reveal osseous erosion or sclerosis. MRI brain showed a heterogeneous conglomerate ring-enhancing left cerebellar mass and extensive surrounding edema with mass effect on the brainstem and adjacent ventricular system [Figure 6A, E and F]. Laterally, the mass was contacting the dural surface with focal tentorial enhancement [Figure 6D and E; pre-contrast and post-contrast respectively]. Diffusion images demonstrated at least three small focal areas of restricted diffusion [Figure 6B and C]. Contrast enhanced dynamic susceptibility imaging (DSC)

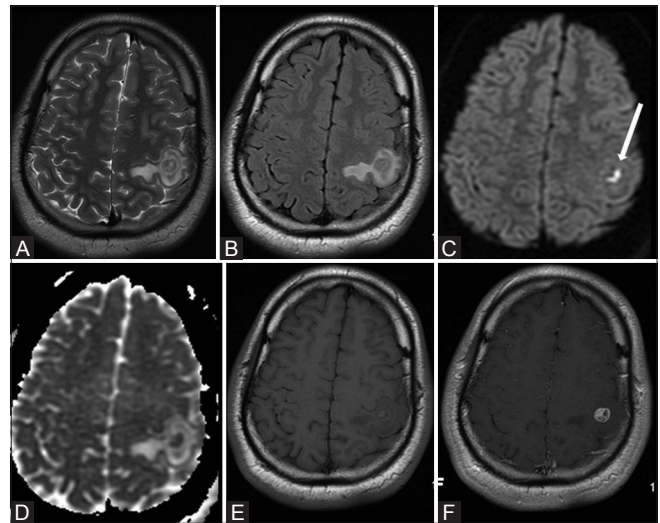


Figure 2 (A-F): Subsequent MRI brain with and without contrast in case 1 shows a ring configuration with perilesional edema expanding the left post central gyrus on T2 and FLAIR images (A and B). Small area of restricted diffusion (C and D; white arrow in C) and T1 shortening (E) is seen within this lesion. Post contrast T1 image shows an irregular crenated thick-walled round rim enhancement (F)

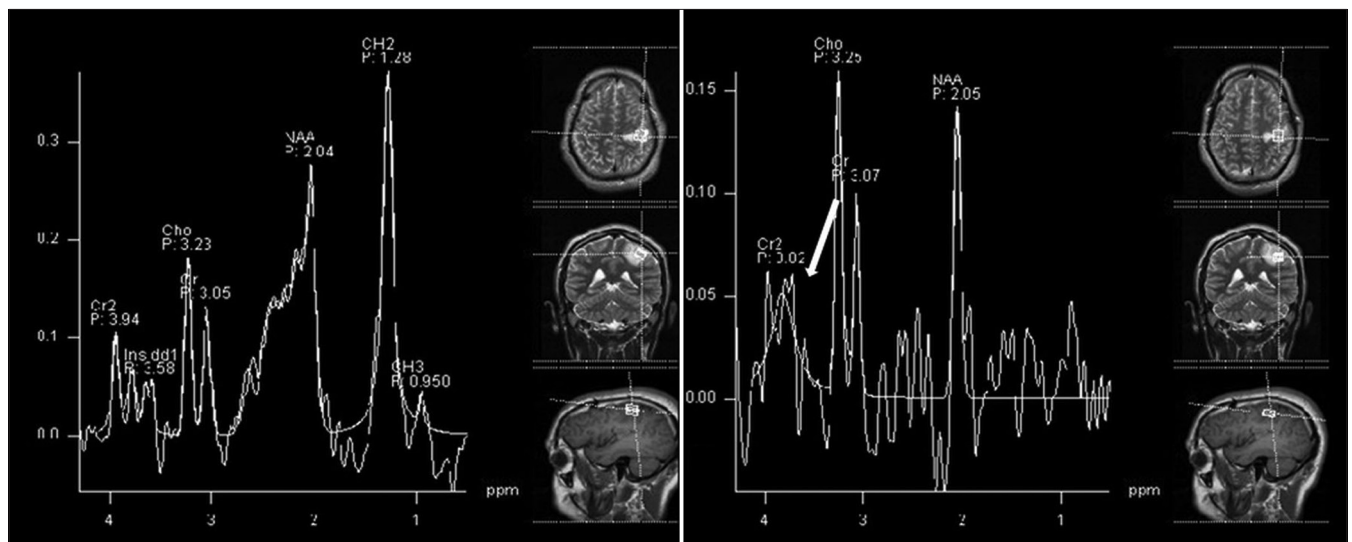


Figure 3: Single voxel short TE (left) and long TE (right) MR spectroscopy through the lesion in case 1 show a peak between 3.5 to 3.8 (white arrow) may represent trehalose peak. Choline-to-NAA ratio did not meet the criteria for neoplasm. Multiple peaks at 0.9-1.3 ppm represent lipid/lactate

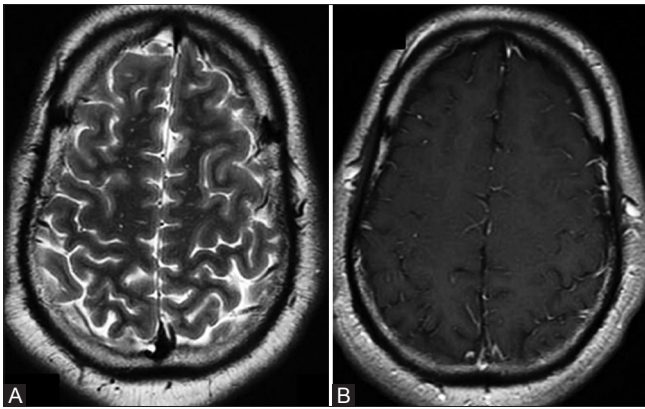


Figure 4 (A and B): Follow up MRI brain performed 12 months after treatment in case 1 shows complete resolution of edema (A) and enhancing lesion (B)

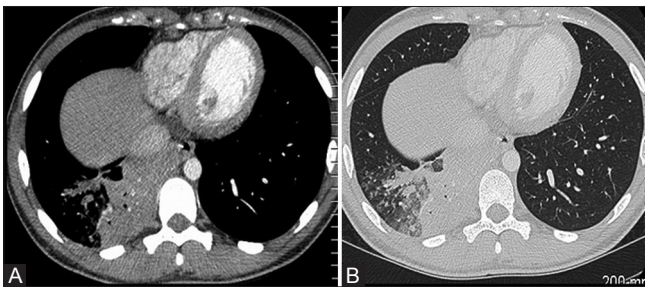


Figure 5 (A and B): Axial contrast enhanced CT chest images in case 1 show consolidation in the right lower lobe (A and B). Blastomycosis was confirmed at bronchoalveolar lavage

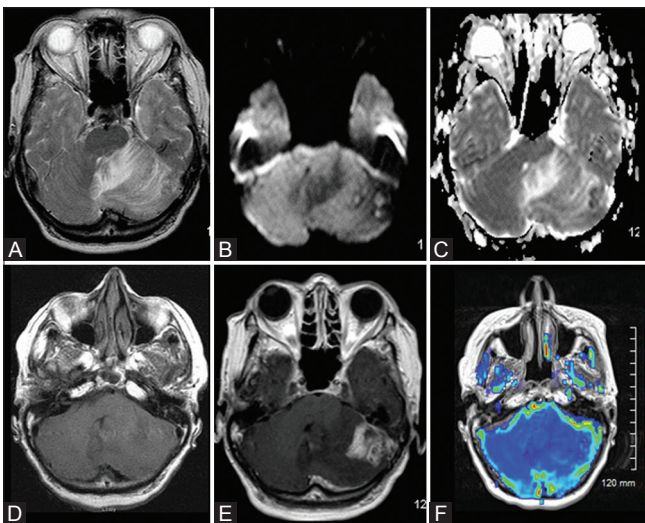


Figure 6 (A-F): MRI brain with contrast in case 2 shows vasogenic edema (A) in left cerebellar hemisphere surrounding an ill-defined altered signal intensity mass lesion demonstrating small focal areas of restricted diffusion (B and C). The mass lesion shows heterogeneous conglomerate ring enhancement (D and E). Contrast enhanced dynamic susceptibility imaging (DSC) MR perfusion with contrast (F) shows no evidence of increased perfusion/neoangiogenesis

MR perfusion with contrast showed no evidence of increased perfusion/neoangiogenesis within the mass [Figure 6F]. MRS (short and long TE) showed increased lipid/lactate,

decreased *N*-acetyl aspartate, and increased choline peaks, which were typical for a neoplasm [Figure 7]. Therefore, a high-grade neoplasm was suspected. The patient underwent surgery and the lesion was resected. Histology revealed fragments of cerebellum with abundant mixed acute and chronic inflammation, as well as fungal organisms morphologically consistent with *Blastomyces* species. Hematoxylin and Eosin (H and E) stained section at $\times 400$ magnification showed large, round, thick-walled yeast cells [Figure 8A]. Grocott's methenamine silver (GMS) stain section at $\times 400$ magnification highlighted the yeast cells with broad-based budding [Figure 8B]. The specimen was negative for malignant cells. MRS findings were re-evaluated. Peaks between 3.6 and 3.8 ppm were noted, which may represent trehalose peaks. The patient was treated with IV and oral long term antifungals. Follow-up scan after 3.5 months showed no evidence of recurrence. Metastatic workup was negative.

Case 3

A 57-year-old man with past medical history of acute myeloid leukemia (AML), status post allogeneic bone marrow transplantation in 2010 and old cerebrovascular accident (CVA) in 2011, presented with multiple painful cutaneous nodules scattered within the scalp, face, neck, back, chest, buttocks, hands, and feet. Lesions were tender to touch. MRI brain without contrast revealed scattered multiple small scalp lesions showing restricted diffusion [Figure 9A and B; arrow in A]. The lesions were hypointense on T1 and hyperintense on fluid attenuation inversion recovery (FLAIR) images [Figure 9C and D]. CT chest before treatment showed multiple scattered nodules and areas of ground glass opacity [Figure 10A] with consolidation in the superior segment of the left lower lobe [Figure 10B]. Treatment with amphotericin B for 2 weeks and oral itraconazole for 1 year showed remarkable clearance of the lesions in the skin and lungs [Figure 10C and D]. Biopsy of the skin lesions revealed focal dense collections of polymorphs admixed with fibrin and multiple round to oval yeast with occasional budding on H and E stain [Figure 11A]. The organism was GMS positive with negative mucicarmine. GMS stain showed broad based budding yeasts [Figure 11B]. Findings were consistent with blastomycosis.

Discussion

B. dermatitidis is a dimorphic fungus endemic in certain parts of North America. Endemic areas are Mississippi and Ohio River valley areas in USA and in areas of northwestern Ontario around Kemora in Canada.^[1,2] CNS blastomycosis is rare clinical manifestation of infection occurring in 2.5–10% of those with disseminated systemic disease,^[2,3] but has been observed in one-third of patients in an autopsy series.^[4] Immune status is an independent variable for CNS blastomycosis, but higher rates can be seen in AIDS

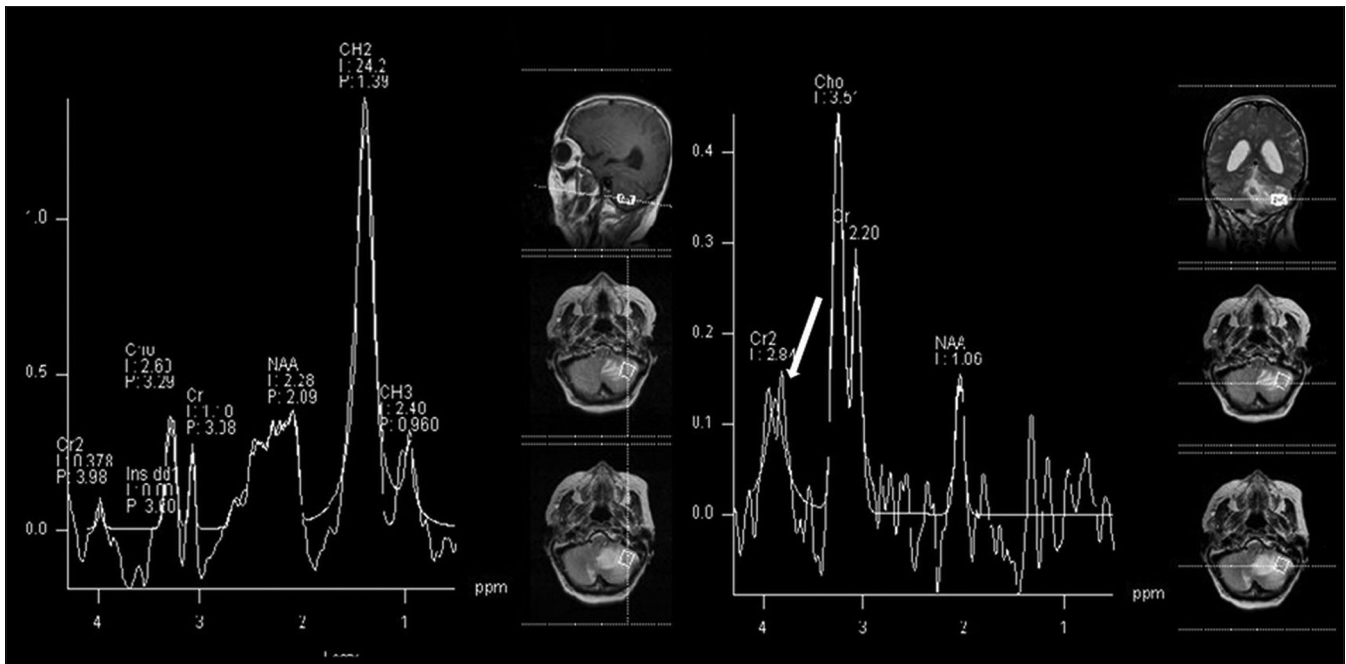


Figure 7: Single voxel short TE (left) and long TE (right) MR spectroscopy through the lesion in case 2 shows increased lipid/lactate, decreased N-acetyl aspartate, and increased choline peaks. Peak between 3.5 to 3.8 (white arrow) may represent trehalose peak

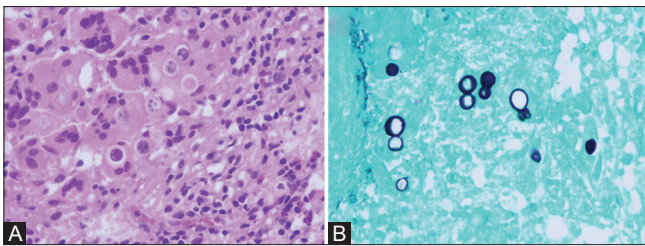


Figure 8 (A and B): Hematoxylin and eosin (H and E) stained section at x400 magnification (A) in case 2 show large round thick-walled yeast cells. Grocott's methenamine silver (GMS) stain section at x400 magnification (B) demonstrates broad based budding yeast cells

patients, which can approach 40%.^[5] The most common single organ involved is the lung, followed by skin, bone, and genitourinary system (in order of frequency).^[6,7]

Meningoencephalitis is the typical form of presentation. Intraparenchymal lesions are rare and are postulated to be due to hematogenous spread from the lungs. Intracranial extension into the epidural space may occur from adjacent osteomyelitis of the skull.^[8] Ward *et al.* described epidural abscesses and empyemas in the region of underlying lytic skull lesions intraoperatively.^[9] Clinical symptomatology is nonspecific. Bariola *et al.*, in their retrospective, multicenter review of 22 patients with CNS blastomycosis found that headache was the most common neurologic symptom that was present in 86% of patients. Other common complaints included focal neurologic deficit, altered mental status, visual changes, and seizures.^[7]

The imaging characteristics of CNS blastomycosis are variable and nonspecific, ranging from diffuse leptomeningeal

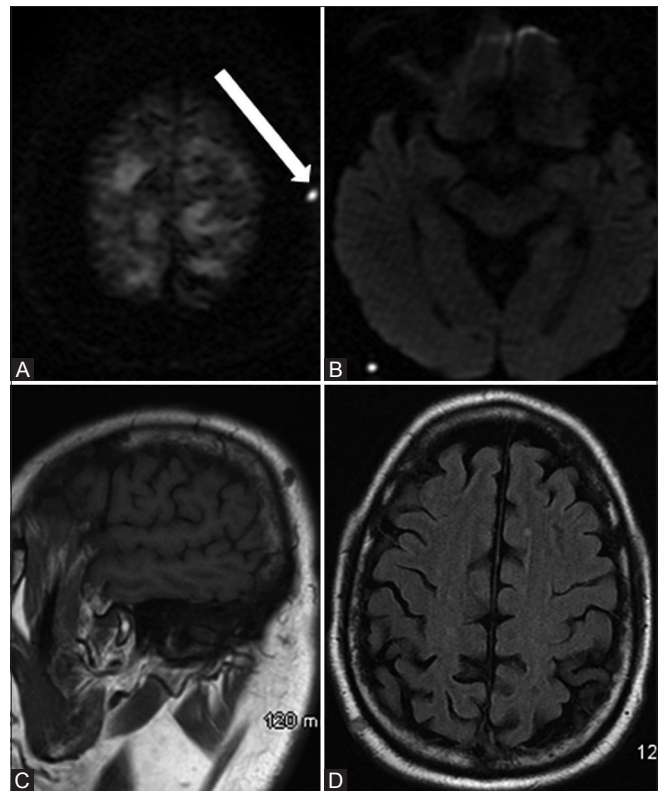


Figure 9 (A-D): MRI brain without contrast in case 3 shows scattered small scalp lesions showing restricted diffusion (A and B; white arrow in A). The lesions appear hypointense on T1 (C) and hyperintense on FLAIR (D)

enhancement to numerous punctate lesions and discrete focal mass lesions.^[8] CT findings are nonspecific. Parenchymal lesions can either be hypo-, iso-, or hyper-dense. Lesions

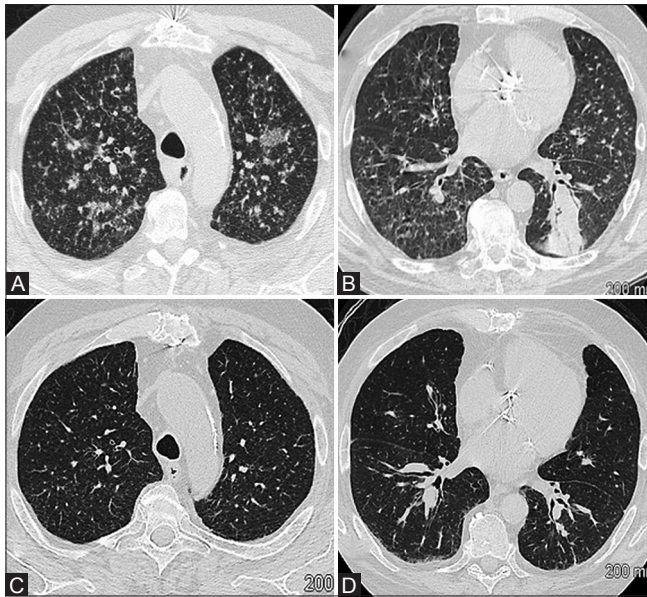


Figure 10 (A-D): Pre-treatment CT chest in case 3 (A and B) shows multiple scattered nodules and areas of ground glass opacity (A) with consolidation in the superior segment of the left lower lobe (B). CT chest after two weeks of antifungal treatment (C and D) shows remarkable clearance of the lesions

show either ring configuration or mass-like enhancement.^[2] MRI is considered the imaging modality of choice with better soft tissue resolution. Bariola *et al.* reported one case in which the patient had a negative CT scan, but showed diffuse leptomeningeal enhancement and a basal ganglia lesion on contrast-enhanced MRI.^[7] On MRI, the lesions typically demonstrate marked homogenous contrast enhancement.^[8,10] Scott and Dhir reported a case with heterogeneously enhancing mass lesions in the left basal ganglia and left cerebellopontine angle.^[2] Munich *et al.* reported one patient with a large conglomerate ring-enhancing mass in the right cerebellar parenchyma with extensive surrounding vasogenic edema.^[8] Akture *et al.* reported a case with a cerebellopontine angle mass extending into the internal auditory canal, mimicking a schwannoma or meningioma.^[11] Wylene and Nanda^[12] and Kale *et al.*^[13] reported cases with dural based plaque-like enhancing lesions mimicking en plaque meningioma. Similarly, Chander *et al.* reported a case of a large homogeneously enhancing extra-axial mass in the anterior cranial fossa, mimicking a meningioma.^[14] Interestingly, conglomerate ring-enhancing mass lesions can mimic racemose neurocysticercosis (NCC), as reported by Kim *et al.*^[15] Mohazab *et al.* reported a case of intracranial blastomycosis presenting as a suprasellar mass.^[16] The wide variety of cases reported throughout the literature suggest that intracranial imaging findings are nonspecific. However, a review of reported cases of intracranial blastomycosis since 1978 strongly suggests that direct isolation of *Blastomyces* from the CNS may not be necessary if the fungus can be isolated or identified morphologically from an extraneural site.^[16]

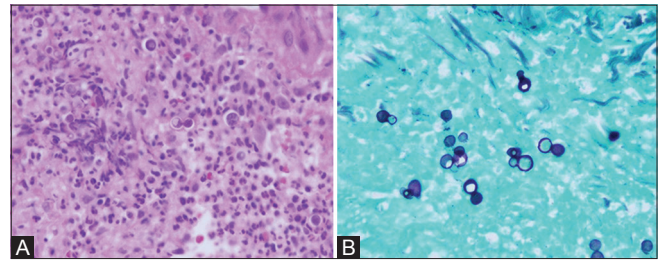


Figure 11 (A and B): H and E stained section at $\times 400$ magnification in case 3 from the biopsied skin lesions show collections of polymorphs admixed with fibrin and multiple round to oval yeast with occasional budding (A). Broad based budding yeasts are seen on GMS stain (B)

Conventional MRI findings are nonspecific and are seen in tuberculomas and pyogenic abscesses. Luthra *et al.* reported in their study that in 100% of the pyogenic and 90.9% of the tubercular abscesses, the outer margin of the wall was either smooth or lobulated, as compared to the fungal lesions which had crenated walls in 50% of the lesions. They postulated that intracavitary projections with restricted diffusion may correspond to the fungal hyphae.^[17] Hence, these intracavitary projections differentiate the fungal lesion from tuberculoma and NCC.

MRS findings are nonspecific and can be seen in other fungal infections like *Aspergillus*, *Candida*, and mucormycosis.^[18,19] Vachhani *et al.* noticed peaks at 3.6–3.8 ppm over the enhancing lesion in the left parietal lobe.^[18] To our knowledge, this is the second case (series) in literature, wherein presence of trehalose peak during MRS study in cranial blastomycosis has been described.

Antifungal agents are the primary treatment for systemic blastomycosis including CNS disease without discrete lesions. In 2008, the Infectious Disease Society of America recommended guidelines for the treatment of blastomycosis. For CNS blastomycosis, the recommendation is lipid amphotericin B 5 mg/kg/day for 4–6 weeks followed by fluconazole 800 mg/day or itraconazole 200 mg for 2 or 3 times a day or voriconazole 200–400 mg twice a day, for at least 12 months and until resolution of CSF abnormalities.^[20] Recently, voriconazole has been favored in place of itraconazole due to increased CNS penetration.^[21] Surgical resection of the lesions provides relief of mass effect, as well as definitive histopathological diagnosis. Indications for surgical management include mass lesions with neurologic deficits, lesions of uncertain etiology, and osteomyelitis of the skull and spine. Surgical resection is followed by mandatory antifungal therapy.^[9]

Financial support and sponsorship

Nil.

Conflicts of interest

There are no conflicts of interest.

References

- Ostrow TD, Hudgins PA. Magnetic resonance imaging of intracranial fungal infections. *Top Magn Reson Imaging* 1994;6:22-31.
- Scott AD, Dhir A. Case of the month #175: Intracranial blastomycosis. *Can Assoc Radiol J* 2012;63:73-6.
- McKinnell JA, Pappas PG. Blastomycosis: New insights into diagnosis, prevention, and treatment. *Clin Chest Med* 2009;30:227-39, v.
- Fetter BF, Klintworth GK, Hendry WS. *Mycoses of the Central Nervous System*. Baltimore: Williams and Wilkins; 1967.
- Wheat J. Endemic mycoses in AIDS: A clinical review. *Clin Microbiol Rev* 1995;8:146-59.
- Bradsher RW, Chapman SW, Pappas PG. Blastomycosis. *Infect Dis Clin North Am* 2003;17:21-40, vii.
- Bariola JR, Perry P, Pappas PG, Proia L, Shealey W, Wright PW, *et al.* Blastomycosis of the central nervous system: A multicenter review of diagnosis and treatment in the modern era. *Clin Infect Dis* 2010;50:797-804.
- Munich SA, Johnson AK, Ahuja SK, Venizelos A, Byrne RW. Large cerebellar mass lesion: A rare intracranial manifestation of blastomycosis. *Surg Neurol Int* 2013;4:141.
- Ward BA, Parent AD, Raila F. Indications for the surgical management of central nervous system blastomycosis. *Surg Neurol* 1995;43:379-88.
- Jain KK, Mittal SK, Kumar S, Gupta RK. Imaging features of central nervous system fungal infections. *Neurol India* 2007;55:241-50.
- Akture E, Salamat S, Baskaya MK. Intracranial blastomycosis presenting as an enhancing cerebellopontine mass. *Turk Neurosurg* 2013;23:252-5.
- Wylen EL, Nanda A. *Blastomyces dermatitidis* occurring as an isolated cerebellar mass. *Neurosurg Rev* 1999;22:152-4.
- Kale H, Narlawar R, Maheswari S, Desai S, Kohli A. CNS blastomycosis, mimic of meningioma. *Indian J Radiol Imaging* 2002;12:483-4.
- Chander B, Deb P, Sarkar C, Garg A, Mehta VS, Sharma MC. Cerebral blastomycosis: A case report. *Indian J Pathol Microbiol* 2007;50:821-4.
- Kim SW, Kim MK, Oh SM, Park SH. Racemose cysticercosis in the cerebellar hemisphere. *J Korean Neurosurg Soc* 2010;48:59-61.
- Mohazab HR, Langer BG, Ramsey RG. Intracranial blastomycosis presenting as a suprasellar mass: MR findings. *J Comput Assist Tomogr* 1997;21:845-7.
- Luthra G, Parihar A, Nath K, Jaiswal S, Prasad KN, Husain N, *et al.* Comparative evaluation of fungal, tubercular, and pyogenic brain abscesses with conventional and diffusion MR imaging and proton MR spectroscopy. *AJNR Am J Neuroradiol* 2007;28:1332-8.
- Vachhani JA, Lee WC, Desanto JR, Tsung AJ. Magnetic resonance spectroscopy imaging characteristics of cerebral blastomycosis. *Surg Neurol Int* 2014;5:80.
- Siegal JA, Cacayorinb ED, Nassif AS, Rizk D, Galambos C, Levy B, *et al.* Cerebral mucormycosis: Proton MR spectroscopy and MR imaging. *Magn Reson Imaging* 2000;18:915-20.
- Chapman SW, Dismukes WE, Proia LA, Bradsher RW, Pappas PG, Threlkeld MG, *et al.* Clinical practice guidelines for the management of blastomycosis: 2008 update by the Infectious Diseases Society of America. *Clin Infect Dis* 2008;46:1801-12.
- Lutsar I, Roffey S, Troke P. Voriconazole concentrations in the cerebrospinal fluid and brain tissue of guinea pigs and immunocompromised patients. *Clin Infect Dis* 2003;37:728-32.