

# Characterization of lesions in dense breasts: Does tomosynthesis help?

Krithika Rangarajan, Smriti Hari, Sanjay Thulkar, Sanjay Sharma, Anurag Srivastava<sup>1</sup>, Rajinder Parshad<sup>1</sup>

Departments of Radiodiagnosis and <sup>1</sup>Surgery, All India Institute of Medical Sciences, New Delhi, India

**Correspondence:** Dr. Smriti Hari, Department of Radiodiagnosis, All India Institute of Medical Sciences, New Delhi, India.  
E-mail: drsmritihari@gmail.com

## Abstract

**Context:** Mammography in dense breasts is challenging due to lesion obscuration by tissue overlap. Does tomosynthesis offers a solution? **Aims:** To study the impact of digital breast tomosynthesis (DBT) in characterizing lesions in breasts of different mammographic densities. **Settings and Design:** Prospective blinded study comparing mammography in two views with Mammography + Tomosynthesis. **Methods and Material:** Tomosynthesis was performed in 199 patients who were assigned Breast imaging reporting and data system (BIRADS) categories 0, 3, 4, or 5 on two-dimensional (2D) mammogram. Mammograms were first categorized into one of 4 mammographic breast densities in accordance with the American College of Radiology (ACR). Three radiologists independently analyzed these images and assigned a BIRADS category first based on 2D mammogram alone, and then assigned a fresh BIRADS category after taking mammography and tomosynthesis into consideration. A composite gold-standard was used in the study (histopathology, ultrasound, follow-up mammogram, magnetic resonance imaging). Each lesion was categorized into 3 groups—superior categorization with DBT, no change in BIRADS, or inferior BIRADS category based on comparison with the gold-standard. The percentage of lesions in each group was calculated for different breast densities. **Results:** There were 260 lesions (ages 28–85). Overall, superior categorization was seen in 21.2% of our readings on addition of DBT to mammography. DBT was most useful in ACR Densities 3 and 4 breasts where it led to more appropriate categorization in 27 and 42% of lesions, respectively. DBT also increased diagnostic confidence in 54.5 and 63.6% of lesions in ACR Densities 3 and 4, respectively. **Conclusions:** In a diagnostic setting, the utility of tomosynthesis increases with increasing breast density. This helps in identifying the sub category of patients where DBT can actually change management.

**Key words:** Breast cancer; dense breasts; digital breast tomosynthesis

## Introduction

Mammographic breast density has been shown to be associated with an increased incidence of breast cancer.<sup>[1-3]</sup> In addition, the dense breast tissue decreases the visibility of lesions on mammography. Therefore, the sensitivity and specificity of mammography is lower in patients with dense breasts.<sup>[4,5]</sup> Screening mammography has been shown conclusively to reduce mortality from breast cancer

in several randomized trials.<sup>[6-8]</sup> However, studies have reported the sensitivity of mammography to be as low as 62% in extremely dense breasts.<sup>[5]</sup> Statistics from the American Cancer Society show the median age of breast cancer to be 61 years.<sup>[9]</sup> Statistics from India are mostly sparse; a study reported the average age of patients with breast cancer at presentation to be 47.8 years, almost a decade earlier than their western counterparts.<sup>[10-12]</sup>

### Access this article online

#### Quick Response Code:



**Website:**  
www.ijri.org

**DOI:**  
10.4103/0971-3026.184416

This is an open access article distributed under the terms of the Creative Commons Attribution-NonCommercial-ShareAlike 3.0 License, which allows others to remix, tweak, and build upon the work non-commercially, as long as the author is credited and the new creations are licensed under the identical terms.

**For reprints contact:** reprints@medknow.com

**Cite this article as:** Rangarajan K, Hari S, Thulkar S, Sharma S, Srivastava A, Parshad R. Characterization of lesions in dense breasts: Does tomosynthesis help?. Indian J Radiol Imaging 2016;26:210-5.

Digital breast tomosynthesis (DBT) attains great relevance in this context because these young breasts tend to be mammographically dense,<sup>[13]</sup> (ACR category 3 and 4) and have a greater chance of tissue overlap leading to a loss of sensitivity as well as specificity.

The introduction of DBT potentially provides a solution to this problem by removing overlap of fibroglandular tissue. The principle of tomosynthesis involves obtaining low-dose projections at different tube positions as the mammographic tube rotates along a limited arc around the compressed breast. The images can then be reconstructed, much like images obtained from computed tomography (CT), thus resolving objects along the Z-axis. Therefore, overlapping breast tissue would potentially be separated and seen on different slices.

On the contrary, unlike CT, where the tube moves an entire 180° around the patient, in DBT there is only a limited arc of motion of the tube around the patient. Therefore, the determination of depth of an object within the breast on tomosynthesis can only be approximate.

There have been several studies evaluating tomosynthesis in the screening population where it has been shown to reduce recall rates<sup>[14-16]</sup> and increase the sensitivity and specificity for breast cancer detection.<sup>[17]</sup> The use of DBT has been shown to increase the diagnostic confidence of radiologists in lesion detection and margin characterization.<sup>[18,19]</sup> Conflicting results have been seen<sup>[20]</sup> with some studies indicating no clear advantage over mammography on addition of tomosynthesis.<sup>[21,22]</sup> Mun *et al.* in their study found that addition of tomosynthesis significantly helped the assessment of lesion extent in dense breasts.<sup>[13]</sup> Haas *et al.* also observed a greater reduction in recall rates in dense breasts in comparison with fatty breasts.<sup>[14]</sup> The cost-effectiveness of adding tomosynthesis to mammography has also been studied in dense breasts.<sup>[23]</sup> There has however been no study assessing the effect of breast density on the diagnostic accuracy of breast tomosynthesis.

The purpose of this study was to study the effect of breast density on the performance of tomosynthesis. Young patients are known to have denser breasts. If tomosynthesis is found useful, it would make a strong case for subjecting this subset of patients to this investigation, albeit at the risk of the slightly increased radiation dose.

## Subjects and Methods

### Patient population

The study was conducted from January 2012 to Dec 2013 after obtaining institutional ethical clearance. All patients provided an informed consent. The study included patients who presented to the surgical clinics of the institution,

and after examination by an experienced surgeon were referred for mammography. A two dimensional (2D) digital mammogram were obtained in all these patients, which were immediately analyzed by a radiologist (who was not a part of the study). All patients were classified as breast imaging reporting and data system (BIRADS) 0, 3, 4, or 5 and then underwent tomosynthesis. The median age of patients in the study was 45 (age range: 28–80 years). There were 199 patients and 260 lesions. Of the 260 lesions, there were 166 biopsy-proven malignancies. We used a composite gold-standard. Results of histopathology were used wherever available. Pooled results of other investigations such as ultrasound, magnetic resonance imaging, and follow-up mammogram (after an interval of 6 months) were used to establish ground reality in other patients where these were not available.

### Image acquisition

Mammography and tomosynthesis were performed on the Full-Field Digital Mammography (Unit Selenia Dimensions, Hologic, Bedford, USA). Mammogram was performed in craniocaudal (CC) and mediolateral-oblique (MLO) views. DBT was performed only in MLO view. Tomosynthesis was performed in one view only for two reasons; a) tomosynthesis gives a depth perception, and therefore we felt that two views may not be essential and b) to minimize radiation exposure, the breast being an exquisitely radiation-sensitive organ. MLO view was chosen because 90% of the breast parenchyma is included in this view.

### Reader study

The study included three radiologists with 18, 8, and 8 years of experience in breast radiology. All readers were blinded to the gold standard. They were first presented the CC and MLO view mammograms and asked to mark the region of abnormality using a circular region of interest (ROI) available on the console. They were then asked to assign a BIRADS category to each lesion they noted. Then, they were presented the tomosynthesis images and asked to locate the lesion and assign it a BIRADS category, as they had done for the DM images. A fourth radiologist (who was not involved in the blinded readings) then compiled the data. Breast density was determined by a nonparticipating radiologist on the DM images and classified into ACR categories 1–4. ACR 1 refers to breasts with <25% fibroglandular tissue, ACR 2 with 25–50% fibroglandular tissue, ACR 3 with 50–75% fibroglandular tissue, and ACR 4 with >75% fibroglandular tissue. The readers were also asked to subjectively rate the change in confidence on addition of DBT.

### Statistical analysis

Abnormalities indicated by different readers were considered to represent the same lesion if there was significant overlap between their ROIs, as determined visually. The BIRADS assigned on DM and DBT + DM were compared with the gold-standard. Change in the

BIRADS category was considered to be appropriate if, for a malignant lesion, the addition of DBT upgraded the BIRADS to 4 or 5, or for a benign lesion, the addition of DBT downgraded the BIRADS to 1, 2, or 3. Percentage of lesions where DBT led to superior categorization, no change, or inferior categorization were then calculated for each breast density. The subjective ratings assigned on addition of DBT were also classified into increased confidence, no change in confidence, and decreased confidence.

## Results

The median age of patients in the study was 45 (age range 28–80 years). The age distribution of patients is summarized in Table 1.

With advancing age, the mammographic density was found to change from ACR category 4 to ACR category 1, as expected, due to the involution of fibroglandular tissue. The age distribution of mammographic breast density is summarized in Table 2.

The most predominant breast densities were ACR category 2 and 3. The summary of the number of lesions analyzed in each ACR-breast density category is given in Table 3.

The three readers independently analyzed the images and assigned BIRADS categories on DM and DM + DBT, as described above. There was excellent interobserver agreement in the BIRADS assigned both on DM alone, as well as on DM + DBT.

On comparison with the gold-standard, the categorization on DM + DBT was considered superior, equal, or inferior to DM alone, as summarized in Table 4 and Figure 1.

The change in confidence on the addition of DBT to DM in different ACR-density categories is summarized in Table 5 and Figure 2.

## Discussion

DBT has been seen to show better depiction of breast architecture, glandular tissue, and fat lobules, hence achieving better BIRADS categorization of lesions.<sup>[24]</sup> This study showed that the percentage of cases where DBT led to better BIRADS categorization was higher in patients with dense breasts. The percentage of cases where DBT led to better classification increased progressively from 19% in ACR density-1 breasts to 42.4% in ACR density-4 breasts. This is primarily due to the ability of DBT to reduce tissue overlap in dense breasts.<sup>[25]</sup> DM was sufficient to assess lesions in ACR 1 and 2 (fatty) breasts because the margins of the mass could easily be delineated against the radiolucent fat; therefore, in most of these cases, DBT had nothing to add. DBT helped in the characterization of architectural

**Table 1: Distribution of patients in different age groups**

Age group (in years)	Percentage
<35	15.3
36-45	36.78
46-55	26.8
56-65	14.5
>66	6.5

**Table 2: Mean age of patients with specific breast parenchymal densities on mammography**

ACR density	Mean age
1	55
2	49
3	43
4	36

ACR: American College of Radiology

**Table 3: Distribution of lesions according to the American College of Radiology density of the breast**

ACR density category	Percentage (number) of lesions analyzed
ACR density 1	10.7 (28 lesions)
ACR density 2	45.7 (119 lesions)
ACR density 3	39.2 (102 lesions)
ACR density 4	4.2 (11 lesions)

ACR: American College of Radiology

distortions even in these cases where it helped separate architectural distortion from overlap [Figures 3 and 4].

As the ACR density increased, the proportion of patients where DBT led to superior BIRADS categorization increased. This increased to 34.9 in ACR 3 and 42.4% in ACR 4 breasts. In the free-text comments, the readers noted a better delineation of margins of the mass on addition of DBT. In most cases, the superior categorization was due to the conversion of BIRADS 0 into a definitive BIRADS category on addition of DBT [Figure 5]. Similar appropriate classification of BIRADS 0 lesions into definitive BIRADS categories were also seen by Yang *et al.* in their study.<sup>[26]</sup> In another study by Margolies *et al.*, it was seen that the probability for change in management with addition of tomosynthesis was higher in patients with dense breasts (13%) as compared with 9% in other patients.<sup>[27]</sup>

In addition, in the subjective ratings, it was seen that DBT was most useful in dense breasts. The proportion of readings where addition of DBT increased diagnostic confidence increased from 27.3% in ACR density-1 breasts to 63.6% in ACR-4 breasts. As noted in the free-text comments, the reasons for the increased confidence on addition of tomosynthesis was clear visualization of margins on DBT due to the separation of overlapping fibroglandular tissue [Figure 6]. Hakim *et al.* in their study perceived the combination of DBT with DM to be better for diagnosis in 50% in comparison to DM with additional

**Table 4: Change in BIRADS category with addition of digital breast tomosynthesis in breasts of different densities**

	ACR 1	ACR 2	ACR 3	ACR 4
Inferior categorization	0.0	0.8	0.0	0.0
No change	80.9	81.5	64.0	57.5
Superior categorization	19.0	16.9	34.9	42.4

BIRADS: Breast imaging reporting and data system, ACR: American College of Radiology

**Table 5: Change in confidence on addition of digital breast tomosynthesis in breasts of different densities**

	ACR 1	ACR 2	ACR 3	ACR 4
Decreased confidence	3.5	1.6	3.9	0
No change	69.1	64.2	40.5	36.3
Increased confidence	27.3	33.4	54.5	63.6

ACR: American College of Radiology

views. In 12%, the readers felt confident in eliminating ultrasound in the work-up of these patients.<sup>[28]</sup> They did not, however, stratify their results according to the ACR breast density of patients.

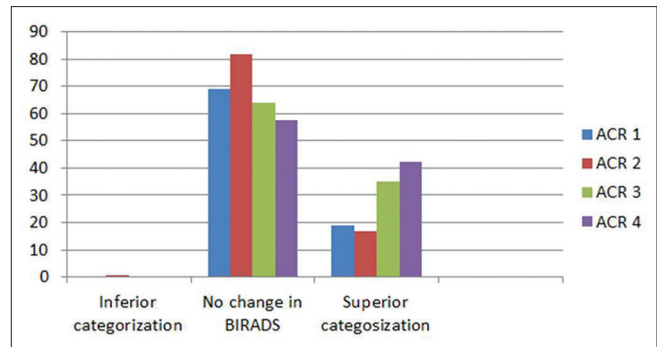
A limitation of our study was that we had a relatively small number of patients in the ACR density-4 category (11 patients), and a larger study would thus be required to establish results in this regard.

There was 1 patient with an ACR density-2 breast where the addition of tomosynthesis led to a wrong downgradation of BIRADS category. The mass with obscured margins on DM was categorized as BIRADS 4. The addition of DBT, however, made the margins appear circumscribed and the BIRADS was downgraded to 3 [Figure 7]. An infiltrating ductal carcinoma was found on biopsy. All 3 readers perceived an increased confidence in this case, however, this was reclassified into the category of decreased confidence for the purpose of statistical analysis because the perceived increase in confidence was in the wrong direction.

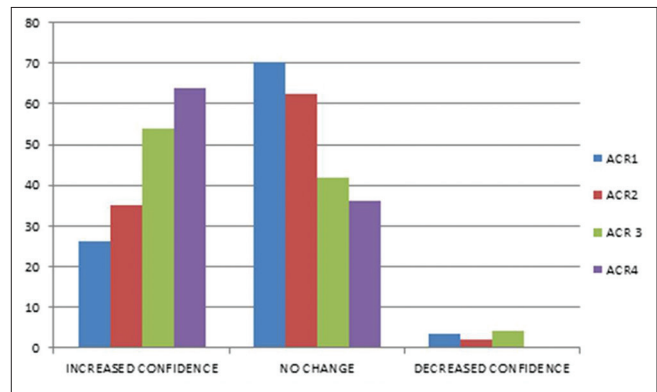
The addition of DBT in young patients may be questionable due to the risk of increased radiation dose. However, it has been seen that by itself, the dose of DBT is comparable to Full Field Digital Mammography (FFDM), and may even be lower in thick breasts.<sup>[29]</sup> Our study, however, shows that DBT is most useful in this population due to the higher density of breasts in younger patients. The average age of patients with ACR density 3 and 4 breasts (where DBT was found most useful) were 43 and 36, respectively, showing that it may be particularly valuable in women below 45 years of age.

### Conclusion

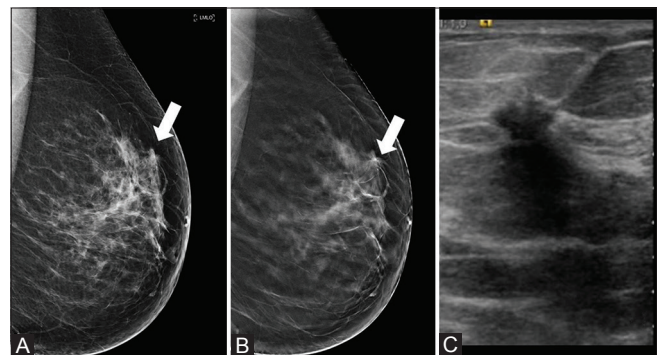
In this study, two views DM (CC + MLO) were compared with DBT (in MLO view) + DM in breasts of various breast



**Figure 1:** Change in BIRADS category with addition of digital breast tomosynthesis in breasts of different densities



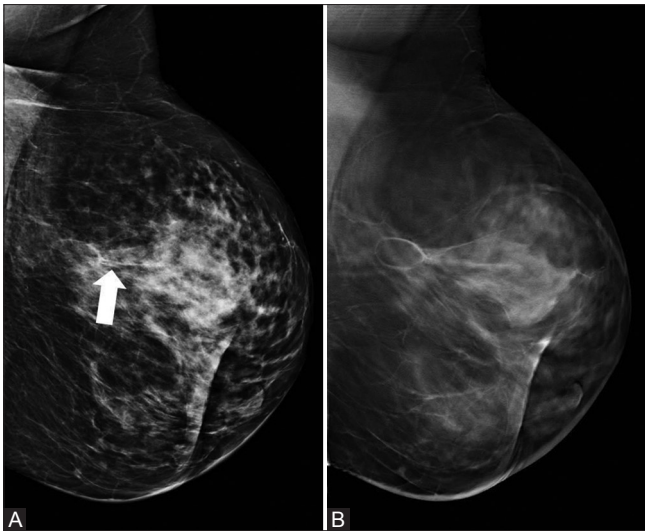
**Figure 2:** Change in confidence on addition of digital breast tomosynthesis in breasts of different densities



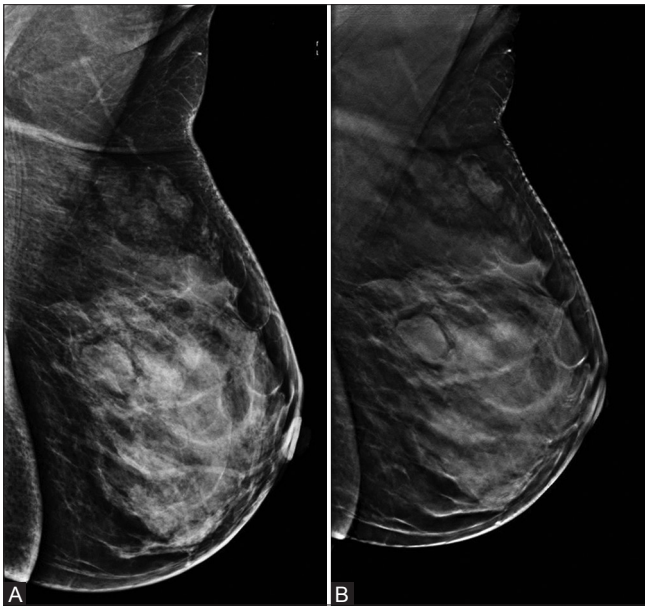
**Figure 3 (A-C):** Breast tomosynthesis in American College of Radiology density 1 breast (A) two-dimensional (2D) mediolateral-oblique (MLO) view of the left breast shows an area of subtle architectural distortion (arrow) assigned a BIRADS 0 on 2D mammogram. (B) 1 mm digital tomosynthesis slice of the same patient in MLO view shows a spiculated mass measuring 6 mm, which was confirmed on targeted ultrasound. (C) The mass was malignant on biopsy

densities. It was observed that the addition of DBT led to a more appropriate BIRADS categorization, particularly in breasts of higher densities (ACR 3 and 4). DBT also increased the diagnostic confidence of the reader, which was also particularly marked in dense breasts. The implication of this study is that DBT may be particularly useful in young patients (<45 years) who have dense breasts, despite the slight increase in radiation dose.



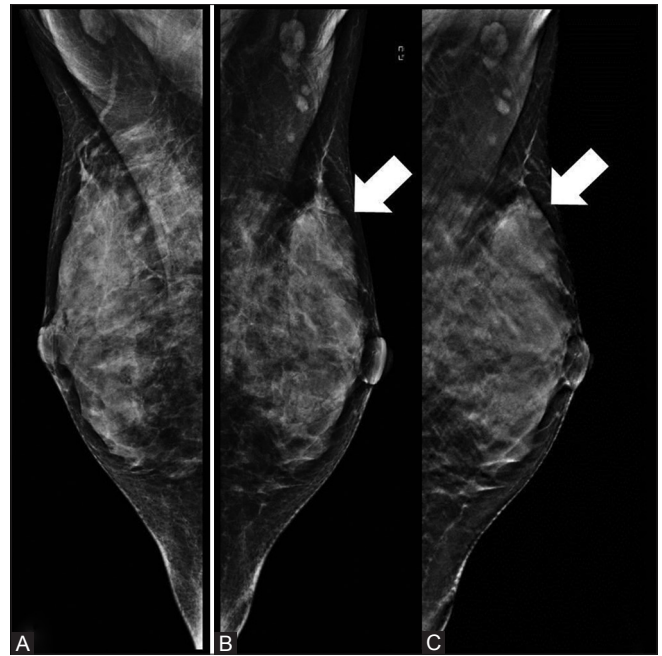


**Figure 4 (A and B):** Tomosynthesis in American College of Radiology density 2 breast. (A) Suspicious architectural distortion (arrow) in a patient who had undergone breast conservation surgery was classified as BIRADS 0 on mammogram (B) 1 mm digital tomosynthesis slice of the same patient in mediolateral-oblique view clearly shows a central lucency, suggestive of fat necrosis and postoperative changes. This was downgraded to BIRADS 2

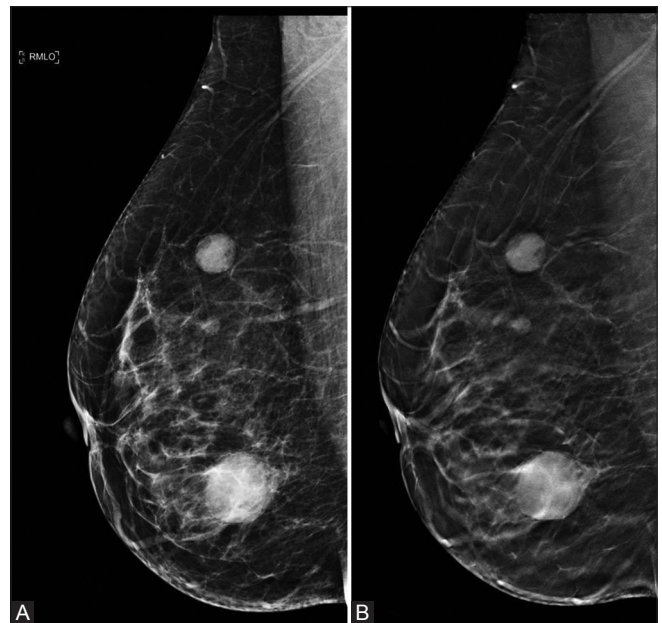


**Figure 6 (A and B):** Breast tomosynthesis increases diagnostic confidence (A) Mediolateral-oblique (MLO) view of the left breast (American College of Radiology density 3) shows a posteriorly located lobulated mass. The margins are partially obscured, it was assigned BIRADS 3 on two-dimensional mammogram (B) 1 mm digital tomosynthesis slice of the same patient in MLO view removes tissue overlap enabling complete delineation of the margins, which appears lobulated. BIRADS category remained 3, but the radiologists' diagnostic confidence was increased

**Financial support and sponsorship**  
Nil.



**Figure 5 (A-C):** Tomosynthesis in American College of Radiology 4 breast. (A, B) Right and left mediolateral-oblique views of the breast show only a slight contour bulge in the left breast superiorly (arrow) categorized as BIRADS 0. (C) A section of tomosynthesis clearly shows the microlobulated margins; BIRADS was changed to 5



**Figure 7 (A and B):** Tomosynthesis leads to the wrong categorization of right MLO views of mammography (A) shows 3 lesions. The two in the superior quadrant show circumscribed margins and were categorized as BIRADS 3 on both two-dimensional mammogram and 1 mm digital tomosynthesis slice (B) However, the lesion in the inferior breast was categorized BIRADS 4 on mammography. This was downgraded to 3 on tomosynthesis. The lesion was, however, malignant on biopsy

**Conflicts of interest**

There are no conflicts of interest.

**References**

- McCormack VA, dos Santos Silva I. Breast density and parenchymal patterns as markers of breast cancer risk: A meta-analysis. *Cancer Epidemiol Biomarkers Prev* 2006;15:1159-69.
- Boyd NF, Martin LJ, Yaffe MJ, Minkin S. Mammographic density and breast cancer risk: Current understanding and future prospects. *Breast Cancer Res BCR* 2011;13:223.
- Bertrand KA, Tamimi RM, Scott CG, Jensen MR, Pankratz V, Visscher D, *et al.* Mammographic density and risk of breast cancer by age and tumor characteristics. *Breast Cancer Res* 2013;15:R104.
- Kerlikowske K, Grady D, Barclay J, Sickles EA, Ernster V. Effect of age, breast density, and family history on the sensitivity of first screening mammography. *J Am Med Assoc* 1996;276:33-8.
- Carney PA, Miglioretti DL, Yankaskas BC, Kerlikowske K, Rosenberg R, Rutter CM, *et al.* Individual and combined effects of age, breast density, and hormone replacement therapy use on the accuracy of screening mammography. *Ann Intern Med* 2003;138:168-75.
- Nyström L, Andersson I, Bjurstram N, Frisell J, Nordenskjöld B, Rutqvist LE. Long-term effects of mammography screening: Updated overview of the Swedish randomised trials. *Lancet* 2002;16;359:909-19. Erratum in *Lancet* 2002;360:724.
- Tabár L, Fagerberg CJ, Gad A, Baldetorp L, Holmberg LH, Gröntoft O, *et al.* Reduction in mortality from breast cancer after mass screening with mammography. Randomised trial from the Breast Cancer Screening Working Group of the Swedish National Board of Health and Welfare. *Lancet* 1985;1:829-32.
- Lewin JM, D'Orsi CJ, Hendrick RE. Digital mammography. *Radiol Clin* 2004;42:871-84.
- American Cancer Society. *Breast Cancer Facts & Figures 2011-2012*. Atlanta: American Cancer Society, Inc. [cited 2013 Nov 24]. Available from: <http://www.cancer.org/acs/groups/content/epidemiologysurveillance/documents/document/acspc-030975.pdf>.
- Saxena S, Rekhi B, Bansal A, Bagga A, Chintamani, Murthy NS. Clinico-morphological patterns of breast cancer including family history in a New Delhi hospital, India--A cross-sectional study. *World J Surg Oncol* 2005;3:67.
- Raina V, Bhutani M, Bedi R, Sharma A, Deo SV, Shukla NK, *et al.* Clinical features and prognostic factors of early breast cancer at a major cancer center in North India. *Indian J Cancer* 2005;42:40-5.
- Deo SVS. Challenges in the treatment of breast cancer in developing countries. *Natl Med J India* 2010;23:129-31.
- Mun HS, Kim HH, Shin HJ, Cha JH, Ruppel PL, Oh HY, *et al.* Assessment of extent of breast cancer: Comparison between digital breast tomosynthesis and full-field digital mammography. *Clin Radiol* 2013;68:1254-9.
- Haas BM, Kalra V, Geisel J, Raghu M, Durand M, Philpotts LE. Comparison of Tomosynthesis Plus Digital Mammography and Digital Mammography alone for Breast Cancer Screening. *Radiology* 2013;269:694-700.
- Gur D, Abrams GS, Chough DM, Ganott MA, Hakim CM, Perrin RL, *et al.* Digital breast tomosynthesis: Observer performance study. *AJR Am J Roentgenol* 2009;193:586-91.
- Poplack SP, Tosteson TD, Kogel CA, Nagy HM. Digital breast tomosynthesis: Initial experience in 98 women with abnormal digital screening mammography. *AJR Am J Roentgenol* 2007;189:616-23.
- Lei J, Yang P, Zhang L, Wang Y, Yang K. Diagnostic accuracy of digital breast tomosynthesis versus digital mammography for benign and malignant lesions in breasts: A meta-analysis. *Eur Radiol* 2014;24:595-602.
- Poplack SP, Tosteson TD, Kogel CA, Nagy HM. Digital breast tomosynthesis: Initial experience in 98 women with abnormal digital screening mammography. *AJR Am J Roentgenol* 2007;189:616-23.
- Yang TL, Liang HL, Chou CP, Huang JS, Pan HB. The adjunctive digital breast tomosynthesis in diagnosis of breast cancer. *BioMed Res Int* 2013;2013:597253.
- Lourenco AP, Barry-Brooks M, Baird GL, Tuttle A, Mainiero MB. Changes in recall type and patient treatment following implementation of screening digital breast tomosynthesis. *Radiology* 2015;274:337-42.
- Good WF, Abrams GS, Catullo VJ, Chough DM, Ganott MA, Hakim CM, *et al.* Digital breast tomosynthesis: A pilot observer study. *AJR Am J Roentgenol* 2008;190:865-9.
- Teertstra HJ, Loo CE, van den Bosch MAAJ, van Tinteren H, Rutgers EJT, Muller SH, *et al.* Breast tomosynthesis in clinical practice: Initial results. *Eur Radiol* 2010;20:16-24.
- Lee CI, Cevik M, Alagoz O, Sprague BL, Tosteson ANA, Miglioretti DL, *et al.* Comparative effectiveness of combined digital mammography and tomosynthesis screening for women with dense breasts. *Radiology* 2015;274:772-80.
- Cai SQ, Yan JX, Chen QS, Huang ML, Cai DL. Significance and Application of Digital Breast Tomosynthesis for the BI-RADS Classification of Breast Cancer. *Asian Pac J Cancer Prev* 2015;16:4109-14.
- Destounis SV, Morgan R, Arieno A. Screening for dense breasts: Digital breast tomosynthesis. *AJR Am J Roentgenol* 2015;204:261-4.
- Yang TL, Liang HL, Chou CP, Huang JS, Pan HB. The adjunctive digital breast tomosynthesis in diagnosis of breast cancer. *BioMed Res Int* 2013;2013:597253.
- Margolies L, Cohen A, Sonnenblick E, Mandeli J, Schmidt PH, Szabo J, *et al.* Digital breast tomosynthesis changes management in patients seen at a tertiary care breast center. *ISRN Radiol* 2014;2014:658929.
- Hakim CM, Chough DM, Ganott MA, Sumkin JH, Zuley ML, Gur D. Digital breast tomosynthesis in the diagnostic environment: A subjective side-by-side review. *AJR Am J Roentgenol* 2010;195:W172-6.
- Paulis LE, Lobbes MBI, Lalji UC, Gelissen N, Bouwman RW, Wildberger JE, *et al.* Radiation Exposure of Digital Breast Tomosynthesis Using an Antiscatter Grid Compared With Full-Field Digital Mammography. *Invest Radiol* 2015;50:679-85.