

Percutaneous epidural drainage through a burr hole

Priscila M Falsarella, Rafael D Rocha, Rodrigo G Garcia

Department of Interventional Radiology, Hospital Israelita Albert Einstein, São Paulo, Brazil

Correspondence: Mrs. Priscila M Falsarella, Department of Interventional Radiology, Hospital Israelita Albert Einstein, Morumbi, São Paulo, Brazil. E-mail: primina@gmail.com

Abstract

Intracranial extradural collection may cause an increase in intracranial pressure, requiring rapid emergency treatment to reduce morbidity and mortality. We described an alternative CT-guided percutaneous access for extradural collection drainage. We report a case of a patient with previous craniectomy for meningioma resection who presented to the Emergency Department with symptoms of intracranial hypertension. Brains CT showed a extradural collection with subfalcine herniation. After multidisciplinary discussion a CT-guided percutaneous drainage through previous burr hole was performed. The patient was discharged after 36 hours of admission, without further symptoms. We describe a safe and effective alternative percutaneous access for extradural collection drainage in patients with previous burr hole.

Key words: Burr hole; epidural abscess; percutaneous drainage

Introduction

Intracranial extradural collection are often due to trauma or surgery,^[1] and may cause an increase in intracranial pressure, requiring rapid emergency treatment to reduce morbidity and mortality.^[2] Conventional treatment is decompressive craniectomy performed by neurosurgeons.^[1] The increased use of computed tomography (CT) scans has changed the diagnosis and management of intracranial extradural collection, allowing its early approach.^[3] We described an alternative CT-guided percutaneous access for extradural collection drainage.

Case Report

A 65-year-old male presented to the Emergency Department with headache, dizziness, and a slowly diminishing level

of consciousness. Neurological examination showed mental confusion without motor weakness. The patient had a past medical history of craniectomy for meningioma resection in the left anterior frontal region 6months ago and development of an extradural collection in the postoperative period, which was already treated with two surgical drainage procedures in the last 2months [Figure 1].

Brain CT was immediately performed and showed recurrence of extradural collection (22HU) with subfalcine herniation [Figure 2]. After discussion with neurology and neurosurgery on call team, we decided to perform a percutaneous drainage of epidural collection in the scan room using the prior burr hole, for immediate reduction of the hypertensive patient's symptoms. Therefore, a CT-guided percutaneous drainage was performed under sedation through a previous burr hole. A coaxial bone biopsy system and 13 G × 10 cm (Cook, Inc, Bloomington, IN,

Access this article online

Quick Response Code:



Website:
www.ijri.org

DOI:
10.4103/0971-3026.195778

This is an open access article distributed under the terms of the Creative Commons Attribution-NonCommercial-ShareAlike 3.0 License, which allows others to remix, tweak, and build upon the work non-commercially, as long as the author is credited and the new creations are licensed under the identical terms.

For reprints contact: reprints@medknow.com

Cite this article as: Falsarella PM, Rocha RD, Garcia RG. Percutaneous epidural drainage through a burr hole. Indian J Radiol Imaging 2016;26:469-71.

USA) needle were introduced into the collection [Figure 3]. Approximately 50 ml of yellowish liquid was slowly aspirated to avoid vascular disruption and increase in blood cerebral flow. Control CT scan showed reduction of epidural collection and midline shift [Figure 4]. The patient was discharged after 36 hours of admission, without further symptoms. Three months later, a magnetic resonance

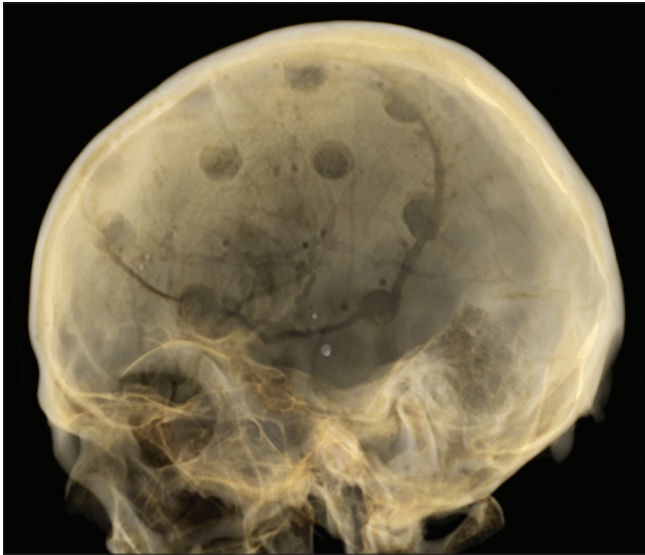


Figure 1: Computed tomography of the brain: Three-dimensional reformation showing previous craniectomy and burr holes

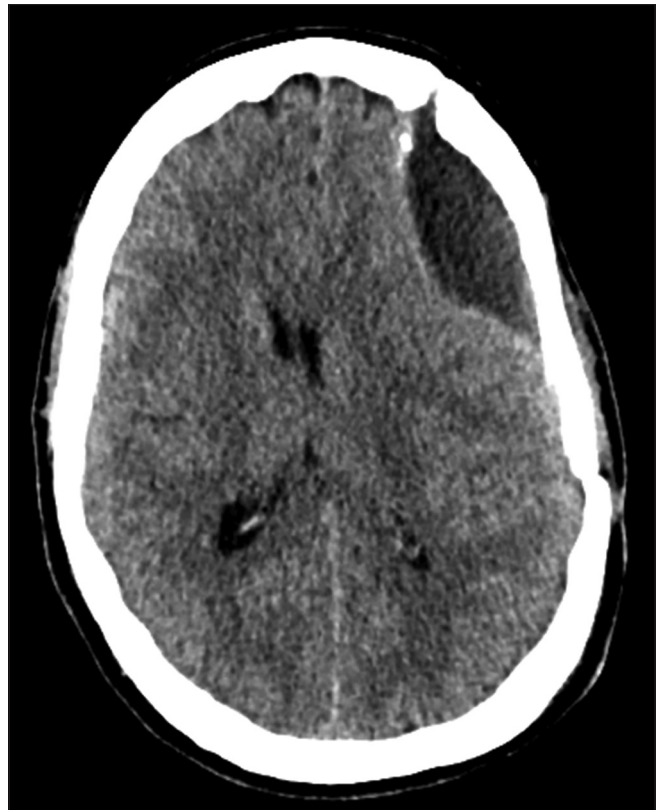

Figure 2: Computed tomography scan of the brain demonstrating recurrence of extradural collection causing subfalcine herniation

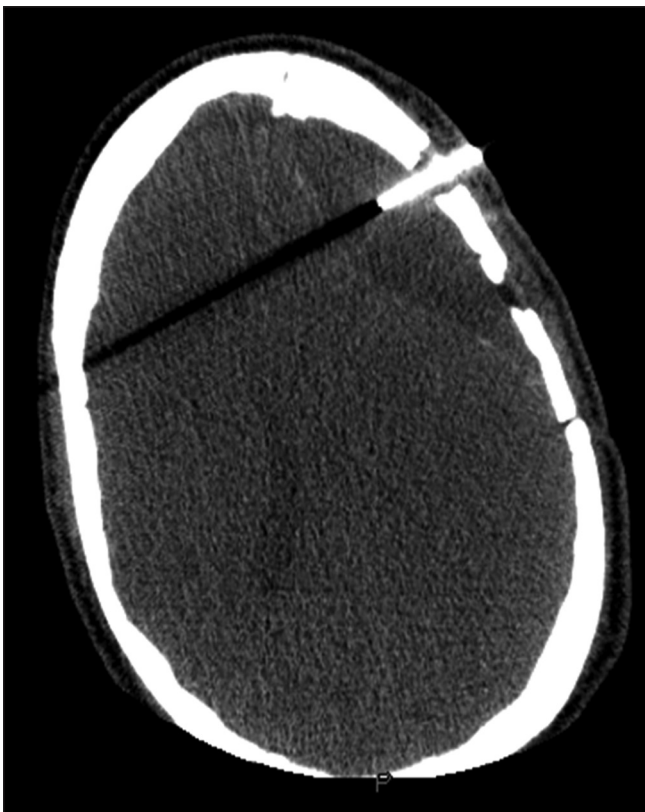

Figure 3: A 13G coaxial bone biopsy system needle was introduced into the collection through a burr hole

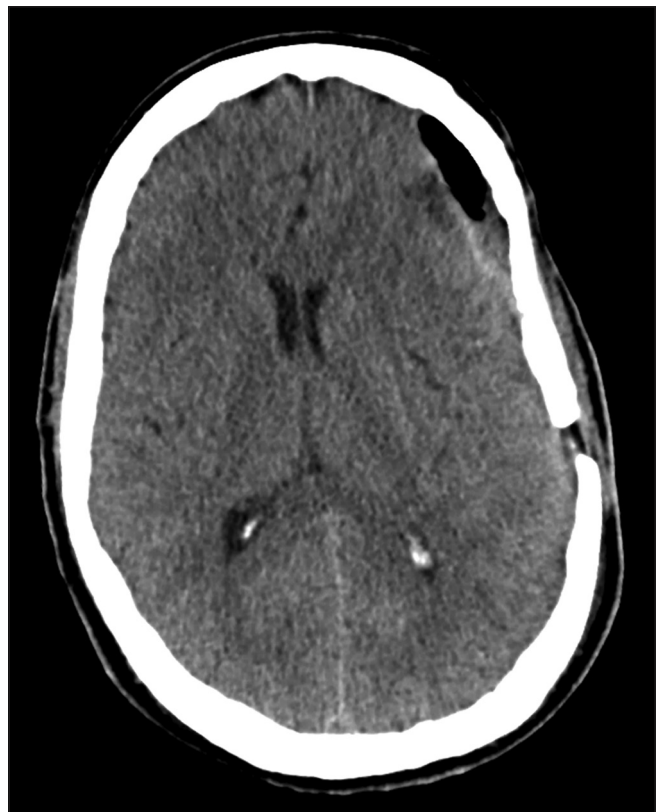

Figure 4: Control computed tomography scan showed small fluid accumulation and pneumocephalus

imaging (MRI) scan demonstrated complete resolution of the collection. After an 18-month follow-up, the patient remains in attendance without any further symptoms.

Discussion

Intracranial extradural collection are often due to trauma or surgery,^[1] and may cause an increase in intracranial pressure, requiring rapid emergency treatment to reduce morbidity and mortality.^[2] The management of extradural collection has changed dramatically in the last decade and the most frequent adoption of nonoperative therapies in the treatment of Intracranial hypertension have reduced the craniotomy rates.^[3,4] The guidelines recommend transfer to neurosurgical centers for patients with extradural collection and compressive symptoms.^[3,4] However, before the transfer, surgical decompression should be performed for deteriorating patients due the risk of additional compromise caused by delays during transport. Xianlin *et al.*,^[5] who analyzed 33 cases of patients undergoing percutaneous intracranial CT-guided collection drainage, observed among others the following advantages: Possibility of performing the procedure under local anesthesia in the CT room in primary hospitals, minimally invasive trauma, short operation trauma, low cost, and short hospital stay. We describe a safe and

effective alternative percutaneous access for extradural collection drainage in patients with a previous burr hole. Emergency doctors in hospitals without neurosurgical facilities could easily perform this procedure.

Financial support and sponsorship

Nil.

Conflicts of interest

There are no conflicts of interest.

References

1. Kim SP, Kang DS, Cheong JH, Kim JH, Song KY, Kong MH. Clinical Analysis of Epidural Fluid Collections as a Complication after Cranioplasty. *J Korean Neurosurg Soc* 2014;56:410-8.
2. Park KJ, Kang SH, Lee HK, Chung YG. Brain Stem Hemorrhage following Burr Hole Drainage for Chronic Subdural Hematoma-Case Report. *Neurol Med Chir* 2009;49:594-7.
3. Deverill J, Aitken LM. Treatment of extradural haemorrhage in Queensland: Interhospital transfer, preoperative delay and clinical outcome. *Emerg Med Australas* 2007;19:325-32.
4. Zakaria Z, Kaliaperumal C, Kaar G, O'Sullivan M, Marks C. Extradural haematoma-To Evacuate or Not? Revisiting treatment guidelines. *Clin Neurol Neurosurg* 2013;115:1201-5.
5. Zhao X, Jiang H, Liu G, Wang T. Efficacy Analysis of 33 Cases with Epidural Hematoma Treated by Brain Puncture Under CT Surveillance. *Turk Neurosurg* 2014;24:323-6.