

01-09

Multifocal Osteoid Osteoma - A Case Report

RM CHANDAK, SV PHATAK, L JAIN, PK KOLWADKAR

Ind J Radiol Imag 2006 16:1:53-54

Key words : Osteoid osteoma

Introduction :

Osteoid osteoma is a common benign lesion consisting of small (upto 2 cms.) nidus of highly vascularized osteoid tissue surrounded by peripheral zone of sclerosis. Only rarely they multifocal. Very few cases have been reported in the literature of multifocal osteoid osteomas (2,3,4). The authors present a case of multifocal osteoid osteoma with two nidi involving the lower shaft of Humerus.

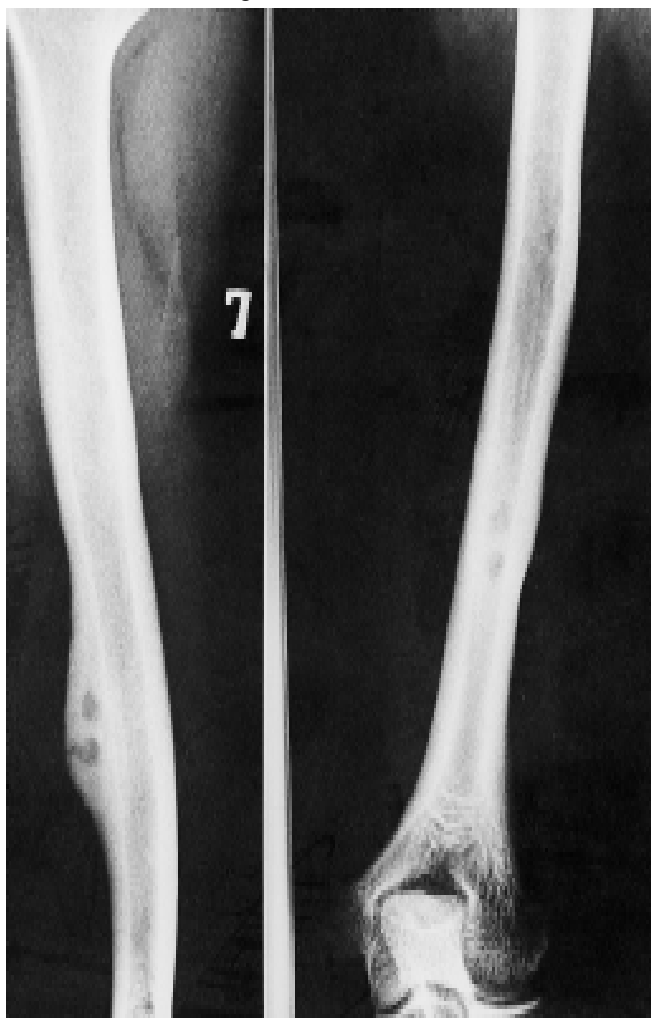

Figure 1. Radiograph humerus showing two lucent lesions.

Case report

A twenty four old man presented with complaints of pain localized to lower third of left arm since one year. He responded well to analgesics but the pain used to recur after a few days. Physical examination and laboratory studies revealed no abnormalities.

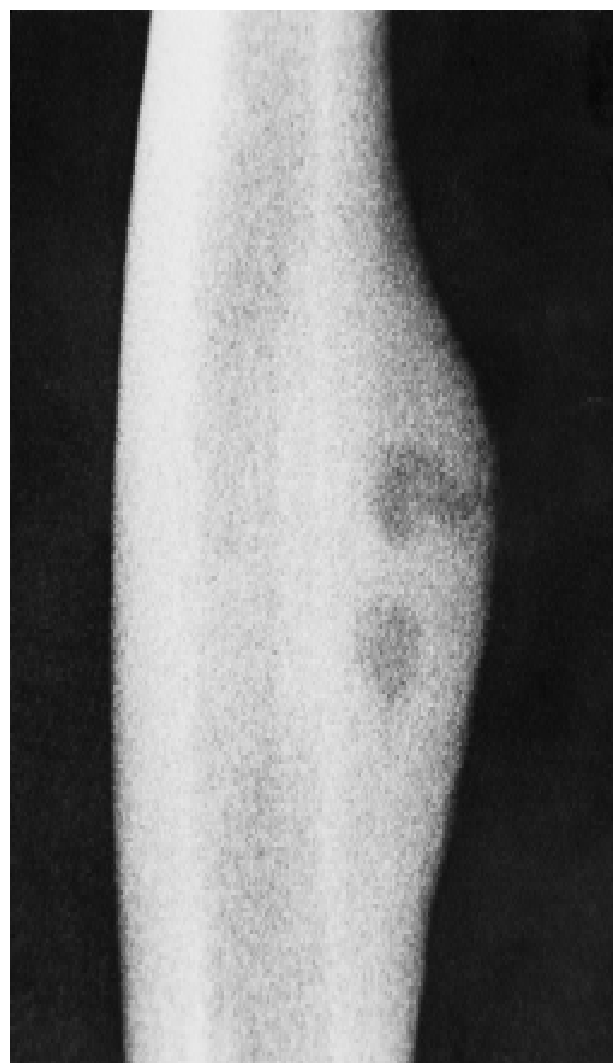


Figure 2. Radiograph humerus showing nidi and periosteal reaction.

From the Chandak Nursing home, Nagpur

Request for Reprints: Dr. R.M. Chandak M.S. (Orthopaedic Surgery), Chandok Nursing Home, 1st floor, Super Market, Sitabuldi, Nagpur-12

Received 17 January 2003; Accepted 10 February 2005

A Radiograph of the left arm shows an area of localized periosteal new bone formation in the lower shaft of humerus along its lateral border. Two lucent areas were noted in this region indicative of nidi. Minimal endosteal thickening was also observed, rest of the humeral shaft appeared normal. Surgical resection of the involved area of the humerus was performed. Two nidi were seen. Microscopic view showed a well developed nidus comprising of thick network of trabeculae of woven bone, partly calcified centrally. Osteoblasts were plump, active and forming prominent rimming of woven bone. Between the woven bone, vascular stroma was present with a few osteoclastic giant cells. Surrounding the nidus sclerotic normal lamellar bone was seen quite abruptly without an interface.

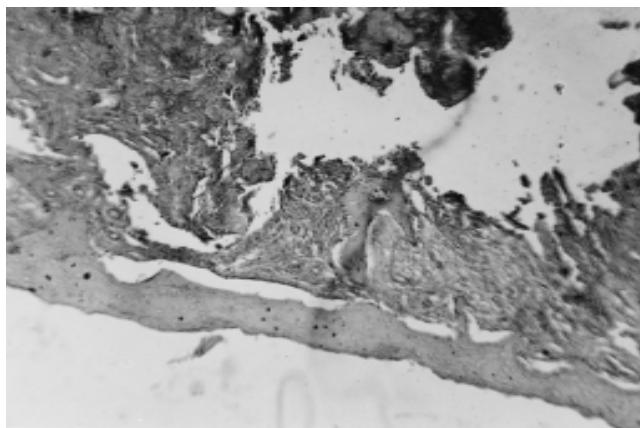


Figure 3. Histopathology of osteoid osteoma.

Discussion

The nidus : The nidus is best seen in the diaphysis where it usually presents as a small lucency or frequently as a mere chink in the bone. The long diameter varies from 0.3 to 2 cms, but rarely it is more than 1 cms. When an osteoid osteoma shows a nidus that measures 2-4 cms in diameter and retains the other attributes of the condition it is a large osteoid osteoma. Whereas if the nidus measures over 4 cms, in diameter it is regarded as a giant sized osteoid osteoma (1).

The core of the nidus is eccentrically placed in respect to long axis of the bone. It does not invade the soft tissue. Approximately half of the nidi are lucent and other contain different patterns of tumor matrix mineralization. If the osteoid tissue is more abundant in central portion of nidus it creates a translucent image, if the reticular calcified bony tissue predominates the image is denser than normal bone. A partly calcified nidus is represented by more distinct flecks of larger masses of increased density creating a 'stippled pattern' when central osteoid area alternates with a reticular one; followed towards periphery by another osteoid area the appearance simulates an annular sequestrum. Occasionally the nidus is completely calcified in which case a uniformly dense center is surrounded by a narrow halo of radiolucency. The nidus may be intramedullary, subcortical, intracortical

or subperiosteal. Rarely it has been seen lying close to the edge of an articular surface in the epiphysis (1). Commonly only one nidus forms but in rare instances an osteoid osteoma may be multifocal. Sherman (1947) found double nidi in neck of femur. Flaherty et al (1956) described one case with three distinct but closely-grouped nidi. Each was identified roentgenologically and histologically. Greenspan et al (1974) reported a case of multifocal osteoid osteoma with three nidi involving distal tibia. Schajowicz and Lemos (1970) in their large series observed one case showing two small nidi adjacent to one another (1).

Kenan S et al (3) also described a case of elliptical multicentric periosteal osteoid osteoma in 1994. G Gonzales et al described a case of osteoid osteoma with multicentric nidus in 1996 (4).

Peripheral sclerosis :

The degree and extent of sclerosis seems to vary with location of nidus and age of patient. An intramedullary nidus in shaft of a bone may produce only a narrow ring of sclerosis and little if any changes in contour of bone. As is more often the case a diaphyseal osteoid osteoma incites an abundant sclerotic reaction about most of the circumference of nidus and will extend for several millimeters beyond it. The reactive bone is often symmetrical in respect to both the long axis of the shaft and location of the nidus so that the nidus may be located towards the edge of the sclerosis and not within the center. When the nidus is in the uncommon subperiosteal location it produces a localized periosteal bulge in contour of bone. In children under the age of five the reactive sclerosis is quite marked irrespective of location of nidus. Extensive and dense reactive new bone formation can obscure the nidus requiring over penetrated or tomography to demonstrate it (1).

Occasional case of osteoid osteoma may present with atypical manifestations. These are subperiosteal nidus - the nidus extending in soft tissues raising the periosteum, juxta articular location, accelerated growth, spontaneous regression, occurrence without characteristic pain or appearance as double lesion - widely separated lesions in same bone.

References

1. Daniel Wilner Osteoid osteoma in radiology of bone tumors and allied disorders First edition WB Saunders and Company Toronto 1982 Volume 1, first edition: 144-216
2. Adam Greenspan, Alberto Elguezael, David BRYK Multifocal osteoid osteomas a case report and review of literature Am. J. of Roentgenology 1974;121:103-106.
3. G. Gonzalez, JC Abril, IG Medirio, Tepeldegui osteoid osteoma with multicentric nidus international Orthopedics 1996; volume 20 issue 1:61-63.
4. Kenan S, Abdelwahab I, Klein MJ, Hermann G, Lewis MM Elliptical multicentric periosteal osteoid osteoma Skeletal Radiol 1994;Oct 23 (7): 565-8.