

A Case Of Tolosa -Hunt Syndrome - Mr Imaging Appearance

BP SATHYANATHAN, R RAJASUNDARAM, ST SANKARAVADIVELU, K NADHAMUNI

Ind J Radiol Imag 2006 16:1:97-98

Key words : - Tolosa hunt, ophthalmoplegia, cavernous sinus, cranial nerves III, IV, and VI

INTRODUCTION:

Tolosa hunt syndrome is recurrent painful ophthalmoplegia caused by non specific inflammation of cavernous sinus or superior orbital fissure, which is responsive to steroid therapy. The cause of the constant pain, which characterizes the onset of the disorder, is due to infiltration of lymphocytes and plasma cells along with thickening of dura matter within the cavernous sinus.

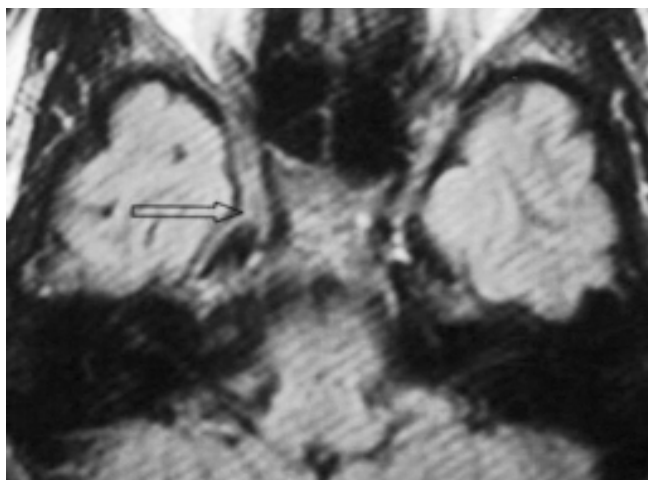


Fig 1 Axial T2 WI FLAIR Expansion of the right cavernous sinus

The disorder is part of continuum with idiopathic orbital pseudotumour with which it shares histopathologic features. Condition may be sight threatening if untreated inflammation extends beyond cavernous sinus to affect optic nerve.

Our case report is regarding a female presenting with unilateral orbital pain and ptosis. The clinical presentation can be a pointer to several conditions of the cavernous sinus and a correct diagnosis is a must to institute appropriate early management. This case is to emphasize the role of MRI in the diagnosis of this condition.

CASE REPORT

Twenty nine years old female presented with complaints

From the Barnard Institute of Radiology- Madras Medical college - Chennai-600003

Request for Reprints: Dr. BP Sathyanathan, Barnard Institute of Radiology- Madras Medical college - Chennai-600003

Received 20 November 2005; Accepted 10 February 2006

of headache for 15 days and double vision for 10 days. Headache was limited to right frontotemporal region. Patient had similar episodes of acute headache over the past one year.

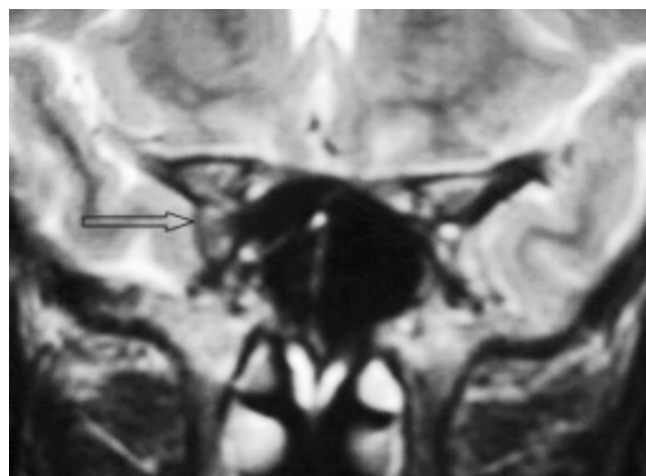


Fig 2 Coronal T2 WI Expansion of the right cavernous sinus

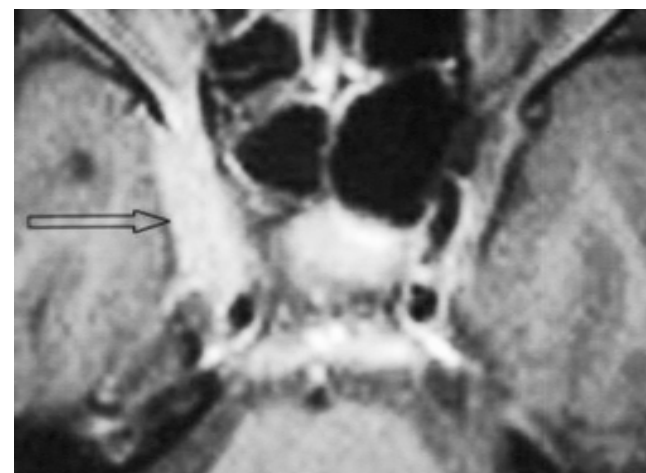

Fig 3 Axial Post contrast T1 WI Homogenous enhancement of right cavernous sinus

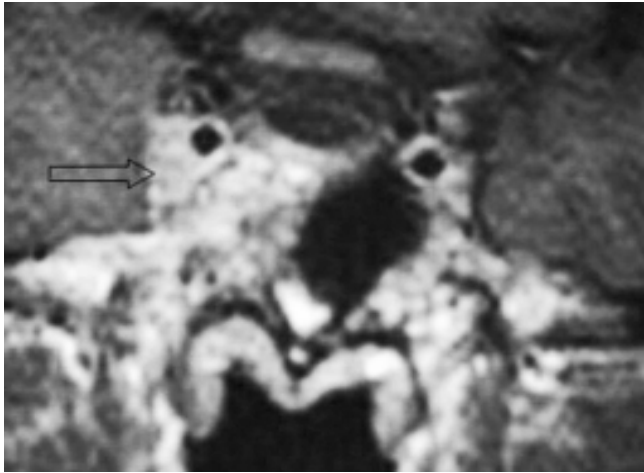


Fig 4 Coronal Post contrast T1 WI Homogenous enhancement of right cavernous sinus

HR & BP was within normal limits. She had incomplete ptosis of the right eye.

Ocular movements on the left side were normal. On the right side, abduction and adduction of the eye was restricted. Elevation and depression were slightly restricted.

No sensory loss over face was detected. Motor system was normal.

Patient underwent extensive laboratory workup, which was nonspecific.

Patient was referred for an MRI examination. Contrast enhanced MRI was performed in a SIEMENS 1.5 T. (Magnetom symphony machine). 0.1 mmol/kg Gadolinium was administered.

Pre and post contrast Coronal and Axial MP-RAGE sequences of the cavernous sinus region was done. Additionally FS CE T1W sequences were also done.

The study revealed engorgement and fullness of the right cavernous sinus with a mass which showed intense enhancement on comparison with the left side. No luminal narrowing of the internal carotid artery was demonstrated. 3D TOF MRA and 2D TOF MRV revealed no additional abnormalities. The rest of the study was unremarkable. [The above imaging findings were consistent with Tolosa hunt syndrome within the context of clinical history].

Patient was treated with steroids (T.Prednisolone 50 mg od). There was dramatic relief of symptoms within the next 48 hours. Follow-up at 3 weeks showed resolution of ptosis. Further periodic follow up was done and patient is doing well.

DISCUSSION

First described by Tolosa in 1954 in a patient with unilateral recurrent painful ophthalmoplegia with involvement of cranial nerves III, IV, and VI. Carotid angiogram showed narrowing of carotid siphon. HUNT described similar

features in 6 patients in 1961. The entity was termed Tolosa Hunt syndrome by Smith and Taxdol (1966).

THS is essentially a clinical diagnosis of exclusion. Exclusion of other conditions by neuroimaging is important. Pain that is relieved within 48 hrs of steroid therapy is characteristic.

Disease manifests as recurrent attacks of steady, dull retro orbital pain, palsies of third, fourth or 6th cranial nerves and first or second divisions of V cranial nerve and venous engorgement. Pathologically there is infiltration of lymphocytes and plasma cells along with thickening of duramater.

MRI of brain and orbit.

On MRI, abnormality was hypointense relative to fat and isointense with muscle on short TR/TE images and isointense with fat on long TR/TE scans.

CE MRI showed expansion of cavernous sinus by an enhancing soft tissue mass, engulfing and narrowing intracavernous portion of right internal carotid artery in few cases. Follow up MRI usually shows complete resolution of abnormality.

Differential diagnosis: MRI is important to rule out other pathological processes presenting with similar clinical features like Meningioma, Sarcoidosis, Pituitary tumours, tuberculous meningitis, Lymphoma.

Two other conditions presenting with identical clinical features are Ophthalmoplegic migraine-oculomotor palsy with headache. Enhancement of cisternal segment of III nerve with no involvement of cavernous sinus seen with CE MRI .

Miller - Fisher syndrome -painless ophthalmoplegia, ataxia MR imaging showed contrast enhancement of oculomotor nerve bilaterally.

CONCLUSION:

Tolosa Hunt syndrome is essentially a diagnosis of exclusion. The role of radiologist is to exclude other conditions causing similar clinical features. Resolution of findings on follow-up imaging and response to steroids is characteristic.

CE MRI plays a vital role in the early diagnosis of this sight threatening disorder.

References :

1. Head and neck imaging - 4th edition Som & Cortin 587-588
2. Yousem DM, Atlas SW : MR imaging of Tolosa -Hunt syndrome ,AJR 1990 Jan : 154(1) : 167-170
3. Goto Y, Hosokawa S ,Abnormalities in three patients with Tolosa-Hunt syndrome,MRI and CT findings J : Neurol Neurosurg Psychiatry,1990 March : 53(3) : 231-234
4. Cohn , Carassor ,painful ophthalmoplegia : the Tolosa Hunt syndrome ,Eur Neurol 1979 ; 18(6) : 373-381