

# Sonographic localization of nonpalpable testis: Tracking the cord technique

S Boopathy Vijayaraghavan

Sonoscan, Ultrasonic Scan Centre, Coimbatore, Tamil Nadu, India

**Correspondence:** Dr. S. Boopathy Vijayaraghavan, 15 B. Venkatachalam Road, R. S. Puram, Coimbatore – 641 002, Tamil Nadu, India.  
E-mail: sonoscan@vsnl.com

## Abstract

**Objective:** To evaluate the value of USG as a diagnostic tool to locate nonpalpable testis (NPT), using a new technique of tracking the spermatic cord. **Materials and Methods:** This technique was used in 197 instances of NPT over a period of 7 years. The presence or absence of the cord in the inguinal canal was recorded. The visualized spermatic cord was tracked down to the testis in extra-abdominal location. If spermatic cord was not visualized, the USG was extended up to look for intra-abdominal testis. The location and size of the testis were recorded, and the findings were compared with those seen at surgery. **Results:** The status of NPT was predicted by sonography in 191 instances. The testis was canalicular in position in 53, abdominal in 76, ascending in 5, ectopic in 8, and moving in 5 cases. There were three instances of tumor in the NPT and one case of torsion. The testes were atrophic in 36 instances. The testis was not visualized by USG in 10 instances. In four of them, spermatic cord was seen in inguinal canal, indicating vanished testes. In one patient, there was an atrophic testis with inguinal hernia. Diagnostic laparoscopy was necessary in only five cases and showed abdominal testes in two cases and the cord entering the internal ring in three cases. There were one false-positive and four false-negative results with this technique. **Conclusion:** USG, with the tracking the cord technique, is a sensitive diagnostic tool in NPT. It is useful for selecting the ideal therapeutic surgical approach and helps avoid diagnostic laparoscopy in most of the patients.

**Key words:** Nonpalpable testes; sonography; spermatic cord

## Introduction

Cryptorchidism or undescended testis refers to the condition in which the testis is not located at its normal position at the base of the scrotum, being found instead anywhere along the normal course of testicular descent, from the level of the inferior pole of the kidney to the upper scrotum.<sup>[1]</sup> Approximately 1–2.7% of boys have undescended testes. In 80% of patients with this condition, the testis is palpable in the inguinal canal and there is no need for an imaging investigation. In 20% of patients with cryptorchidism, the testis is nonpalpable.<sup>[2,3]</sup> In these cases, the first step in the

management is to identify whether a viable testis is present. If the testis is found to be viable, either an orchidopexy or, if necessary, an orchidectomy will have to be performed. The use of imaging to locate a nonpalpable testis (NPT) has been controversial. USG is appealing because it is noninvasive, does not involve radiation exposure, is economical, is easily available, and does not require sedation. However, reports so far have not demonstrated significant efficacy of sonography in localizing NPT. The aim of this prospective study was to evaluate the results of sonography – using a new technique of tracking the spermatic cord – in a series of patients who were referred with a diagnosis of NPT.

## Materials and Methods

This prospective study, conducted over a period of 7 years (up to June 2007), included patients of cryptorchidism in whom the testis was nonpalpable. A broadband linear probe of 5–12 MHz was used (Philips HDI 3500 and 5000). In unilateral cases, sonography was performed over the normal testis and then over the scrotum of the NPT. If the testis was not seen in the scrotum, the “tracking the cord”

### Access this article online

#### Quick Response Code:



**Website:**  
www.ijri.org

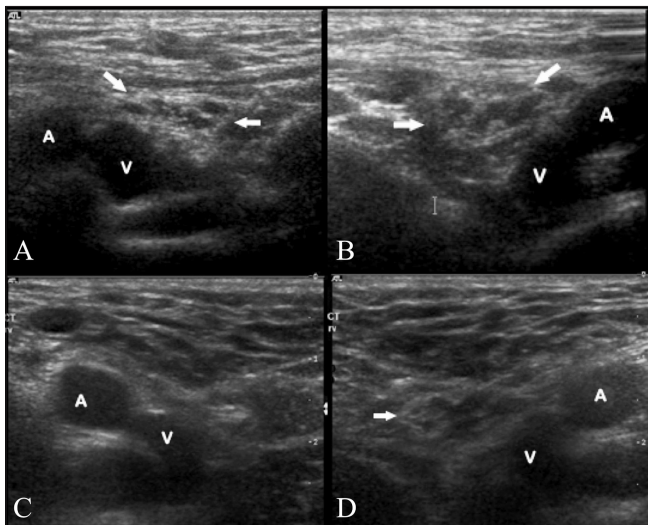
**DOI:**  
10.4103/0971-3026.82298

technique was performed as follows. A transverse scan of the inguinal region was obtained just below the inguinal crease with the common femoral artery and vein seen in their transverse axis. The normal spermatic cord was then identified in the inguinal canal, anteromedial to the common femoral vessels. It was seen as an oval echogenic structure with a few round echo-poor areas within it, representing the vas deferens and the vessels [Figure 1A-D]. For comparison, particularly in children in whom the cord is small, a similar scan of the normal side was performed. If the cord was seen, it was tracked down along the inguinal canal and beyond to look for a testis. The spermatic cord led to a normal or atrophic testis in the inguinal canal, scrotum, or at an ectopic site. When there was looping of the cord in the inguinal canal, tracking the returning loop led to an intra-abdominal testis in cases of an ascended testis. If the testis was seen along the course, this fact was recorded. When the cord was not seen in the inguinal canal, an extra-abdominal testis was ruled out [Figure 1C and D]. In these cases, the transverse scan of the common femoral vessels was extended upward along the external iliac and common iliac vessels up to the bifurcation of aorta to look for an abdominal testis. When this failed to locate the testis, a scan of the iliac fossa and pelvis was obtained. If necessary, a lower-frequency probe was used. The intra-abdominal testis was differentiated from a bowel loop by the presence of peristalsis in the bowel and the mobility of the testis. If a testis was located, its size was measured and the echo pattern assessed. The presence of an inguinal hernia was assessed using the Valsalva maneuver. We excluded those patients in whom sonography revealed a normal testis in the scrotum or those in whom the testis, located in the

inguinal canal, could be easily milked into scrotum. There were 17 such patients. One newborn patient of 13 days with bilateral NPT showed both testes located intra-abdominally, but a follow-up scan at 6 months revealed both testes in the upper scrotum; this patient was also excluded. The remaining 202 patients were taken as true NPT cases. Of these, 13 patients were not willing for further management and 10 were lost to follow-up and, hence, they were also excluded from the study. One patient in whom sonography could not locate the testis showed an absent testis on MRI scan also and nothing further was done. All the remaining 178 patients were subjected to appropriate surgery, either laparoscopy or inguinoscrotal exploration, and the results were recorded. Either orchidopexy or orchidectomy was performed, depending on the findings.

### Results

This study included 178 patients, with a total of 197 NPT (bilateral in 19), who underwent surgery for the same. The age of the patients ranged from 3 months to 40 years [Table 1]. Among 159 patients with unilateral NPT, the right side was involved in 61 patients and the left in 98 [Table 2]. The testis (normal or atrophic) was localized by sonography in 187 patients (94.9%), while the investigation failed to localize the testis in 10 (5.1%). The testis was of normal size in 147 patients, and the site of the localized testis was inguinal canal (canalicular) in 53 [Figure 2], intra-abdominal in 76 [Figure 3], ectopic in 8, ascended testis in 5,



**Figure 1 (A-D):** Transverse scans of the right (A) and left (B) inguinal regions of a normal patient show the spermatic cord in oblique section (arrows) anteromedial to the common femoral artery (A) and vein (V). Similar sections in a patient with a right NPT reveal nonvisualization of the spermatic cord on the right side (C) and a normal cord (arrow) on the left side (D)

**Table 1: Age distribution of patients with nonpalpable testis**

Up to 5 years	115
6–10 years	34
11–20 years	22
21–30 years	15
31–40 years	11
<b>Total</b>	<b>197</b>

**Table 2: Sonographic features of nonpalpable testes**

	Unilateral		Bilateral	Total
	Right	Left		
Canalicular – Normal	25	16	12	53
Canalicular – Tumor and torsion		2		2
Abdominal – Normal	23	31	22	76
Abdominal – Tumor			2	2
Ectopic	2	6	–	8
Ascended	1	4	–	5
Moving testis	2	3	–	5
Vanished testes	1	3		4
Atrophic	6	28	2	36
Not located	1	5	–	6
<b>Total</b>	<b>61</b>	<b>98</b>	<b>38</b>	<b>197</b>

and moving testis in 5. The patients with canalicular or ectopic testis underwent inguinoscrotal exploration and the location was confirmed in all of them. Laparoscopy was performed in all the patients in whom sonography revealed an intra-abdominal testis, and the location was confirmed in all of them. The various locations of intra-abdominal testis are shown in Table 3.

There were eight ectopically located testes [Table 4] and all were confirmed by surgery. The perineal testis was seen in the subcutaneous plane, posterolateral to the base of the scrotum [Figure 4]. Of the two cases of transverse testicular ectopia, one was intra-abdominal, proximal to the opposite internal ring. In the other case, both testes were seen in the opposite scrotal sac [Figure 5]. In five patients, a looped spermatic cord was seen in the inguinal canal and tracking the returning loop led to an abdominal testis [Figure 6]. These features were suggestive of an ascended testis. In all the five patients, laparoscopy revealed an abdominal testis, with a loop of spermatic cord in the inguinal canal, confirming an ascended testis. In five instances, the testis was seen moving between the inguinal canal and an intra-abdominal location during scanning [Figure 7]. At laparoscopy they were abdominal in location, with an open internal ring. In one patient aged 30 years with bilateral NPT, there was seminoma of both testes, which were located at the pelvic brim. In another patient of 27 years, there was a mass

of the testis located in the inguinal canal; this turned out to be a germ cell tumor. There was torsion of a canalicular testis in an infant of 3 months; this case has been reported earlier by the author.<sup>[4]</sup> The testis was atrophic in 36 patients. Atrophic testis was seen in the scrotum in 25 patients, in the inguinal canal in 10, and in an intra-abdominal location in 1 patient [Table 5]. The appearance of the atrophic testis varied. It was echo poor in 15 cases, echogenic in 7, showed central calcification in 8, and eggshell calcification in 6 [Figure 8]. Inguinoscrotal exploration or laparoscopy and biopsy confirmed the diagnosis of atrophic testes and the location in 35 cases. In one instance, laparoscopy revealed a normal abdominal testis proximal to the internal ring, whereas USG had revealed an atrophic testis in the scrotum. This case was the only false-positive case in the series. This case was also false negative as the normal-sized intra-abdominal testis was not located by USG.

In the 10 patients in whom the testis could not be located, the spermatic cord was seen in the inguinal canal in four cases [Table 6]. In these four patients, an inguinal exploration revealed a thin vas deferens ending blindly in the scrotum, confirming a diagnosis of vanished testis. Among the remaining six in whom the spermatic cord was not visualized, one patient had an ipsilateral inguinal hernia, which on exploration revealed an atrophic testis. The remaining five underwent diagnostic laparoscopy. There

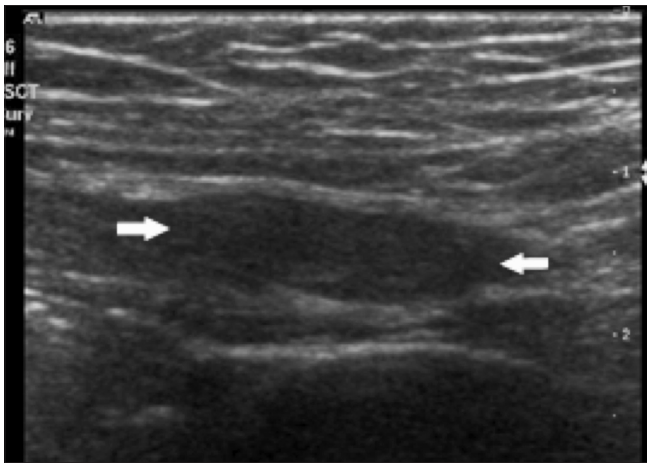


Figure 2: Oblique section shows the testis (arrows) in the inguinal canal

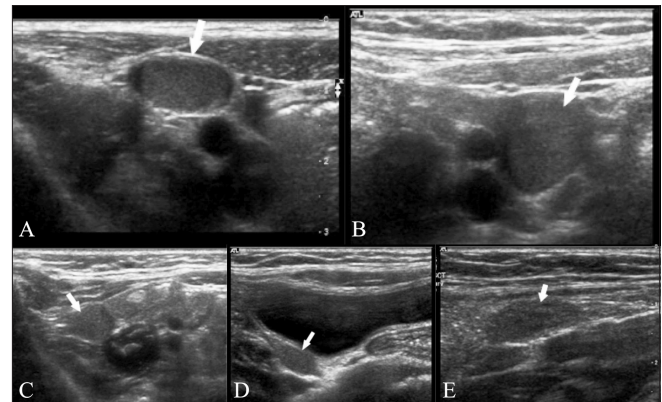


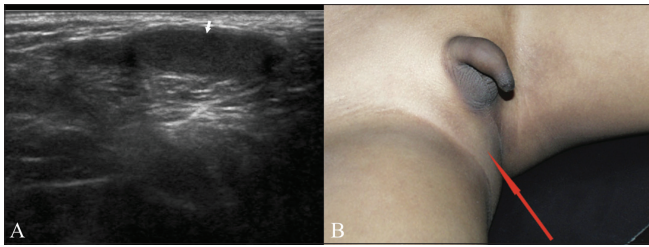
Figure 3 (A-E): Intra-abdominal testes. Sections of the lower abdomen show the location of intra-abdominal testes (arrows): Anterior (A), medial (B), and lateral (C) to the external iliac vessels; along the right side wall of the pelvis (D); and anterior to the bifurcation of the common iliac artery (E)

Table 3: Location of intra-abdominal testis

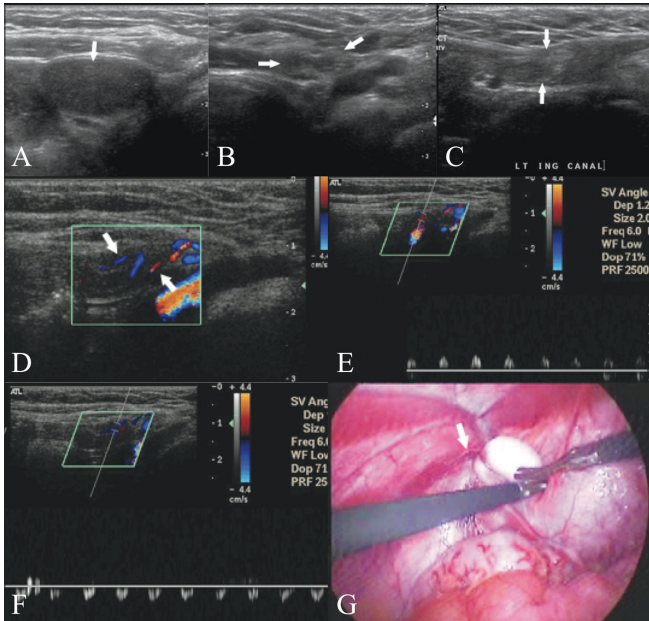
Anterior to external iliac vessels	24
Medial to external iliac vessels	37
Lateral to external iliac vessels	11
Related to bifurcation of common iliac artery	4
Side wall of pelvis	2
	78

Table 4: Ectopic testis

Perineal	2
Transverse testicular ectopia – abdominal	1
Transverse testicular ectopia – scrotum	1
Anterior abdominal wall	2
Superficial inguinal pouch	2



**Figure 4 (A,B):** Perineal testis. Longitudinal image (A) shows the testis (arrow) in the subcutaneous plane in the perineum, posterolateral to the scrotum. Photograph (B) shows the site of the ectopic testis (arrow)



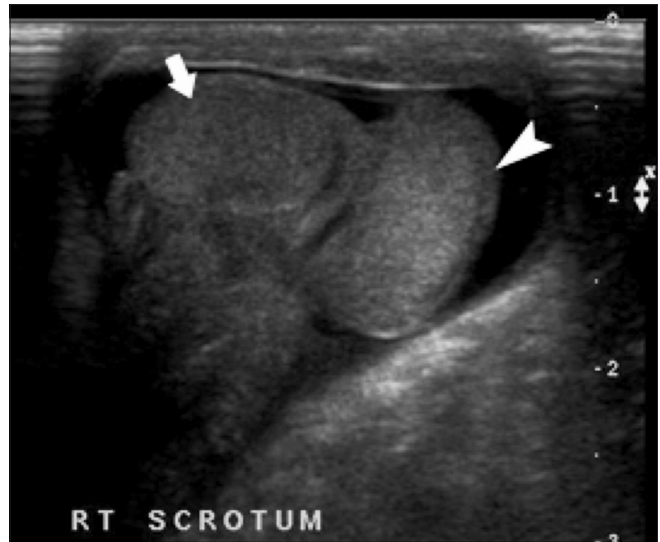
**Figure 6 (A-G):** Ascended testis. Image of the lower abdomen (A) shows the intra-abdominal testis (arrows). Transverse (B) and (C) longitudinal sections of the inguinal region show the two loops (arrows) of the spermatic cord in the inguinal canal. Color Doppler (D) image shows the testicular artery (arrows) in the two loops of the cord, confirming the looping of the cord. Spectral Doppler images (E,F) of the testicular artery in the two loops show flow in opposite directions. Laparoscopic picture (G) shows the intra-abdominal testis with the spermatic cord (arrow) emerging out of the internal ring

**Table 5: Atrophic testes**

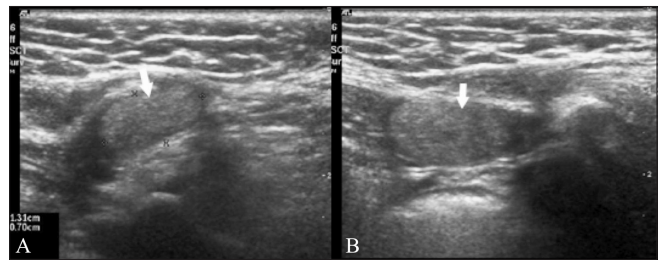
	Echo poor	Echogenic	Central calcification	Eggshell calcification	Total
Scrotum	8	4	7	6	25
Canalicular	7	2	1	0	10
Abdominal	0	1	0	0	1
	15	7	8	6	36

**Table 6: Patients in whom the testis was not located by USG**

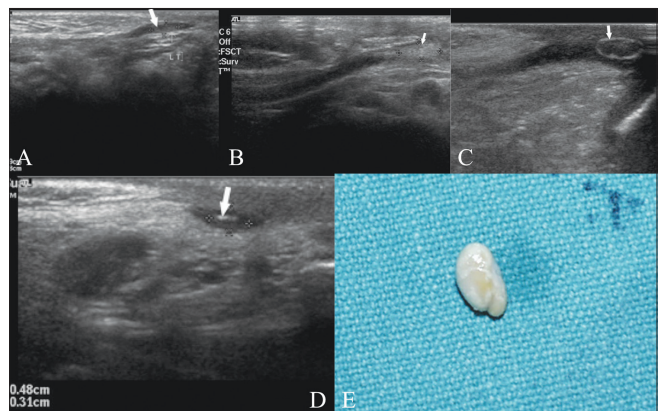
Spermatic cord seen in inguinal canal (vanished testis)	4
Spermatic cord not seen	6
Inguinal hernia with atrophic testis	1
Abdominal testis	2
Thin cord entering internal ring/no testis (vanished testis)	3



**Figure 5:** Transverse testicular ectopia. Both testes (arrow, arrowhead) are seen in the right side of the scrotum



**Figure 7:** Moving testis: Images shows the testis (arrows) in the inguinal canal (A) and in the abdomen (B)



**Figure 8:** Images show varying appearance of atrophic testis (arrows). Echopoor (A), echogenic (B), eggshell calcification (C), and central calcification (D). Photograph (E) of an atrophic testis removed at exploration

was an intra-abdominal testis in two patients. In three cases, there was a thin vas deferens entering the internal ring, with an absent testis distally, indicating vanished testis. Thus, laparoscopy was necessary for diagnosis in only 5 of the 197 NPT (2.5%) cases. There was an ipsilateral inguinal hernia in 21 patients.

The status of NPT was a normal-sized testis (147), abnormally enlarged testis like tumor or torsion (4) atrophic testis (35) or vanished testis (7).

When compared with surgery, USG had a 97.9% sensitivity in predicting the status of NPT; USG failed to predict the status of NPT in seven instances [Tables 7 and 8]. Similarly, compared to surgery, the sensitivity of USG was 96.7% in localizing an intra-abdominal testis [Table 9]. It located 90 out of 93 abdominal testes (normal intra-abdominal testis 76, tumor of abdominal testis 2, ascended testis 5, moving testis 5, atrophic intra-abdominal testis 1, and transverse testicular ectopia 1). The sensitivity of USG was 99% in localizing testes in the extra-abdominal regions [Table 10]. Surgery confirmed sonographically located extra-abdominal testis in 100 out 101 cases (canalicular 53, atrophic 34, tumor and torsion 2, vanished testis 4 and ectopic 7); thus, there was only one false-positive case with USG.

## Discussion

The testis develops intra-abdominally and moves toward the scrotum during fetal development. Undescended testis, also known as cryptorchidism, refers to the condition in which the testis fails to reach the scrotum. The descent may be arrested at any level along the path from the retroperitoneum to the scrotum. The condition is associated with some complications, such as testicular malignancy, subfertility, torsion, and inguinal hernia, with a high risk of occurrence of these complications if the condition is not corrected early.<sup>[5]</sup> The rationale of management of this condition is to place the testis in the scrotum to maximize its potential for spermatogenesis and to screen for occurrence of malignancy or to remove a nonviable testis. One surgical procedure is to perform diagnostic laparoscopy to determine the location of the testis and then proceed with orchidopexy when a viable testis is found. Another common approach is to perform an inguinoscrotal exploration and,

**Table 7: Results of USG and surgery in NPT**

	USG	Surgery		
		Inguinoscrotal exploration	Laparoscopy	
Extra-abdominal testis by USG				
a. Canalicular normal size	53	53		
b. Ectopic	7	7		
c. Tumor	1	1		
d. Torsion	1	1		
e. Atrophic	35	34	1 (intra-abdominal testis)	False + and false –
Intra-abdominal testis by USG				
a. Normal size	76		76	
b. Atrophic	1		1	
c. Ascending testis	5		5	
d. Moving testis	5		5	
e. Tumor	2		2	
f. Transverse testicular ectopia	1		1	
Nonvisualized testis by USG				
a. Spermatic cord in inguinal canal (vanished testis)	4	4		
b. Inguinal hernia with atrophic testis	1	1		False –
c. Spermatic cord not seen in inguinal canal	5			
i. Intra-abdominal testis			2	False –
ii. Spermatic cord entering internal ring (vanished testis)			3	
<b>Total</b>	<b>197</b>			

**Table 8: Status of nonpalpable testis**

	Surgery	
	+	-
USG	190	1
	4	3

Sensitivity:  $190/(190 + 4) = 97.9\%$

**Table 9: Intra-abdominal testis**

	Surgery	
	+	-
USG	90	0
	3	0

Sensitivity:  $90/(90 + 3) = 96.7\%$

**Table 10: Extra-abdominal testis**

		Surgery	
		+	-
USG	+	100	1
	-	1	5

Sensitivity:  $100/(100 + 1) = 99\%$

if the testis is not located, to extend the exploration into the peritoneal cavity.<sup>[6,7]</sup>

On clinical examination, 80% of undescended testes are palpable and do not need any imaging investigation. About 20% of undescended testes are nonpalpable.<sup>[2,3]</sup> Besides nonpalpable canalicular testes and abdominal testes, the term NPT also includes those cases where there is an ectopic, atrophic, and absent testis. Preoperative localization of the testis by an imaging study is beneficial as the findings will modify the surgical procedure and thus help avoid some of the costs and risks associated with surgery. If the testis is not located or if an abdominal testis is located by imaging, the patient can undergo laparoscopy. Patients who have canalicular or ectopic testis can undergo inguinal exploration and laparoscopy can be avoided in them. Surgery can even be avoided if it could be proven that the cause is vanished testis. So, the aims of an imaging method are (1) to localize the testis, including ectopic locations; (2) to find out if the testis is viable or atrophic; and (3) to know if it is a case of vanished testis.

USG is a non invasive, simple, easily available, and economical imaging method. The utility of the imaging methods for preoperative localization of NPT remains controversial and the reports so far have been discouraging because of the high false-positive and false-negative rates.<sup>[8-22]</sup> The status of NPT may include a testis of normal size, abnormally enlarged testis like tumor or torsion, atrophic testis or vanished testis. In the past, the techniques used have aimed at visualizing the testis, and there were problems when attempting to visualize atrophic, absent, and ectopic testes. This resulted in the low sensitivity and specificity of USG.<sup>[20-22]</sup> Hence, the surgeons opted to perform either diagnostic laparoscopy or inguinoscrotal exploration as the first procedure. Depending on the outcome of this procedure, the second surgery was performed. In most instances, an imaging investigation was not performed.

The current study presents the new technique of tracking the spermatic cord. The spermatic cord, being an accompanying structure of the testis, helps to locate the testis. The spermatic cord is formed at the internal inguinal ring; it passes down the inguinal canal to exit the canal at the external inguinal ring and extends into the scrotum, lying posterior to the testis, up to the tail of the epididymis. It contains the vas deferens, veins, arteries, lymphatics, and

nerve, and is covered by the cremasteric fascia. The high resolution provided by the presently available USG scanners helps to visualize the spermatic cord in the inguinal canal. On a transverse scan of the inguinal region, the cord is seen as an oval, echogenic structure with a few rounded echopoor areas that represent the vas deferens and the vessels. It is seen in the inguinal canal, anteromedial to the common femoral vessels. Visualization and tracking of the spermatic cord helps predict the status of the NPT in various ways as follows. (1) When visualized, the spermatic cord can be tracked down and will lead to a testis of normal size located in the inguinal canal and scrotum. Using this technique, the testis [normal, abnormal (tumor or torsion), or atrophic testis], was located correctly in 187 patients in this study. (2) The visualized cord can be tracked to an ectopic testis, which otherwise would have evaded detection. Ectopic testis is the condition where the testis is located outside the path of its descent. It can be located in the following locations: (a) superficial inguinal pouch, (b) anterior abdominal wall, (c) prepenile region, (d) perineal region, and (e) femoral region. In all these situations, the spermatic cord is seen in the inguinal canal and it acts as a guide to the ectopic testis. The tracking the cord technique was useful in six cases in our series for locating the ectopic testis (in the perineum, anterior abdominal wall, and superficial inguinal pouch).<sup>[23,24]</sup> Transverse testicular ectopia is the condition where both the gonads migrate toward the same hemiscrotum. The testis may lie in the opposite hemiscrotum, in the opposite inguinal canal, or at the opposite deep inguinal ring. Transverse testicular ectopia was seen in two instances in this series. (3) Tracking the visualized cord can lead to an atrophic testis in the canal or scrotum, which can be easily missed otherwise due to its very small size. The smallest atrophic testis in this series was 4.8 mm × 3 mm. Such a small testis can be missed on routine USG, but with the technique of tracking the spermatic cord, such a small testis can be easily identified and confirmed. This technique helped in visualizing the atrophic testis in 36 patients in this series; the testes in these cases revealed varied appearance, being echo poor, echogenic, or showing central/eggshell calcification. (4) The cord can be looped in the inguinal canal in cases of ascended testis and the returning loop can be tracked up to the intra-abdominal testis. Ascended testis is defined as a condition where the testis is initially thought to be normally descended but is later found to be outside of the scrotum.<sup>[25]</sup> Ascended testis was seen in five instances in this series. (5) When the testis is not visualized although the spermatic cord is seen in inguinal canal, it would indicate a vanished testis. Vanished testis occurs when the testis has descended into the scrotum but has atrophied totally due to torsion or an ischemic event during prenatal or early postnatal life. In this situation, the spermatic cord will be seen in the inguinal canal, but when tracked down it does not lead to a testis. USG correctly predicted a vanished testis in four patients in this series. (6) If the spermatic cord is not visualized in the inguinal canal, an extra-abdominal location

of the testis can be ruled out and the search can be extended to look for an abdominal, retroperitoneal, or pelvic location of the testis. Thus, tracking the spermatic cord technique addressed the problem of locating ectopic, atrophic and vanished testes, thereby improving the sensitivity to a great extent. This technique has not been used by anyone earlier to the best of our knowledge.

USG failed to predict the status of the NPT in 7 out of 197 patients. In one patient, the nonvisualization was due to an inguinal hernia, which hampered the visualization of an atrophic testis and the cord. The rest of the patients had to undergo diagnostic laparoscopy to locate the testis or document its absence. Hence, diagnostic laparoscopy was necessary in only 5 of the 197 cases of NPT (2.5%). Laparoscopy revealed a normal abdominal testis in two of these patients. These form two of the four false-negative cases in our series. In the remaining three patients, a thin vas deferens was seen entering the internal ring, indicating the diagnosis of vanished testis. In these three patients, USG failed to visualize the thin spermatic cord in the inguinal canal. Thus, the tracking the cord technique helps especially in those situations where the testis is atrophic, vanished or ectopic, the spermatic cord acting as a lead point to locate the testis irrespective of its size and location, thereby improving the sensitivity of USG.

This technique of tracking the cord also helps in selection

of the appropriate therapeutic surgery for patients. Patients with an abdominal testis underwent laparoscopy. Those with canalicular testis, ectopic testis, or atrophic testis in the scrotum/canal underwent inguinoscrotal exploration. There was only one false-positive instance in whom USG located an atrophic testis in the scrotum but surgery revealed an abdominal testis. This was the only instance of unnecessary surgery (inguinal exploration) out of 197 instances (0.5%). Thus, the tracking the cord technique was useful for selecting the ideal therapeutic surgical approach in 193 (98%) patients, with only one instance of unnecessary surgery. Based on this study, an algorithm for managing NPT is suggested in Figure 9.

In conclusion, high-resolution USG using the tracking the spermatic cord technique is a cost-effective and sensitive preoperative imaging method in NPT. The technique provides a protocol of scanning approach in a patient with NPT. It is useful for selecting the ideal therapeutic surgical approach and avoids the need for diagnostic laparoscopy in most of the patients.

### Acknowledgement

I wish to thank my wife Mrs. Radhika Vijayaraghavan and children for their support. I wish to thank all the urologists and pediatric surgeons for their excellent co-operation during the study. My thanks are also due to the

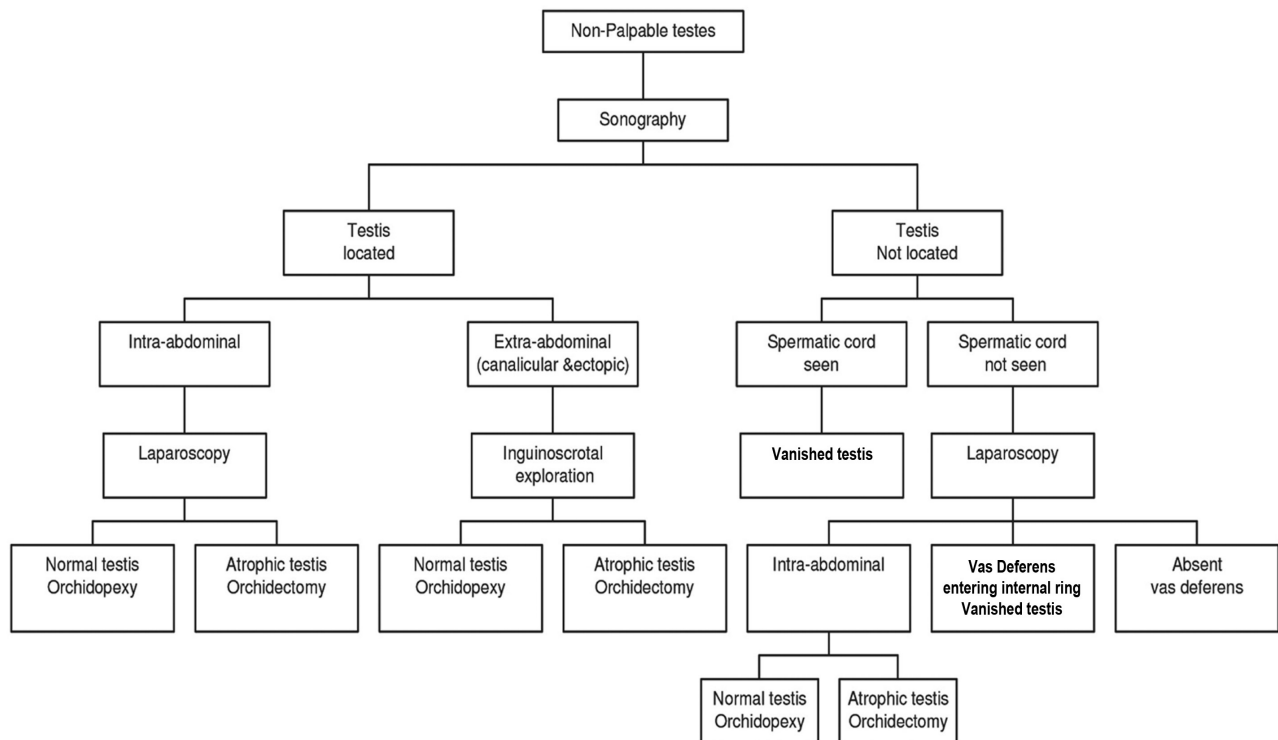


Figure 9: Algorithm for managing a case of nonpalpable testis

staff of SONOSCAN- In particular Mrs. Padma Ramesh for secretarial help and Mr.Sreedharan for EDP help.

## References

1. Salder TW. Longman's Medical Embryology. 9<sup>th</sup> ed. St. Louis, MO: Mosby; 2004.
2. Elder JS. The undescended testis. Hormonal and surgical management. Surg Clin North Am 1988;68:983-1005.
3. MacKinnon AE. The undescended testis. Indian J Pediatr 2005;72:429-32.
4. Vijayaraghavan SB. Sonographic differential diagnosis of acute scrotum: Real-time whirlpool sign, a key sign of torsion. J Ultrasound Med 2006;25:563-74.
5. Martin DC. Germinal cell tumors of the testis after orchiopexy. J Urol 1979;121:422-4.
6. Elder JS. Laparoscopy for impalpable testes: Significance of the patent processus vaginalis. J Urol 1994;152:776-8.
7. Pekkaflali MZ, Sahin C, Ilbey YO, Albayrak S, Yildirim S, Basekim CC. Comparison of ultrasonographic and laparoscopic findings in adult nonpalpable testes cases. Eur Urol 2003;44:124-7.
8. Weiss RM, Carter AR, Rosenfield AT. High resolution real-time ultrasonography in the localization of the undescended testis. J Urol 1986;135:936-8.
9. Madrazo BL, Klugo RC, Parks JA, DiLoreto R. Ultrasonographic demonstration of undescended testes. Radiology 1979;133:181-3.
10. Wolverson MK, Houttuin E, Heiberg E, Sundaram M, Shields JB. Comparison of computed tomography with high-resolution real-time ultrasound in the localization of the impalpable undescended testis. Radiology 1983;146:133-6.
11. Rajfer J, Tauber A, Zinner N, Naftulin E, Worthen N. The use of computerized tomography scanning to localize the impalpable testis. J Urol 1983;129:972-4.
12. Hrebinko RL, Bellinger MF. The limited role of imaging techniques in managing children with undescended testes. J Urol 1993;150:458-60.
13. Riebel T, Gonnermann D, Willig RP. Spermatic venography in undescended testes. Pediatr Radiol 1987;17:39-44.
14. Gill B, Kogan S. Cryptorchidism. Current concepts. Pediatr Clin North Am 1997;44:1211-27.
15. Elder JS. Epididymal anomalies associated with hydrocele/hernia and cryptorchidism: Implications regarding testicular descent. J Urol 1992;148:624-6.
16. Maghnie M, Vanzulli A, Paesano P, Bragheri R, Palladini G, Preti P, *et al.* The accuracy of magnetic resonance imaging and ultrasonography compared with surgical findings in the localization of the undescended testis. Arch Pediatr Adolesc Med 1994;148:699-703.
17. De Filippo RE, Barthold JS, Gonzalez R. The application of magnetic resonance imaging for the preoperative localization of nonpalpable testis in obese children: An alternative to laparoscopy. J Urol 2000;164:154-5.
18. Dogra VS, Gottlieb RH, Oka M, Rubens DJ. Sonography of the scrotum. Radiology 2003;227:18-36.
19. Wolverson MK, Jagannadharao B, Sundaram M, Riaz MA, Nalesnik WJ, Houttuin E. CT in localization of impalpable cryptorchid testes. AJR Am J Roentgenol 1980;134:725-9.
20. Cain MP, Garra B, Gibbons MD. Scrotal-inguinal ultrasonography: A technique for identifying the nonpalpable inguinal testis without laparoscopy. J Urol 1996;156:791-4.
21. Dhaghighi MH. Assessment of diagnostic value of sonography for cryptorchidism. J Diagn Med Sonography 2006;22:42-7.
22. Nijs SM, Eijssbouts SW, Madern GC, Leyman PM, Lequin MH, Hazebroek FW. Nonpalpable testes: Is there a relationship between ultrasonographic and operative findings? Pediatr Radiol 2007;37:374-9.
23. Hutcheson JC, Snyder HM 3rd, Zuñiga ZV, Zderic SA, Schultz DJ, Canning DA, *et al.* Ectopic and undescended testes: 2 variants of a single congenital anomaly? J Urol 2000;163:961-3.
24. Rao PL, Gupta V, Kumar V. Anterior abdominal wall--An unusual site for ectopic testis. Pediatr Surg Int 2005;21:687-8.
25. Rusnack SL, Wu HY, Huff DS, Snyder HM 3rd, Zderic SA, Carr MC, *et al.* The ascending testis and the testis undescended since birth share the same histopathology. J Urol 2002;168:2590-1.

**Cite this article as:** Vijayaraghavan SB. Sonographic localization of nonpalpable testis: Tracking the cord technique. Indian J Radiol Imaging 2011;21:134-41.

**Source of Support:** Nil, **Conflict of Interest:** None declared.

### Advertisement

#### PRE OWNED MRI FOR SALE

1. Fully loaded APERTO 0.4T Hitachi MRI system in full working and good condition.

PLEASE SEND YOUR INQUIRIES WITH NAME AND CONTACT NUMBERS AT

E-mail: mrisale2011@gmail.com