

# A pictorial essay: Radiology of lines and tubes in the intensive care unit

Sanjay N Jain

Head of Radiology Department, Prince Aly Khan Hospital, Aga Hall, Nesbit Road, Mazagaon, Mumbai – 400 010, India

**Correspondence:** Dr. Sanjay N. Jain, Flat.No. 55, 5<sup>th</sup> Floor, Mamta “B” CHSL, A. M. Marg, Prabhadevi, Mumbai–400 025, Maharashtra, India. E-mail: dr.jainn@gmail.com

## Abstract

A variety of devices are used in the intensive care unit for long durations. Each one of them is a double-edged sword: intended to save life, but life-threatening if in the wrong place. Hence, it is important to periodically check that these devices are correctly placed so as to prevent complications. The portable chest radiograph is of tremendous value in this context.

**Key words:** Chest radiograph; intensive care unit; catheters; lines; tubes

## Introduction

The chest radiograph (CXR) plays a crucial role in critically ill patients in intensive care units. It is the most common radiological investigation ordered due to its diagnostic value in cardiorespiratory disease. In addition, it is extremely useful for evaluating the position of various tubes, lines, and other devices and for detecting related complications.

The American College of Radiology (ACR) recommends a CXR immediately following placement of indwelling tubes, catheters and other devices to check the position and detect procedure related complications.<sup>[1]</sup> Bekemeyer and colleagues found that 27% of newly placed catheters or tubes were improperly positioned and that 6% resulted in a radiographically visible complication of the intervention.<sup>[2]</sup> Although many such abnormalities may not be immediately life-threatening, some require rapid correction to avoid clinical deterioration in patients with marginal cardiopulmonary reserve. All catheters have the potential risks of coiling, misplacement, knotting, and fracture. It is important to understand the function of a

device as well as to recognize the complications associated with its use. We will now discuss the commonly used tubes and lines.

## Nasogastric Tube

The nasogastric (NG) tube is inserted for either feeding the patient or for aspiration of gastric contents, and for these purposes the tip should lie within the stomach. The NG tube has multiple side holes. There are terminal lead balls to facilitate identification of the tip. Ideally, the tip of NG tube should lie with its side holes in the gastric antrum. Pushing air into the NG tube while auscultating with a stethoscope over the stomach is the usual method by which correct positioning in the stomach is confirmed.

If the side holes are positioned within the esophagus there is increased risk of aspiration [Figure 1]. For this reason, the tip of the NG tube should be positioned at least 10-cm caudal to location of the gastroesophageal junction. Other naso/oro-enteric tubes are also encountered. The tip of a nasoduodenal feeding tube should be inserted at least 10–12 cm into the small bowel.

Inadvertent insertion into the trachea and bronchus [Figure 2] can cause pneumonia, pulmonary contusion, or pulmonary laceration. Pharyngeal and esophageal perforations can occur but are rare.<sup>[3]</sup>

## Endotracheal Tube

The endotracheal (ET) tube is inserted for ventilation of

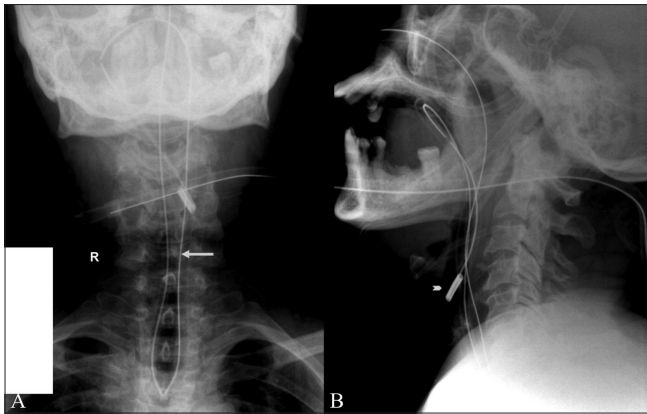
### Access this article online

#### Quick Response Code:



Website:  
www.ijri.org

DOI:  
10.4103/0971-3026.85365



**Figure 1 (A, B):** Frontal (A) and lateral (B) radiographs of the neck show a NG tube (arrow) coiled in the upper esophagus with its tip in the oropharynx (arrowhead)

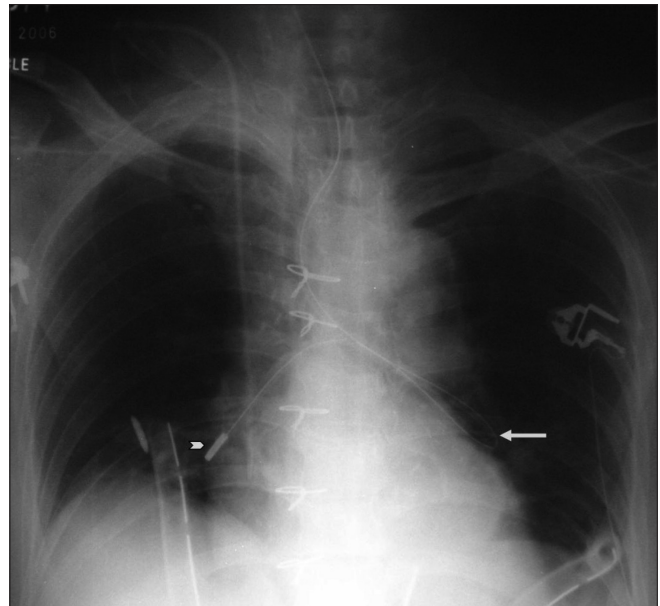
both the lungs and for prevention of aspiration. It has a terminal hole and a cuff. The satisfactory position of an ET tube in the neutral position of the neck is with the tip 5–7 cm above the carina. The location can vary approximately 2 cm in the caudal or cephalad directions with neck flexion and extension, respectively.<sup>[4]</sup> When the carina is not visible, the tip of the ET tube should be approximately at the level of the medial ends of the clavicle. It should lie midway between the larynx and carina so that injury to either structure or complications like inadvertent extubation or selective main-stem bronchus intubation are avoided. Selective intubation can cause collapse of the contralateral lung [Figure 3], hyperinflation of the ipsilateral lung, or pneumothorax. An immediate CXR after intubation is warranted because these complications are not uncommon and because the tube is quite commonly malpositioned.<sup>[5]</sup> Main stem intubation can be clinically occult in about 60% of patients and only revealed on the CXR.<sup>[6]</sup> One other thing that must also be checked for is an aspirated tooth.

Inadvertent esophageal intubation [Figure 4] is a dreadful complication, which is mostly diagnosed clinically; it can be detected radiographically by the presence of an over-distended stomach.

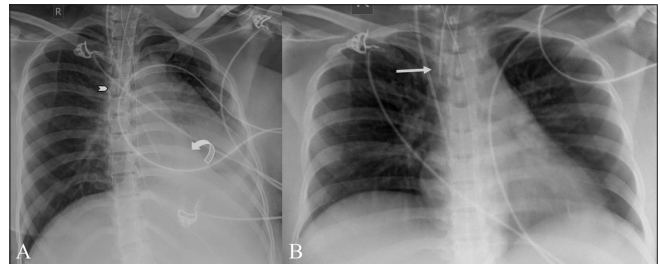
Tracheal stenosis can occur following long-term tube placement.

### Tracheostomy

The tip of the tracheostomy tube should be half way between the stoma and the carina, at the level of the D3 vertebra. Unlike the ET tube, its position is maintained with neck flexion and extension. The width of the tube (diameter) should be 2/3<sup>rd</sup> of the tracheal width, and the cuff should not distend the tracheal wall. It should lie parallel to the trachea. The possible complications are surgical emphysema, pneumomediastinum, pneumothorax



**Figure 2:** Frontal radiograph of the chest shows a NG tube forming a loop in the left bronchus (arrow) before the tip (arrowhead) reaches the right lower lobe bronchus

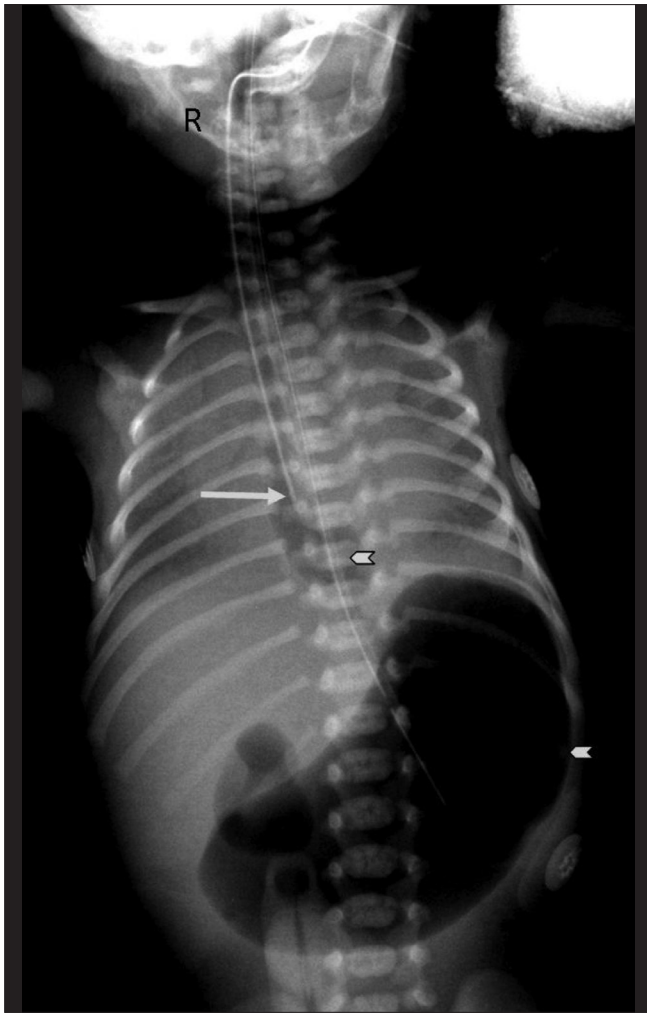


**Figure 3 (A, B):** Frontal chest radiographs show an endotracheal tube in the right main bronchus (arrowhead in A), causing hyperinflation of the ipsilateral lung and partial collapse of the left lung (curved arrow in A). After withdrawal of the tube into the trachea (arrow in B), the left lung has inflated

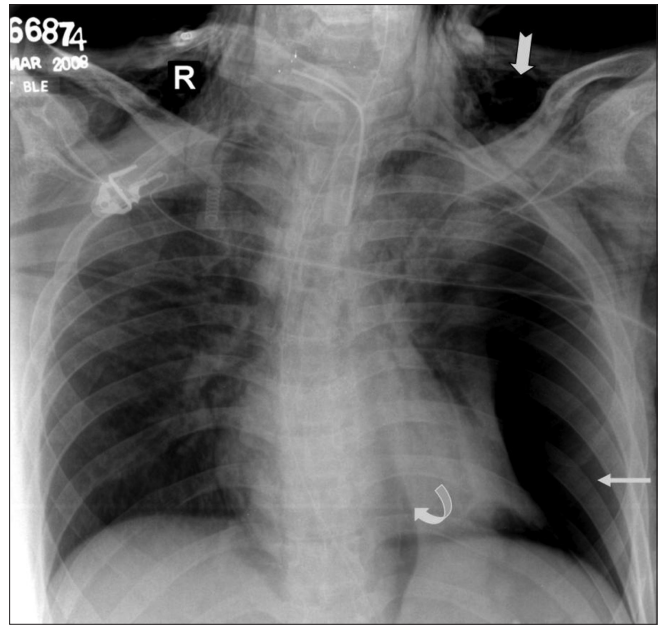
[Figure 5], hemorrhage, false tract, and tracheal stenosis. Hematoma causes widening of the superior mediastinum.

### Drainage Tube

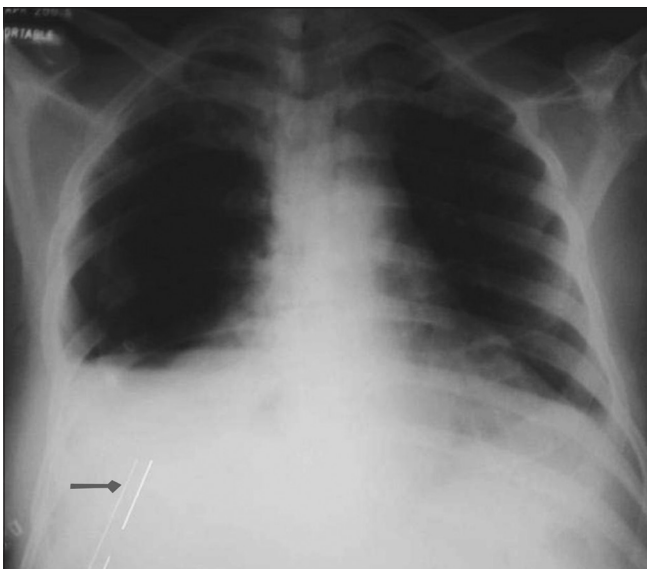
The pleural tube, more commonly known as the intercostal drainage tube (ICD), is inserted through the 4<sup>th</sup> intercostal space in the anterior or mid-axillary line. It is then directed posteroinferiorly in cases of effusion and anterosuperiorly in cases of pneumothorax. The ICD tube has a terminal hole as well as side holes; the side holes can be identified on a CXR by the interruption in the radiopaque outline of the tube. No side holes should lie outside the chest/pleura and the tube should not float above the effusion like a 'lotus in the pond.' Chest tube malposition occurs in about 10% of placements, rendering the tube malfunctioning or nonfunctioning [Figure 6].<sup>[1]</sup> Occasionally the tube tip may lie in an interlobar fissure or even within the lung



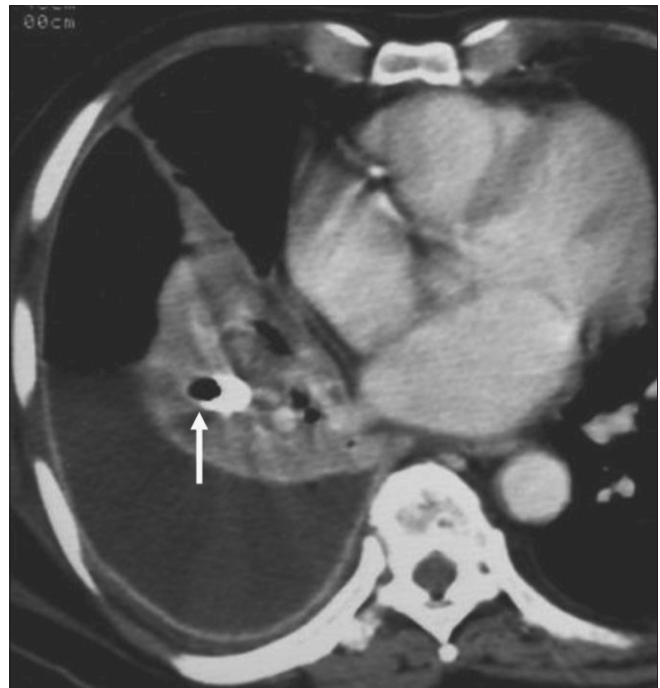
**Figure 4:** Frontal radiograph of a neonate shows inadvertent placement of an endotracheal tube in the esophagus (arrow) with distension of the esophagus and stomach (arrowheads) with air



**Figure 5:** Frontal chest radiograph shows complications of tracheostomy: pneumothorax (straight arrow), pneumomediastinum (curved arrow), and surgical emphysema (notched arrow)



**Figure 6:** Frontal chest radiograph shows moderate right pleural effusion. The intercostal drainage tube (arrow) was not functioning because of an abnormally low position



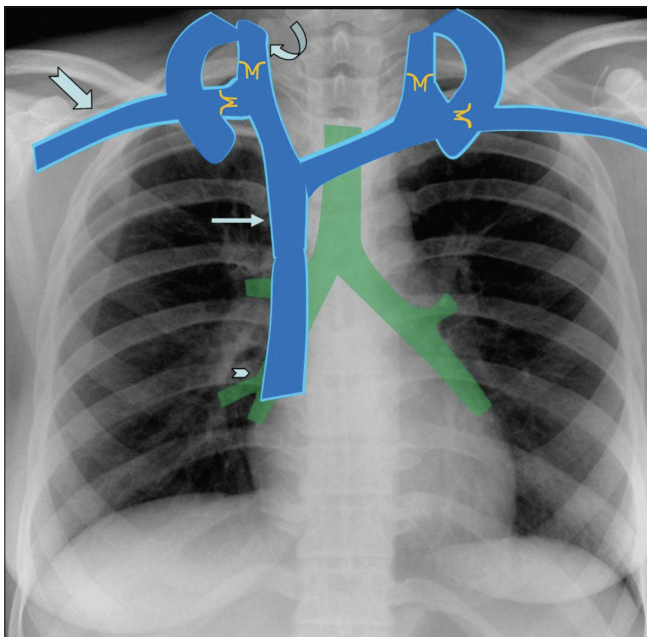
**Figure 7:** Contrast-enhanced axial CT image of the same patient as figure 6 demonstrates the tip of the intercostal drainage tube (arrow) within the lung

parenchyma [Figure 7]. Both frontal and lateral CXRs are necessary to ensure proper positioning of the chest tube. Mediastinal drains are usually present following sternotomy and, except for their position, resemble pleural tubes in all respects.

## Central Venous Lines

Central venous lines (catheters) are useful for a variety of purposes, e.g., hemodynamic pressure monitoring; hemodialysis; and administration of medications, nutrition, and fluids.<sup>[7]</sup> They provide long-term venous access. Central venous lines are inserted through major veins such as the subclavian, internal jugular, or femoral veins into the superior vena cava. The tip of the line should be distal to the last venous valve, which is located at the junction of the internal jugular and the subclavian veins. On the CXR, the position of the valve corresponds to the inner aspect of the first rib [Figure 8]. Many central venous lines have two or three lumens, each with a different orifice. If the tip of the line is positioned in the superior vena cava, all orifices will be distal to the last valve. On the CXR, the first anterior intercostal space corresponds to the approximate site of the junction of the brachiocephalic veins to form the superior vena cava [Figure 8]. On the CXR, the cavoatrial junction corresponds to the lower border of bronchus intermedius [Figure 8].<sup>[8]</sup> If the line tip reaches the right atrium, it can cause dysrhythmia or result in injection of undiluted toxic medications into the heart.

In about 30% of cases the initial radiographs show a malpositioned central venous line.<sup>[9]</sup> Complications vary with the type of line and the site of insertion.<sup>[10]</sup> Pneumothorax occurs in up to 6% of procedures and is more



**Figure 8:** Diagrammatic representation of the last valves in the internal jugular vein (curved arrow) and subclavian veins (notched arrow). The valves are located near the inner aspects of the first ribs. The brachiocephalic veins join to form the superior vena cava (straight arrow) near the 1<sup>st</sup> anterior intercostal space. The cavoatrial junction (arrowhead) is where the superior vena cava crosses the bronchus intermedius

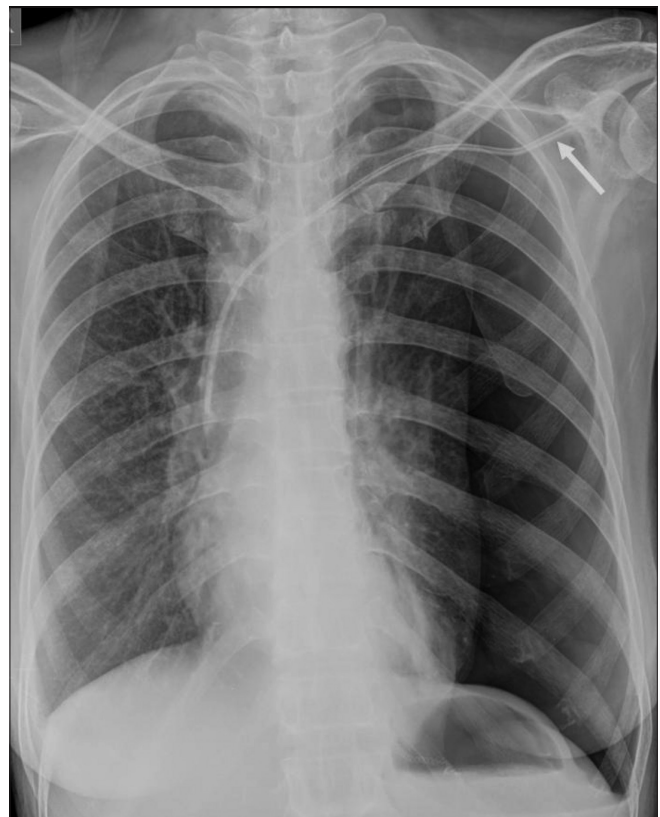
common with the subclavian approach [Figure 9].<sup>[5]</sup> If initial placement fails, a CXR before attempting the procedure on the other side helps avoid bilateral pneumothoraces.

If the central venous line tip abuts the venous wall there is a risk of vessel perforation, with resultant infusion of fluid into the mediastinum or pleural or pericardial space. On the CXR, this complication will appear as mediastinal widening [Figure 10], enlargement of the cardiac silhouette, or a new pleural effusion [Figure 11].

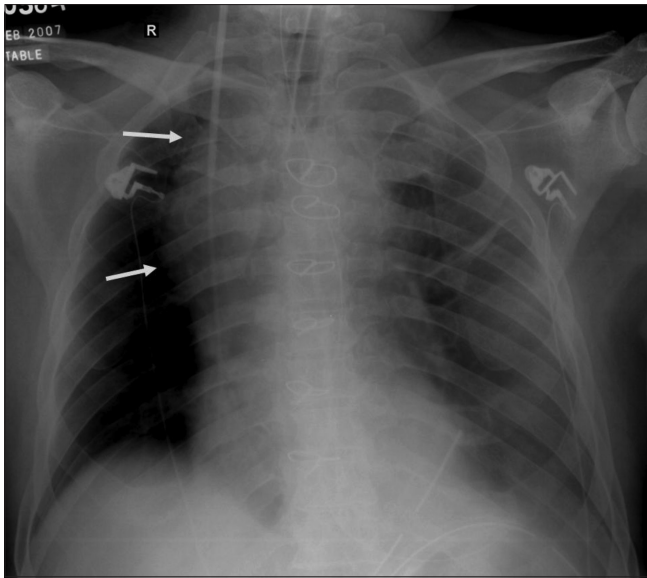
Other complications are abnormal course, cardiac perforation, and arrhythmias. Abnormal course of a central venous line or malpositioning occurs when it enters a tributary such as the azygos vein, subclavian vein, internal mammary vein, or an anomalous vein such as a persistent left-sided superior vena cava; the line may even enter the carotid vessels [Figure 12].<sup>[11]</sup>

## Pulmonary Artery (Swan-Ganz) Catheter

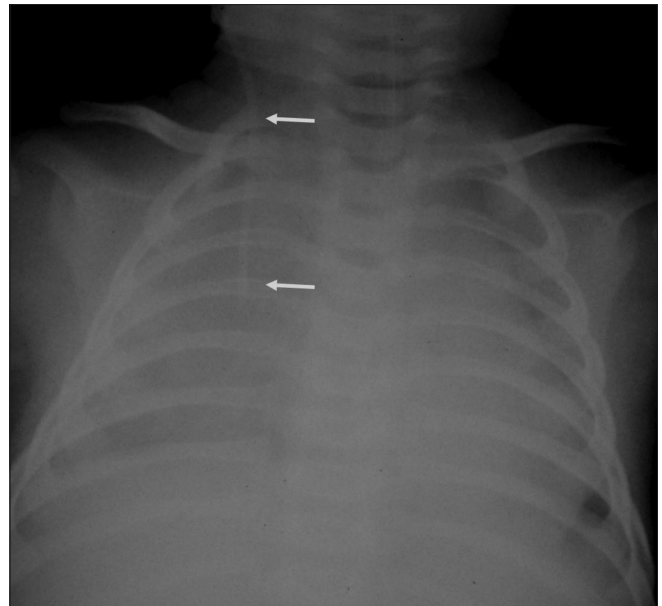
The Swan-Ganz catheter is a flow-directed balloon-tipped pulmonary artery catheter. The balloon is inflated to measure the capillary wedge pressure. This catheter is widely used for monitoring circulatory hemodynamics in the management of a variety of critical illnesses. To



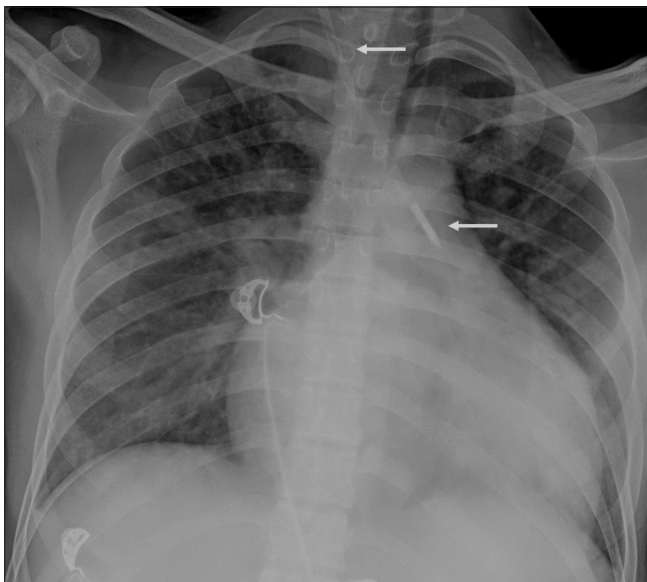
**Figure 9:** Frontal chest radiograph shows a left-sided pneumothorax following insertion of a central venous catheter. Note that the subclavian approach (arrow) was used for insertion of the catheter



**Figure 10:** Frontal chest radiograph following placement of a central venous catheter shows right paratracheal soft tissue with a bulging contour (arrows), due to mediastinal hematoma

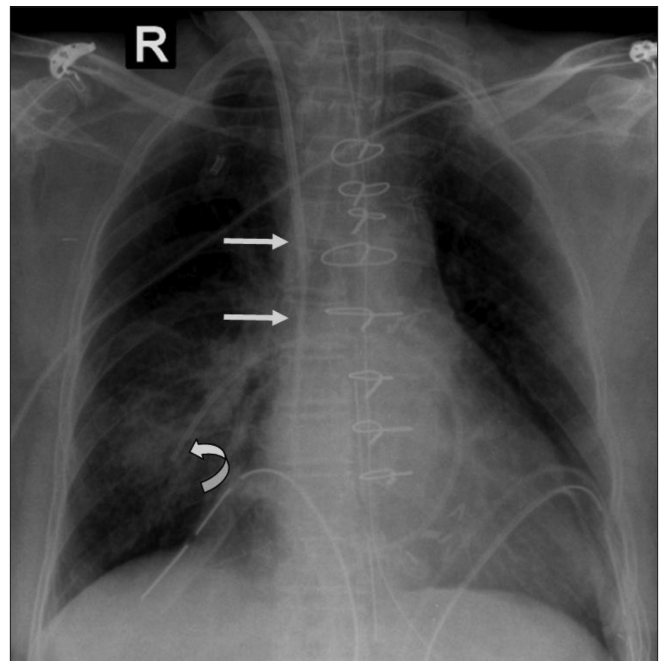


**Figure 11:** Frontal chest radiograph of a patient who was receiving fluids through a right jugular central venous catheter (arrows) shows an opaque right hemithorax (which was a fresh finding compared to earlier normal radiographs). This was due to vessel perforation by the catheter and resultant accumulation of fluid in the pleural space



**Figure 12:** Frontal chest radiograph shows an abnormally medial course of the catheter (arrows) in a case of inadvertent carotid cannulation

measure pulmonary artery pressure and capillary wedge pressure, the tip of catheter needs to be in the right or left pulmonary artery. To avoid complications, the tip of the Swan-Ganz catheter must not be more than 1 cm lateral to the mediastinal margin. The rule of thumb is that the catheter should not extend beyond the pulmonary hilum on the CXR; else, it should be retracted.<sup>[12]</sup> The complication rate of pulmonary infarction is reduced when the balloon is inflated only during pressure measurement and insertion. Potential complications are intracardiac knotting, pulmonary infarction [Figure 13], pulmonary



**Figure 13:** Frontal chest radiograph shows the tip (curved arrow) of a Swan-Ganz catheter (straight arrows) lying in the descending branch of the right pulmonary artery. The right paracardiac opacity is due to pulmonary infarction

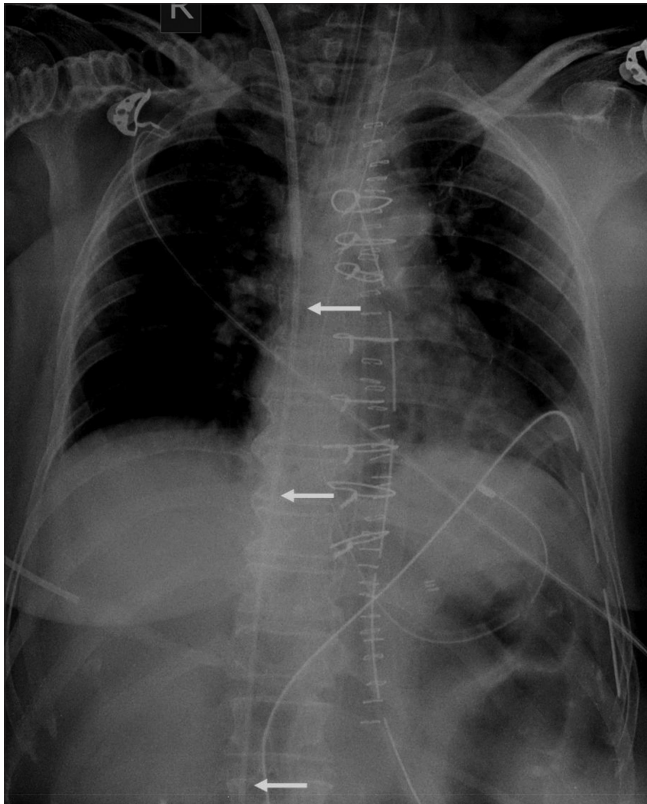
artery perforation, arrhythmias, cardiac perforation, and placement in the inferior vena cava [Figure 14].

### Intra-aortic Balloon Pump

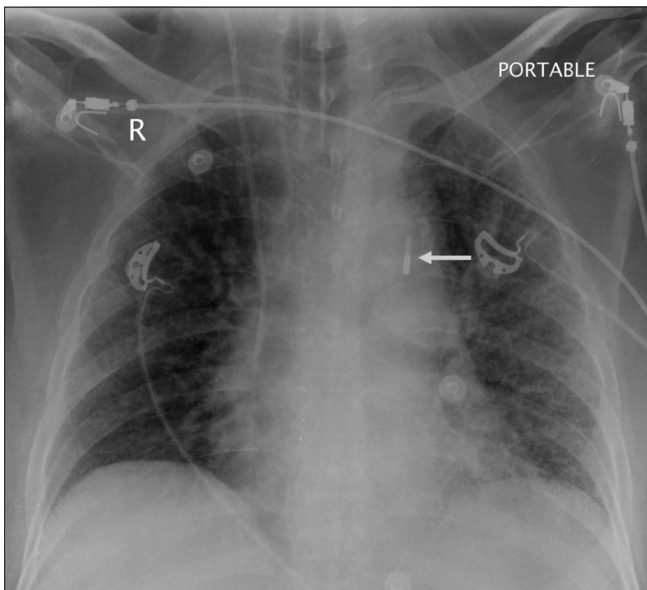
Intra-aortic balloon pump (IABP) is a long-balloon

temporary circulatory assist device that works on the principle of cardiac counter-pulsation. The IABP is used to support the circulation. The balloon, approximately 25-cm long, is mounted on a catheter. The catheter tip is visible as

a 3 × 4-mm rectangular metallic density while the rest of the catheter is radiolucent [Figure 15]. The catheter is inserted through the femoral artery. The balloon is inflated with gas during diastole and deflates during systole, resulting in increase in coronary blood flow and reduction in left ventricular afterload (and hence, reduction in myocardial oxygen consumption).<sup>[13]</sup> The various indications are acute myocardial infarction (MI) with cardiogenic shock, post-coronary artery bypass graft (high-risk cases with low ejection fraction of <20%), acute mitral insufficiency, and cardiac transplantation. It is contraindicated in aortic regurgitation, aortic dissection, and in the presence of a prosthetic graft in the thoracic aorta (within 12 months of surgery). To avoid occlusion of the left subclavian artery and visceral and renal arteries, its tip should be slightly cephalad to the adjacent carina (2<sup>nd</sup>–3<sup>rd</sup> intercostal space). The balloon should not occlude more than 85–90% of the aortic diameter. Balloon rupture with air embolization and septicemia are rare potential complications.



**Figure 14:** Frontal chest radiograph shows malposition of a Swan-Ganz catheter (arrows) in the inferior vena cava

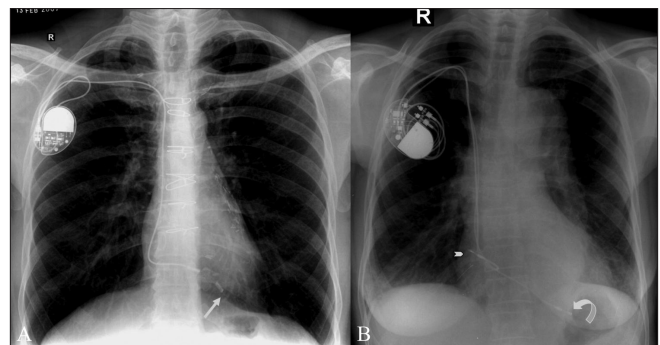


**Figure 15:** Frontal chest radiograph demonstrates an optimally positioned intra-aortic balloon pump catheter. The catheter tip is identified by a rectangular metallic density (arrow)

### Pacemaker

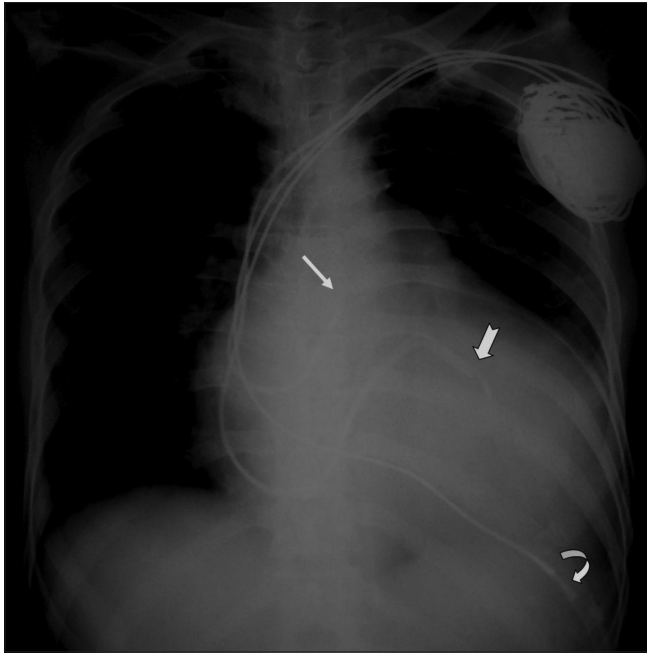
Pacemakers are used in cases of severe sinus node dysfunction, complete heart block, and various arrhythmias. They have two main elements: a pulse generator and a lead wire with electrodes. The single-lead pacemaker is the most basic type and is positioned with its tip in the right ventricular apex [Figure 16A]. An atrioventricular two-lead sequential pacemaker has one electrode in the right atrium and the other at the right ventricular apex [Figure 16B]. Sometimes a third lead is placed in the coronary sinus to pace the left ventricle [Figure 17]. It is not feasible to insert an electrode in the left side of the heart due to the high pressures in these chambers. Temporary epicardial wires are sometimes inserted during cardiac surgery; the tips of these wires resemble a corkscrew. They can be removed easily.

A lateral CXR is usually required to confirm the position



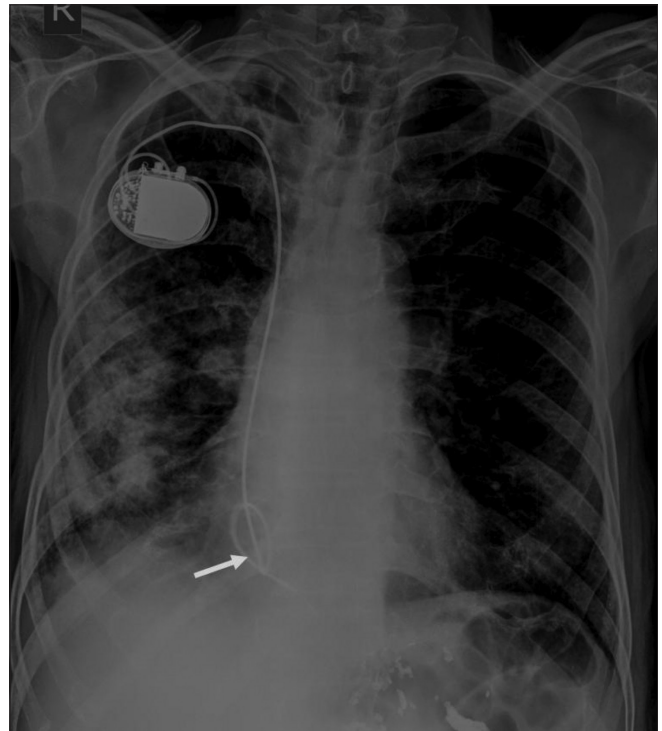
**Figure 16 (A, B):** Frontal chest radiograph (A) shows the optimal position of the electrode of a single-lead pacemaker. The electrode has been placed in the right ventricular apex (straight arrow). Frontal chest radiograph (B) shows a two-lead pacemaker that has one electrode in the right atrium (arrowhead) and the other at the right ventricular apex (curved arrow)

of the electrode in the right atrial appendage. The tip points anteriorly when correctly positioned. The tip may

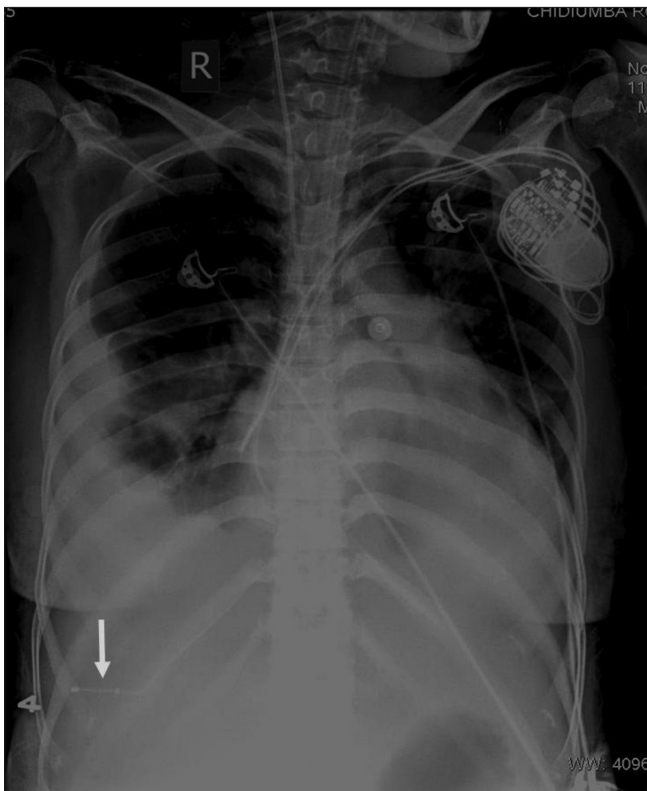


**Figure 17:** Frontal chest radiograph shows optimal position of a biventricular pacemaker. Besides the electrodes in the right atrium (straight arrow) and right ventricle (curved arrow), the third electrode is placed in the coronary sinus (notched arrow)

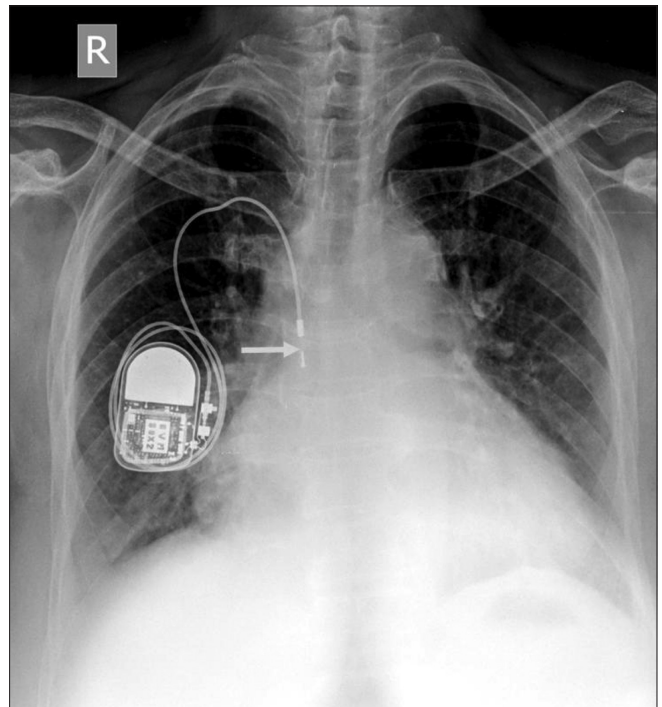
have a slight bend as it abuts the wall but there should no sharp bends. The potential complications are malposition, intracardiac knotting [Figure 18], fracture, perforation



**Figure 18:** Frontal chest radiograph shows coiling of the lead (arrow) of a single-lead pacemaker in the right atrium



**Figure 19:** Frontal chest radiograph shows abnormal course of the lead with the electrode tip overlying the liver (arrow). This was due to cardiac perforation by the pacemaker lead, with a fatal outcome

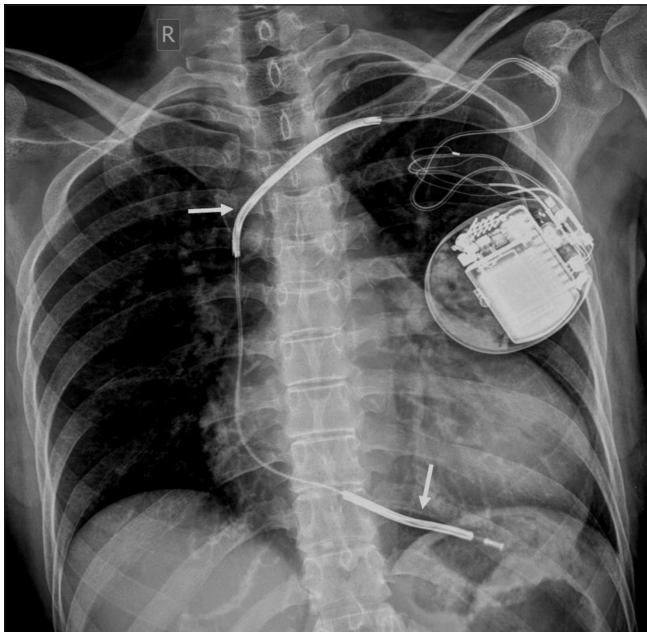


**Figure 20:** Frontal chest radiograph shows recoil of the pacemaker lead with its tip in the superior vena cava (arrow). This is called Twiddler's syndrome

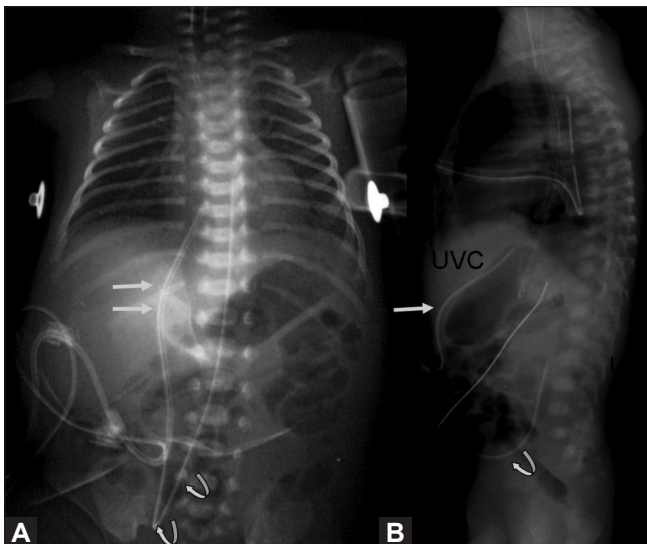
[Figure 19], cardiac tamponade, arrhythmias, infection, and hemorrhage. Twiddler's syndrome is a rare disorder in which twisting of the lead occurs either due to the patient's manipulation or spontaneously [Figure 20].

### Automated Implantable Cardioverter Debrillator

Automated implantable cardioverter defibrillator (AICD) is



**Figure 21:** Frontal chest radiograph of a patient with automated implantable cardioverter defibrillator. Dense bands (arrows) along the electrode are characteristic of this device



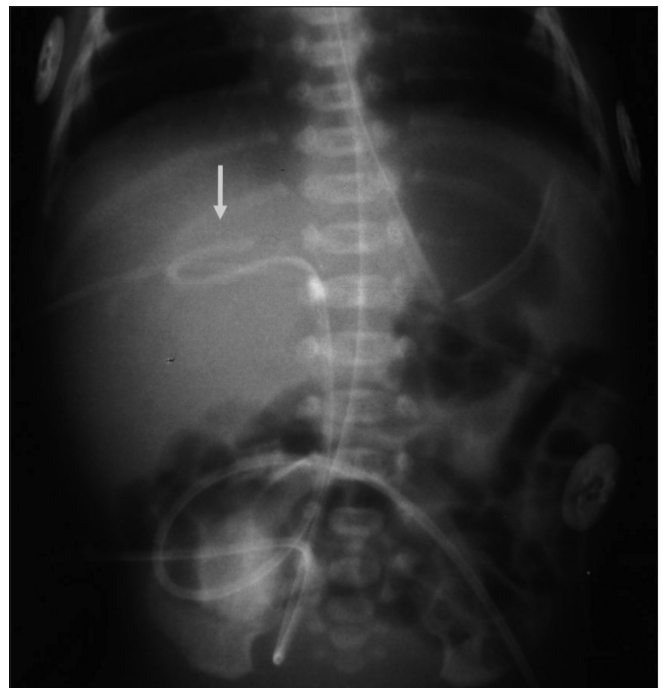
**Figure 22 (A, B):** Frontal (A) and lateral (B) radiographs of the chest and abdomen of a neonate demonstrate the correct position of an umbilical venous catheter (to the right of the spine) and an umbilical artery catheter (high position). Note the curve of the venous catheter as it passes through the portal sinus (arrows) and the classical dip of the arterial catheter in its proximal course (curved arrows)

used in cases of recurrent refractory ventricular tachycardia. It has two electrodes (one electrode in the right atrium and the other in the right ventricle). The lead is wider compared to the pacemaker lead and has a 'coiled-spring' appearance [Figure 21]. Complications are similar to those with transvenous pacemakers and the incidence of radiographical abnormalities may approach 20%.

### Pediatric Lines

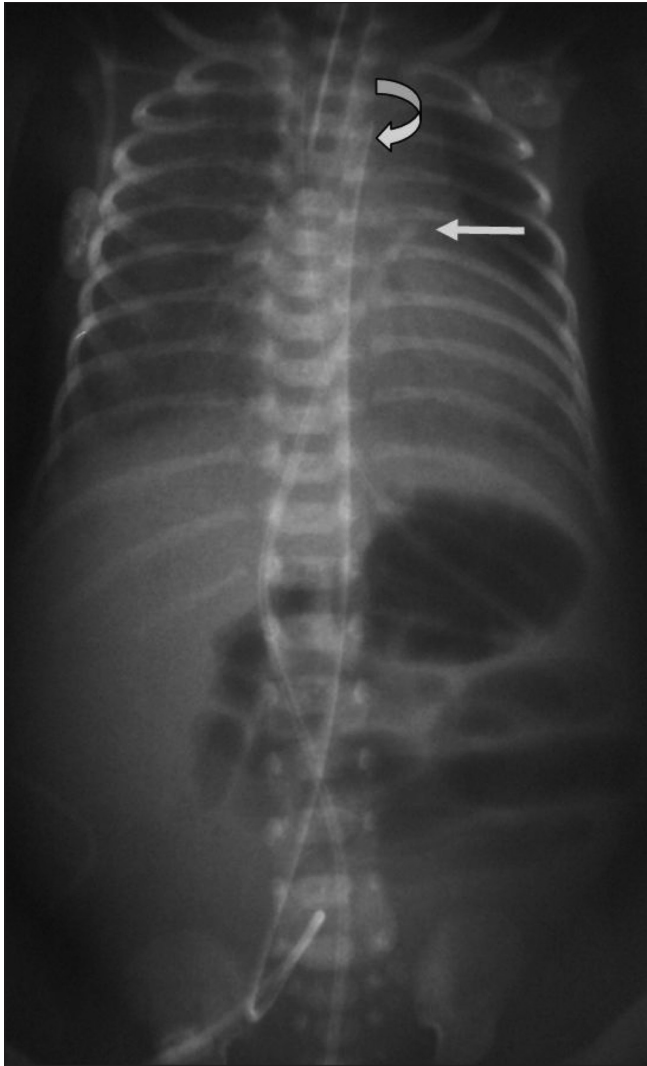
Some catheters are only used in the pediatric population, for example, the umbilical artery and venous catheters. They are used for vascular access for exchange transfusion; hyperalimentation; and measurement of blood gases, pressures, electrolytes, etc. The umbilical vein and arteries remain patent for up to 4–5 days after birth. The umbilical venous catheter courses anteriorly and cephalad in the midline, with posterior angulation in the liver [Figure 22]. The umbilical artery catheter initially dips into the pelvis to enter the iliac artery before coursing superiorly in the aorta [Figure 22].<sup>[14]</sup>

The umbilical venous catheter should reach the base of the right atrium or the cephalad portion of the inferior vena cava [Figure 22]. This is sometimes difficult to ascertain. The rule of thumb is that the tip should be approximately at the level of D8-D9 vertebrae. It lies on the right side on the anteroposterior radiograph. On the lateral CXR, it lies anteriorly [Figure 22]. The initial radiograph may show air in the portal system introduced during procedure. There



**Figure 23:** Frontal radiograph of the abdomen shows looping of an umbilical venous catheter in the liver (arrow) with its tip in the right branch of the portal vein





**Figure 24:** Frontal radiograph of the chest and abdomen of a neonate shows the tip of an umbilical venous catheter (straight arrow) in the left atrium; it has passed through a patent foramen ovale. The tip of the umbilical artery catheter (curved arrow) is in the arch of the aorta (which is undesirable as it is near the origin of the carotid artery)

should be no coiling, bend, or kink in the catheter. Insertion into the hepatic vein, peripheral portal vein [Figure 23], left atrium [Figure 24], right ventricle, or even into the pulmonary arteries can occur. Cardiac perforation, cardiac arrhythmias, valvular injury, and portal vein or pulmonary artery thrombosis are some of the complications.<sup>[15,16]</sup>

The umbilical artery catheter should be at the level of the D6-D10 vertebrae (high position) or at the level of the L3-4 vertebrae (low position) to ensure that its tip is away from the origins of vessels supplying vital organs (the carotids in the high position and the renal vessels in the low position). The high position is usually preferred. Thrombosis and ischemia are well-known complications. In contrast to the umbilical venous catheter, the umbilical artery catheter dips initially before it takes a path parallel to the spine on the left side [Figure 22]. On a lateral CXR, it lies posteriorly.

## Conclusion

The portable CXR is invaluable for monitoring the various indwelling devices used in critically ill patients. A systematic approach and knowledge of the radiographic features of the common indwelling tubes and lines is of the utmost importance.

## Acknowledgement

The author expresses his gratitude to Dr. Vinod Attarde and Dr. Ravi Varma for their valuable contribution.

## References

1. Aquino SL. Routine chest radiograph. ACR appropriateness criteria, 2006. American College of Radiology. Available from: <http://www.acr.org>. [Last accessed on 2011 Mar 12].
2. Bekemeyer WB, Crapo RO, Calhoun S, Cannon CY, Clayton PD. Efficacy of chest radiography in a respiratory intensive care unit. A prospective study. *Chest* 1985;88:691-6.
3. Hill JR, Horner PE, Primack SL. ICU Imaging. *Clin Chest Med* 2008;29:59-76.
4. Rubinowitz AN, Siegel MD, Tocino I. Thoracic Imaging in the ICU. *Crit Care Clin* 2007;23:539-73.
5. Gray P, Sullivan G, Ostryzniuk P, McEwen TA, Rigby M, Roberts DE. Value of postprocedural chest radiographs in the adult intensive care unit. *Crit Care Med* 1992;20:1513-8.
6. Brunel W, Coleman DL, Schwartz DE, Peper E, Cohen NH. Assessment of routine chest roentgenograms and the physical examination to confirm endotracheal tube position. *Chest* 1989;96:1043-5.
7. Funaki B. Central venous access: A primer for the diagnostic radiologist. *AJR Am J Roentgenol* 2002;179:309-18.
8. Webb WR. Pulmonary edema, the acute respiratory distress syndrome and radiology in the intensive care unit. In: Webb WR, Higgins CB, editors. *Thoracic imaging: Pulmonary and cardiovascular radiology*. 2<sup>nd</sup> ed. Philadelphia: Lippincott Williams and Wilkins; 2011. p. 348-74.
9. Tocino I. Chest imaging in the intensive care unit. *Eur J Radiol* 1996;23:46-57.
10. Dunbar RD. Radiological appearance of compromised thoracic catheters, tubes and wires. *Radiol Clin North Am* 1984;22:699-722.
11. Wiener MD, Garay SM, Leitman BS, Wiener DN, Ravin CE. Imaging of the intensive care unit patient. *Clin Chest Med* 1991;12:169-98.
12. Collins J, Stern EJ. Monitoring and support devices - "Tubes and Lines." In: *Chest radiology: The essentials*. Philadelphia: Lippincott Williams and Wilkins; 1999. p. 59-71.
13. Kazerooni EA, Gross BH. Lines, tubes, and devices. In: *Cardiopulmonary imaging*. Philadelphia: Lippincott Williams and Wilkins; 2004. p. 255-93.
14. Hogan MJ. Neonatal vascular catheters and their complications. *Radiol Clin North Am* 1999;37:1099-125.
15. Schlesinger AE, Braverman RM, DiPietro MA. Neonates and umbilical venous catheters: Normal appearance, anomalous positions, complications and potential aid to diagnosis. *AJR Am J Roentgenol* 2003;180:1147-53.
16. Cohan MD. Tubes, wires and the neonate. *Clin Radiol* 1980;31:249-56.

**Cite this article as:** Jain SN. A pictorial essay: Radiology of lines and tubes in the intensive care unit. *Indian J Radiol Imaging* 2011;21:182-90.

**Source of Support:** Nil, **Conflict of Interest:** None declared.