

Clinicopathoradiological findings in SEGA: A rare astroglial tumor

Sir,

A 7½-year-old male presented with features of raised intracranial symptoms. He had a history of delayed milestones, mental retardation and seizures since 4 years. Examination revealed multiple facial angiofibromas [Figure 1]. Computed tomography (CT) imaging showed a large hyperintense lobular lesion, approximately 55 mm×50 mm in the right fronto-temporo-parietal region, causing compression over the frontal horn of the right lateral and third ventricles, with midline shift and subfalcine herniation to left, and hydrocephalous [Figure 2]. Following surgery, subsequent histopathological findings revealed closely packed polygonal to round cells with eosinophilic glassy hyaline cytoplasm and eccentrically positioned vesicular nuclei and prominent nucleoli in a fibrillary background [Figure 3]. Hence, the diagnosis of Subependymal giant cell astrocytoma (SEGA) was made. Following surgery, the patient was relieved of symptoms with no recurrence of tumor on follow-up.

Subependymal giant cell astrocytoma is a rare, slow-growing intraventricular tumor arising classically in 6-16% cases of tuberous sclerosis (TS).^[1] TS is an autosomal dominant neurocutaneous phacomatosis with an incidence of 1 in 10,000. It comprises of hamartomatous tumors^[2] and malformations affecting multiorgan systems, the central nervous system (CNS) being the most commonly involved. CNS lesions include cortical tubers, subependymal nodules, white matter heterotrophies and subependymal giant cell astrocytomas.^[3] Other lesions include renal angiomyolipomas, cardiac rhabdomyomas and cystic lung disease, etc. Clinically, TS is characterized by Vogt's triad of mental retardation, seizures and adenoma sebaceum. SEGA are usually located in the lateral ventricles near the foramen of munro, causing obstructive hydrocephalus.^[4,5] Radiological findings include sharply marginated and uniformly enhancing lesion on CT and magnetic resonance imaging, with hydrocephalus and size >1cm³. Grossly, it is a sharply delineated, spherical or multinodular mass of fleshy grey-pink tissue, anchored to the ventricular wall over a broad front. Tumor has a good prognosis, and recurrence is rare after surgical resection. Hence, the need for having a high index of suspicion and early identification of SEGA in patients of tuberous sclerosis can help prevent complications.

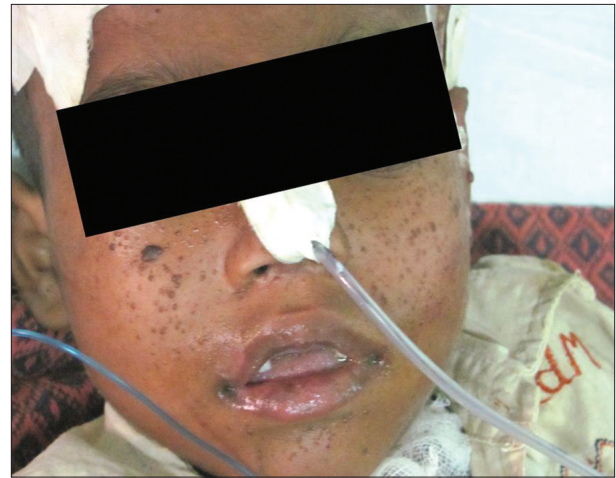

Figure 1: Clinical photograph demonstrating cutaneous adenoma sebaceum

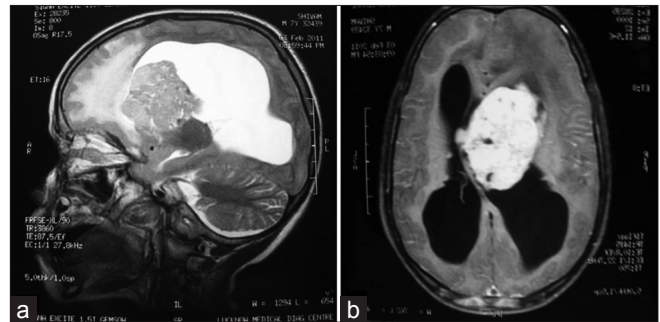


Figure 2: (a) T2 sagittal image: Large periventricular SOL is noted adjacent to the body and frontal horn of the left lateral ventricle. (b) T1 post-contrast axial image showing intraventricular extension of the same mass causing obstruction of the foramen of munro with non-communicating hydrocephalus

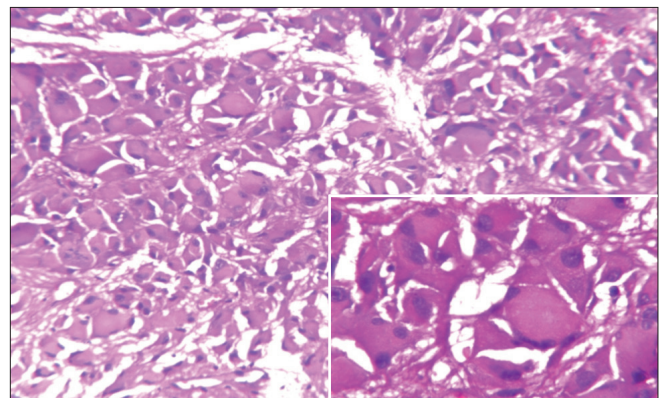


Figure 3: Microphotograph showing closely packed large polygonal to round cells with glassy hyaline eosinophilic cytoplasm and eccentric vesicular nucleus and prominent nucleoli in a fibrillary background (hematoxylin and eosin, ×100). Inset showing higher magnification (hematoxylin and eosin, ×400) of the same

ACKNOWLEDGMENT

The author would like to thank Prof. Nuzhat Husain and Prof. B. K. Ojha for their helpful discussions. The author is also grateful to parents of the ailing child to provide consent for publication.

Nidhi Verma, Suresh Babu, Atin Singhai, Chani Gupta

*Department of Pathology, C.S.M. Medical University,
(Formerly King George Medical University),
Lucknow, Uttar Pradesh, India
E-mail: rubyruby2k4@yahoo.com*

REFERENCES

1. Frerebeau P, Benezech J, Segnarbieux F, Harbu H, Dessy A, Marty Double C: Intraventricular tumors in tuberous sclerosis, Intraventricular tumors in Tuberous Sclerosis, Child's Nerv Syst 1985;1:45-8.
2. Roach ES, Gomez MR, Northrup H. Tuberous sclerosis complex consensus conference: Revised clinical diagnostic criteria. J Child Neurol 1998;13:624-8.
3. Grajkowska W, Kotulska K, Jurkiewicz E, Matyja E. Brain lesions in tuberous sclerosis complex. Review. Folia Neuropathol 2008;48:139-49.
4. Kim SH, Lee HW, Shin HJ, Nam DH, Kim ES, Eoh W, Clinicopathological analysis of Subependymal Giant Cell Astrocytomas in Childhood, J Korean Neurosurg soc 2004;35:12-6
5. Goh S, Butler W, Thiele EA. Subependymal giant cell tumors in tuberous sclerosis complex. Neurology 2004;63:1457-61.

Access this article online

Quick Response Code:



Website:

www.ijmpo.org

DOI:

10.4103/0971-5851.103158

Announcement

Android App



Download
**Android
application**

FREE

A free application to browse and search the journal's content is now available for Android based mobiles and devices. The application provides "Table of Contents" of the latest issues, which are stored on the device for future offline browsing. Internet connection is required to access the back issues and search facility. The application is compatible with all the versions of Android. The application can be downloaded from <https://market.android.com/details?id=comm.app.medknow>. For suggestions and comments do write back to us.