

# Sebaceous carcinoma and systemic chemotherapy

Poonam Joshi, Amit Joshi<sup>1</sup>,  
Vanita Norohna<sup>1</sup>,  
Kumar Prabhaskar<sup>1</sup>,  
Subhdha Kane<sup>2</sup>, Anil K. D'cruz

Departments of Head & Neck  
Surgery, <sup>1</sup>Medical Oncology, and  
<sup>2</sup>Pathology, Tata Memorial Hospital,  
Mumbai, Maharashtra, India

## Address for correspondence:

Dr. Poonam Joshi,  
Flat No. 207, Vishwakarma Tower,  
Aruna Asif Ali CHS,  
Plot No. 4, Sector-21,  
Kharghar, Navi Mumbai - 410 210,  
Maharashtra, India.  
E-mail: drpunamjoshi@  
rediffmail.com

## ABSTRACT

Sebaceous gland carcinoma is a rare malignant tumor, which arises from the adnexal epithelium of sebaceous glands. Sebaceous glands are present all over the body and hence have variable sites of origin, histological growth patterns, and clinical presentations. Here, we report a case of recurrent extraocular sebaceous carcinoma of left occipital region with lung metastases who went into complete remission with chemotherapy for lung metastasis. Role of chemotherapy in the management of metastatic sebaceous carcinoma is evolving. Combination chemotherapy can result in long term remission as described in this case report.

**Key words:** Chemotherapy, lung metastasis, sebaceous carcinoma

## INTRODUCTION

Sebaceous carcinoma may occur in either ocular or extraocular locations. It forms less than 1% of all cutaneous malignancies.<sup>[1]</sup> In the ocular region upper eyelid is the most common site of occurrence. SC of extraocular origin in the head is considered less locally aggressive and rarely tends to develop metastases as compared to ocular SC.<sup>[2]</sup> Approximately 25% of sebaceous carcinomas arise in extraocular sites, most commonly on the head and neck.<sup>[3]</sup> So far only few cases of extra orbital sebaceous carcinoma are reported in the literature.<sup>[1]</sup> Sebaceous cell carcinoma is a disease of the sixth and seventh decade of life and occurs in men and women equally.<sup>[4]</sup> We present a case of recurrent sebaceous carcinoma in a young 21-year-old male, with lung metastasis achieving complete remission at 6 months post treatment. This case is unique in itself as complete remission persisted for 6 months with chemotherapy and there are only 2 cases of complete response as reported in literature which lasted for only 3 months.

## CASE REPORT

A 21-year-old male presented to the head and neck oncology clinic with a history of recurrent lesion in left occipital region. He had a swelling in the left occipital region 1 year back. Although the swelling had been largely asymptomatic, patient sought medical opinion at a local hospital, due to its rapidly growing size and the presence of ulceration. The lesion was mobile with small area of ulceration in center. According to the CT scan findings, there was a soft tissue lesion  $4.2 \times 2.5$  cm<sup>2</sup> in subcutaneous tissue in posterior occipital region with no bony erosion or intracranial extension and a diagnosis of sebaceous cyst was made. Excision of the swelling was done but specimen was not sent for histopathological examination (HPE). Again, patient developed recurrence at the local site after 4 months. This was followed by excision of the swelling and this time the specimen was sent for HPE. The report came as sebaceous carcinoma and the patient was kept under follow up. After 3 months, patient again developed local recurrence and this time he sought medical advice at our oncology clinic. The swelling was  $2 \times 2$  cm<sup>2</sup> in size, subcutaneous, and mobile present at previous scar site in left occipital region. CT scan was suggestive of  $2.1 \times 2 \times 1$  cm<sup>2</sup> lesion with subtle outer cortex erosion. Wide excision of the lesion was planned. Chest X-ray done for pre-anaesthetic check up was suggestive of nodular opacity in right middle lobe of lung. Following which, CT thorax was done. It was suggestive of multiple B/L lung opacities [Figures 1 and 2]. FNAC of the swelling at left

## Access this article online

### Quick Response Code:



Website:  
www.ijmpo.org

DOI:  
10.4103/0971-5851.107105

occipital region and the bsiopsy of lung nodule [Figure 3] both were sebaceous carcinoma. The patient underwent local excision with local rotation flap followed by systemic chemotherapy for lung metastasis. The patient received six cycles of 3 weekly paclitaxel (175 mg/m<sup>2</sup>) and carboplatin (Area under curve-5). Patient tolerated the chemotherapy well without any grade III or IV toxicities. Post three cycles of chemotherapy, the lung metastases had completely resolved on CT scan and patient was symptomatically better. CT scan done 6 months after completion of chemotherapy [Figures 4 and 5] revealed that patient was still in complete remission. The primary site as well was controlled and the patient was doing well.

## DISCUSSION

Sebaceous gland carcinoma is a rare but aggressive cutaneous tumor first well described by Allaire in 1891. This is controversial whether the ocular and extraocular SC differ in their biological behavior, recurrence pattern, and distant metastasis. Most reports conclude that

carcinoma in the orbital area is more aggressive.<sup>[5,6]</sup> Rao reported 104 cases of ocular SC with 23 deaths caused by metastases (22%).<sup>[6]</sup> The metastatic potential of extraocular SC is still not well-defined due to paucity of cases and adequate follow up. Mellette, *et al.* for instance found that the biological behavior of extraorbital sebaceous carcinoma is not different from the orbital sebaceous carcinoma.<sup>[7]</sup> The series by Wick, King showed that distant metastases to liver, lung, bone, and brain occurred in patients with extraorbital sebaceous carcinoma.<sup>[8]</sup>

The mainstay of treatment of SC is surgical excision. For regional and metastatic disease, radiation, and chemotherapeutic drugs have been used with varying degrees of response. Only a few studies have shown use of adjuvant chemotherapy in treatment of sebaceous carcinoma and metastasis. There is one such report of complete response to systemic chemotherapy in metastatic sweat gland carcinoma to pleura, pericardium and chest wall with 5-fluorouracil after follow up of 3 months.<sup>[9]</sup> Another study showed significant eyelid and orbital tumor volume

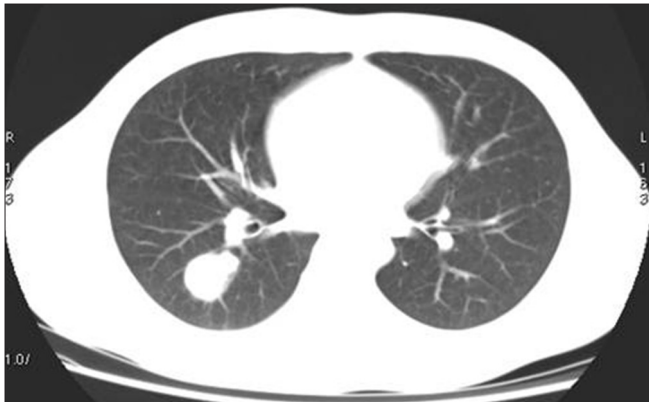

Figure 1: Lung metastasis right lung

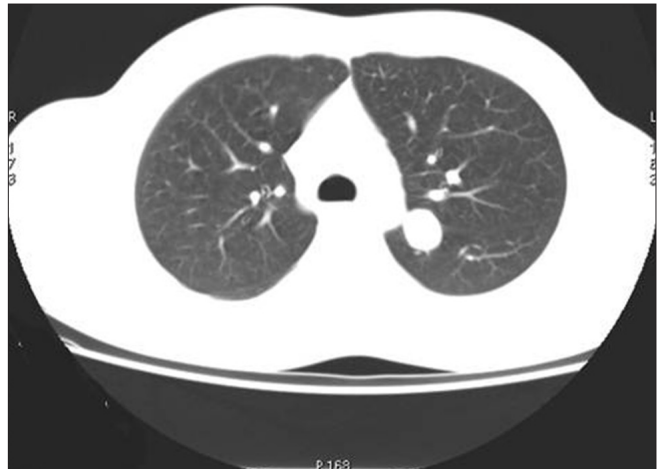

Figure 2: Lung metastasis left lung

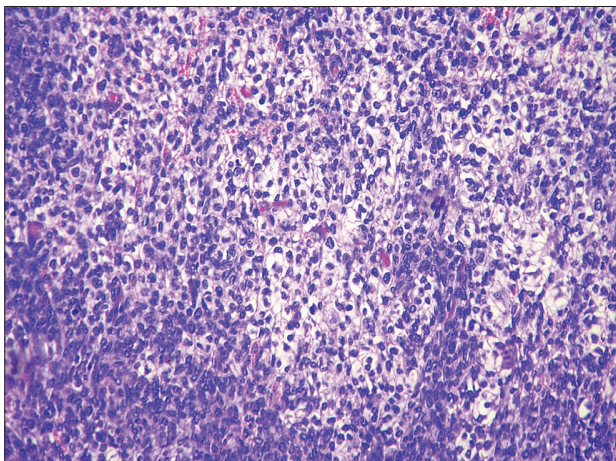


Figure 3: H and E  $\times 40$  slide of lung biopsy shows tumor composed of lobules of variably atypical polygonal cells having abundant cytoplasm with vesicular nuclei and distinct nucleoli. At places tumor cells show foamy cytoplasm

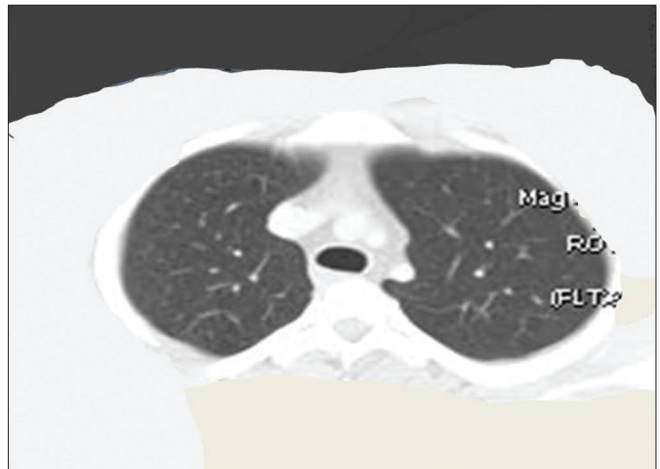
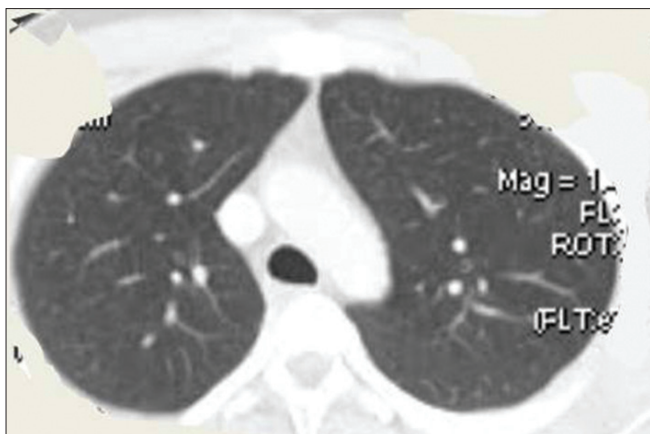


Figure 4: Complete remission of lung nodule



**Figure 5:** Complete remission of lung nodules

reduction with neoadjuvant chemotherapy carboplatin and 5-fluorouracil, making eyelid-sparing orbital exenteration possible.<sup>[10]</sup>

Our case report is the first in literature, in which patients had complete clinicoradiological response with combination of paclitaxel and carboplatin for lung metastasis. This shows that chemotherapy can be a good option in treatment of sebaceous carcinoma with metastasis as our patient showed complete remission of lung metastasis and was disease free after 6 months of treatment. But long term follow up of the patient is needed to see for actual disease free period. New chemotherapeutic regimens need to be evaluated in treatment of sebaceous carcinoma as our case report has shown combination of carboplatin and paclitaxel as a promising treatment option.

## REFERENCES

1. Ghosh SK, Bandyopadhyay D, Gupta S, Chatterjee G, Ghosh A. Rapidly growing extraocular sebaceous carcinoma occurring during pregnancy: A case report. *Dermatol Online J* 2008;14:8.
2. Reina RS, Parry E. Aggressive extraocular sebaceous carcinoma in a 52-year-old man. *Dermatol Surg* 2006;32:1283-6.
3. Wick MR, Goellner JR, Wolfe JT 3<sup>rd</sup>, Su WP. Adnexal carcinomas of the skin II. Extraocular sebaceous carcinomas. *Cancer* 1985;56:1163-72.
4. Bhavarajua VM, Shamim SE, Naik VR, Shaari S. Sebaceous cell carcinoma of scalp. A rare presentation. *Malays J Med Sci* 2007;14:67-70.
5. Russel WG, Page DL, Hough AJ, Rogers LW. Sebaceous carcinoma of the meibomian gland origin. *Am J Clin Pathol* 1980;73:504-11.
6. Rao NA, Hidayat AA, McLean IW, Zimmerman LE. Sebaceous carcinomas of the ocular adnexa: A clinicopathologic study of 104 cases, with five-year follow-up data. *Hum Pathol* 1982;13:113-22.
7. Mellette JR, Amonette RA, Gardner JH, Chesney TM. Carcinoma of sebaceous glands on the head and neck. A report of four cases. *J Dermatol Surg Oncol* 1981;7:404-7.
8. King DT, Hirose FM, Gurevitch AW. Sebaceous carcinoma of the skin with visceral metastasis. *Arch Dermatol* 1979;115:862-3.
9. Swanson JD Jr, Pazdur R, Sykes E. Metastatic sweat gland carcinoma: Response to 5-fluorouracil infusion. *J Surg Oncol* 1989;41:69-72.
10. Murthy R, Honavar SG, Burman S, Vemuganti G, Naik MN, Reddy VA. Neoadjuvant chemotherapy in the management of sebaceous gland carcinoma of the eyelid with regional lymph node metastasis. *Ophthal Plast Reconstr Surg* 2005;21:307-9.

**How to cite this article:** Joshi P, Joshi A, Norohna V, Prabhaskar K, Kane S, D'cruz AK. Sebaceous carcinoma and systemic chemotherapy. *Indian J Med Paediatr Oncol* 2012;33:239-41.  
**Source of Support:** Nil, **Conflict of Interest:** None declared.