

Primary anaplastic astrocytoma of the brain after prophylactic cranial irradiation in a case of acute lymphoblastic leukemia: Case report and review of the literature

Imtiaz Ahmed,

Sapna Krishnamurthy,

Aanchal Kakkar¹,

Pramod Kumar Julka,

Goura Kishor Rath

Departments of Radiotherapy and Oncology and ¹Pathology, All India Institute of Medical Sciences, New Delhi, India

Address for correspondence:

Dr. Imtiaz Ahmed,
Department of Radiotherapy and Oncology, All India Institute of Medical Sciences, New Delhi, India.
E-mail: imtizr@gmail.com

ABSTRACT

A 6½-year-old boy had developed acute lymphoblastic leukemia and was treated with systemic chemotherapy, intrathecal triple drug regimen and prophylactic cranial irradiation. After 10 years he developed anaplastic astrocytoma of the postero-superior cerebellum on the left side while leukemia was in remission. He was treated with surgical excision, followed by adjuvant three dimensional conformal radiotherapy and is on salvage chemotherapy with temozolamide. It is possible that the anaplastic astrocytoma may be a radiation induced malignancy.

Key words: *Acute lymphoblastic leukemia, anaplastic astrocytoma, prophylactic cranial irradiation*

INTRODUCTION

Acute lymphoblastic leukemia (ALL) is the most common malignancy in children. Currently, the overall 5 year relative survival is 80%. Curative therapy includes multi-agent chemotherapy and prophylaxis against central nervous system (CNS) leukemia with intrathecal chemotherapy and/or cranial radiation.

Cranial irradiation has been shown to result in increasing survival of children with ALL.^[1] However with increasing survival, there is an increasing risk of secondary brain tumors after cranial irradiation.^[2-4] Gliomas, meningiomas and sarcomas are the most frequent.^[5] We report a case of child in whom anaplastic astrocytoma developed after prophylactic whole brain irradiation for the treatment of ALL.

CASE REPORT

This was a case report of a 6-year-old boy who was diagnosed with ALL-L2 (French American British Classification) in 2001 and was treated as per multi center protocol (MCP) 843 protocol. Prophylactic irradiation to whole brain with cobalt 60 γ rays to a total dose of 1800 cGy in 10 fractions at 180 cGy/fraction was given from 13th to 23rd September 2001. In December 2003, all medications were stopped after proving complete remission by bone marrow examination.

In April 2011, nearly 10 years post-radiotherapy, he presented with speech difficulty and gait ataxia of 3 months duration. On examination, apart from subnormal intelligence and cerebellar signs he had no other deficits. Magnetic resonance imaging-brain showed – An ill-marginated infiltrating mass lesion in postero-superior cerebellar hemisphere with extension across the midline to involve left cerebellar hemisphere, compressing and displacing the 4th ventricle [Figure 1].

He underwent midline sub occipital craniotomy and gross total excision of the tumor. Histopathology examination showed a moderately cellular tumor with a fibrillary background infiltrating into the cerebellar parenchyma

Access this article online

Quick Response Code:



Website:
www.ijmpo.org

DOI:
10.4103/0971-5851.133729

[Figure 2a]. The tumor cells displayed moderate nuclear pleomorphism and frequent mitotic figures, including atypical forms [Figure 2b]. Tumor cells were immunopositive for glial fibrillary acidic protein [Figure 2c] and p53. MIB-1 labeling index was approximately 25% in the highest proliferating areas [Figure 2d]. A diagnosis of anaplastic astrocytoma, World Health Organization grade III, was made. Post-operatively he was treated with adjuvant radiation therapy with three dimensional conformal radiotherapy to a dose of 60 Gy in 30 fractions at 2 Gy/fraction. Post- radiotherapy, at 6 weeks follow-up, he had residual disease and hence was started on salvage chemotherapy with temozolamide. Presently, patient has only cerebral ataxia and no evidence of ALL.

DISCUSSION

Although most children with ALL become 5 year survivors, second malignancies and other adverse events reduce long-term survival.^[3-6] At 15 year cumulative incidence of second malignancies for ALL survivors is about 2.5-4%. However, with increasing duration of follow-up a cumulative incidence of 6% at 30 years is noted. The most commonly observed secondary malignancies include CNS tumors, leukemias/lymphomas and skin cancers. Risk factors associated with secondary malignancies in ALL survivors include, age at diagnosis (age <5 years), female sex, prophylactic cranial/cranial spinal irradiation (PCI/CSI), and relapsed cases.^[3] Gilman and Miller^[7] have explained the possible pathogenesis for secondary malignancies, as intrinsic - due to pleiotropic gene action, cytogenetic abnormalities associated with ALL, or immunoregulatory dysfunction; or extrinsic - due to carcinogen that caused ALL, and the treatment administered - as a mere chance of coincidence.

Induction of second malignancies after radiation is well-recognized. This risk was first recognized among children

who developed brain tumors after radiation therapy for tinea capitis in the 1940s and 1950s, and was reported among children exposed to as little as 2.5 Gy. Most common second malignancies in CNS include gliomas and meningiomas. The first fully documented case of CNS glioma following prophylactic treatment of ALL was reported in 1979.^[8] Similar cases have been reported, which is systematically evaluated by Bowers *et al.*^[9] and concluded that survivors of childhood cancer who received cranial radiation therapy have an increased risk for subsequent CNS neoplasms.

The standardized incidence ratios for subsequent gliomas ranged from 8.9 to 24.3. The interval between first cancer diagnosis and diagnosis of a subsequent high-grade glioma was 8-20 years.^[9] There is a linear correlation between the dose of cranial radiation and relative risk of subsequent high-grade gliomas, odds ratios (ORs) for subsequent glioma increased with a dose of radiation exposure and peaked at exposures of 30-44.9 Gy (OR-21).^[9]

At 5-year survival for patients with subsequent high-grade gliomas ranged from 0% to 19.5%, which is similar to the 5 year survival rate of 16.6% reported in young adults in the general population.^[9]

Well-accepted criteria have been established to show a causal relationship between radiotherapy and occurrence of subsequent neoplasm. These includes prolonged delay between irradiation and detection of a second tumor, second malignancy occurring in the irradiated field, histology of the second tumor differs from the initial neoplasm and the incidence of the second lesion is significantly higher than in controls.^[10]

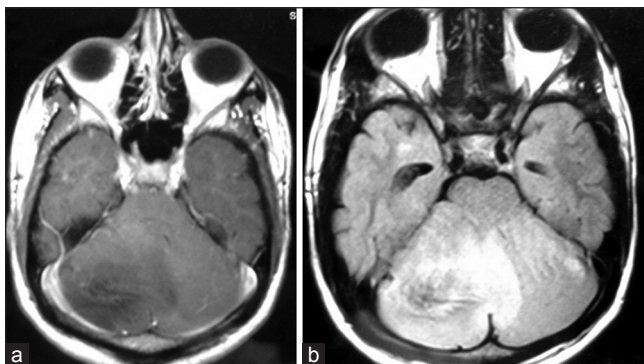


Figure 1: (a) T1contrast showing homogeneously hypointense lesion with minimal patchy enhancement in cerebellum (b) T2 fluid attenuated inversion recovery showing homogeneously hypertintense lesion in cerebellum

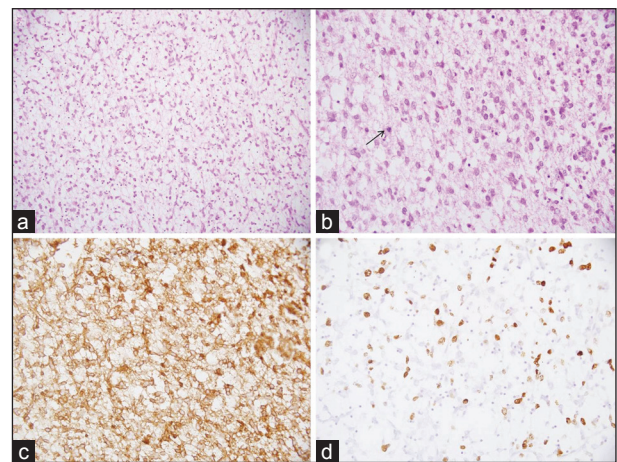


Figure 2: Photomicrographs of the tumor showing moderate cellularity in a fibrillary background (a, H and E, x200). The tumor cells show moderate nuclear pleomorphism, frequent mitoses (arrow) (b, H and E, x400), immunopositivity for glial fibrillary acidic protein (c, immunohistochemical [IHC]; x400) and high MIB-1 labeling index (d, IHC; x400)

Our case report clearly demonstrates that a possible radiation induced high-grade glioma in the previously irradiated area, as there is in field occurrence of a second type of malignancy, which is histological different from the initial primary leukemic cause, after 10 years of radiation.

In addition this is the first report of a secondary anaplastic astrocytoma developing in the cerebellum in a treated case of ALL.

CONCLUSION

Long-term survivors of patients treated for ALL possibly have increased risk of developing secondary CNS neoplasm especially those who have received cranial irradiation; and that these tumors are of high grade, aggressive clinical behavior and less amenable for treatment.

REFERENCES

1. Pui CH, Robison LL, Look AT. Acute lymphoblastic leukaemia. *Lancet* 2008;371:1030-43.
2. Neglia JP, Meadows AT, Robison LL, Kim TH, Newton WA, Ruymann FB, *et al.* Second neoplasms after acute lymphoblastic leukemia in childhood. *N Engl J Med* 1991;325:1330-6.
3. Friedman DL, Whitton J, Leisenring W, Mertens AC, Hammond S, Stovall M, *et al.* Subsequent neoplasms in

- 5-year survivors of childhood cancer: The Childhood Cancer Survivor Study. *J Natl Cancer Inst* 2010;102:1083-95.
4. Hope AJ, Mansur DB, Tu PH, Simpson JR. Metachronous secondary atypical meningioma and anaplastic astrocytoma after post-operative craniospinal irradiation for medulloblastoma. *Childs Nerv Syst* 2006;22:1201-7.
5. Armstrong GT, Liu Q, Yasui Y, Huang S, Ness KK, Leisenring W, *et al.* Long-term outcomes among adult survivors of childhood central nervous system malignancies in the Childhood Cancer Survivor Study. *J Natl Cancer Inst* 2009;101:946-58.
6. Pui CH, Cheng C, Leung W, Rai SN, Rivera GK, Sandlund JT, *et al.* Extended follow-up of long-term survivors of childhood acute lymphoblastic leukemia. *N Engl J Med* 2003;349:640-9.
7. Gilman PA, Miller RW. Cancer after acute lymphocytic leukemia. *Am J Dis Child* 1981;135:311-2.
8. Walters TR. Childhood acute lymphocytic leukemia with a second primary neoplasm. *Am J Pediatr Hematol Oncol* 1979;1:285-7.
9. Bowers DC, Nathan PC, Constine L, Woodman C, Bhatia S, Keller K, *et al.* Subsequent neoplasms of the CNS among survivors of childhood cancer: A systematic review. *Lancet Oncol* 2013;14:e321-8.
10. Cahan WG, Woodard HQ. Sarcoma arising in irradiated bone; report of 11 cases. *Cancer* 1948;1:3-29.

How to cite this article: Ahmed I, Krishnamurthy S, Kakkar A, Julka PK, Rath GK. Primary anaplastic astrocytoma of the brain after prophylactic cranial irradiation in a case of acute lymphoblastic leukemia: Case report and review of the literature. *Indian J Med Paediatr Oncol* 2014;35:86-8.

Source of Support: Nil. **Conflict of Interest:** None declared.

Author Help: Online submission of the manuscripts

Articles can be submitted online from <http://www.journalonweb.com>. For online submission, the articles should be prepared in two files (first page file and article file). Images should be submitted separately.

1) **First Page File:**

Prepare the title page, covering letter, acknowledgement etc. using a word processor program. All information related to your identity should be included here. Use text/rtf/doc/pdf files. Do not zip the files.

2) **Article File:**

The main text of the article, beginning with the Abstract to References (including tables) should be in this file. Do not include any information (such as acknowledgement, your names in page headers etc.) in this file. Use text/rtf/doc/pdf files. Do not zip the files. Limit the file size to 1 MB. Do not incorporate images in the file. If file size is large, graphs can be submitted separately as images, without their being incorporated in the article file. This will reduce the size of the file.

3) **Images:**

Submit good quality color images. Each image should be less than 4096 kb (4 MB) in size. The size of the image can be reduced by decreasing the actual height and width of the images (keep up to about 6 inches and up to about 1800 x 1200 pixels). JPEG is the most suitable file format. The image quality should be good enough to judge the scientific value of the image. For the purpose of printing, always retain a good quality, high resolution image. This high resolution image should be sent to the editorial office at the time of sending a revised article.

4) **Legends:**

Legends for the figures/images should be included at the end of the article file.