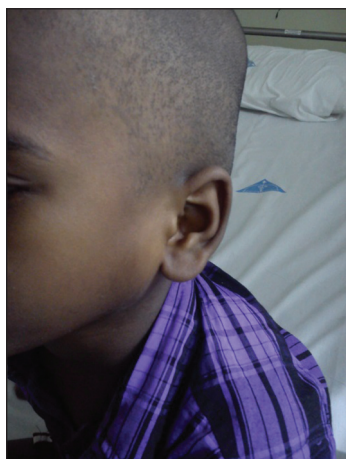


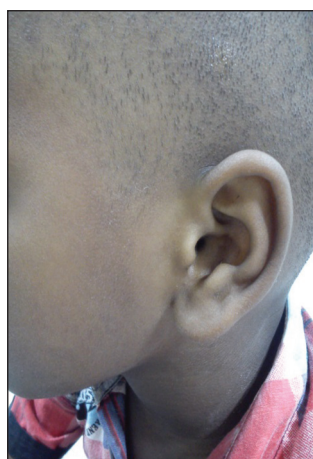# Acute transient parotitis in a child with primitive neuroectodermal tumor after a standard dose etoposide

Sir,

A 4-year-old male child, known case of non-metastatic primitive neuroectodermal tumor of right lower back was being treated as per children oncology protocol, which includes vincristine, doxorubicin, cyclophosphamide alternating with etoposide and ifosfamide. The child was admitted for the 2<sup>nd</sup> cycle of chemotherapy consisting of ifosfamide and etoposide. After his first dose of etoposide and ifosfamide, he developed swelling below the left ear, 24 h after the completion of the drug infusion. The swelling was 2 cm × 1.5 cm, firm, tender and the child had minimal restriction in opening the mouth [Figure 1]. He was suspected to have mumps and mumps serology and serum lipase was sent subsequently.



**Figure 1:** Swelling over the left parotid area noted 24 h after etoposide



**Figure 2:** Complete resolution of the swelling after 12 h of noticing it

Pediatric surgery opinion was sought and he was not found to have any signs of inflammation of the parotid gland. However, the swelling resolved dramatically within 12 h with only supportive care and no specific treatment [Figure 2]. Mumps serology was negative. Review of literature revealed a case report of etoposide and melphalan induced transient parotitis and submandibular sialadenitis in nine of the 19 patients who received the drugs.<sup>[1]</sup> The children had developed symptoms of pain, tenderness and swelling of the glands within 4-16 h after administration of the drug and resolved within 72 h. Only analgesics were used for the discomfort and none of them developed any complications. Our child didn't require any specific treatment for the parotid swelling and received the remaining 4 days of chemotherapy without any adverse events. To the best of our knowledge, there are no other case reports of transient parotitis with standard dose of etoposide. We report this case for the pediatric hemato oncologists to be aware of this rare complication of etoposide even at lower doses than reported in case series. This knowledge of association of transient parotitis with a standard dose of etoposide will avoid unnecessary intervention and investigations in an otherwise uncomplicated case.

*Magatha Sneha Latha, Aruna Rajendran,  
Umapathy Pasupathy, Julius Xavier Scott*

Department of Pediatrics, Division of Pediatric Hemato Oncology,  
Sri Ramachandra Medical Centre, Porur, Chennai, Tamil Nadu, India  
E-mail: [jxscott@hotmail.com](mailto:jxscott@hotmail.com)

## REFERENCE

1. Crump M, Brandwein JM, Scott JG, Sutcliffe SB, Keating A. Acute transient parotitis after high dose etoposide and autologous bone marrow transplantation. *Bone Marrow Transplant* 1990;6:259-61.

### Access this article online

Quick Response Code:



Website:  
[www.ijmpo.org](http://www.ijmpo.org)

DOI:  
10.4103/0971-5851.133744