

A rare case of lung cancer presenting as an ischioanal fossa mass

Nishitha Shetty,

Ranvijay Singh¹,

Maryam Naveed²,

Ashwini M. Ronghe³,

Falguni Shashikant Barot⁴

Department of Medical Oncology, Father Muller Medical College, Mangalore, Karnataka,

¹Department of Medicine, RCSM Government Medical College, CPR Hospital, Kolhapur,

³Department of Medicine, Grant Medical College and Sir JJ Group of Hospitals, Mumbai,

⁴Department of Medicine, Byramjee Jeejeebhoy Medical College, Pune, Maharashtra, India,

²Department of Medicine, CMH Lahore Medical College, Lahore, Pakistan

Address for correspondence:

Dr. Ranvijay Singh,
Department of Medicine,
RCSM Government Medical
College, CPR Hospital,
Near Dasara Chowk,
Kolhapur - 416 002,
Maharashtra, India.
E-mail: ranvijay707@yahoo.co.in

ABSTRACT

Lung cancer metastasis commonly involves the adrenal glands, liver, bone, and brain. However, it can have some rarer forms of metastatic presentation making diagnosis difficult, especially in nonsmokers. We describe a rare case of lung cancer with metastasis to the ischioanal fossa. Overall, this case emphasizes that consideration should be given to wide range of diagnosis in atypical cases of anorectal masses. Lung cancer presenting as an ischioanal mass is not reported so far.

Key words: *Ischioanal fossa, lung cancer, metastasis*

INTRODUCTION

Lung cancer is one of the most frequent and commonly diagnosed cancers worldwide, with a high mortality rate.^[1] The most common sites for distant metastases of lung cancer are adrenal glands, liver, brain, and bone.^[2,3] We present a case of a 75-year-old nonsmoker male who presented with an ischioanal mass. The biopsy showed adenocarcinoma without any colorectal mucosal lesion, which prompted a positron emission tomography (PET) computed tomography (CT) scan evaluation, leading to the diagnosis of Stage 4 lung cancer with metastasis to the ischioanal fossa and adrenal glands.

CASE REPORT

A 75-year-old male, nonsmoker, diabetic, hypertensive, postcoronary bypass was referred to our hospital with complaints of burning sensation in perianal area with a

mass-like sensation causing hindrance to sit. There was no history of constipation, bleeding per-rectum, pain or mass per-abdomen or weight loss. On examination, a hard mass was felt on the external side around the perianal region. Per-rectum revealed a growth on the left lateral part around the anal region, no growth felt in the rectal mucosa, and the upper extent of the tumor could not be delineated. There was no other palpable mass or peripheral lymphadenopathy. Other systemic examination was normal. Contrast-enhanced CT of the abdomen and pelvis done outside showed a 3.7 cm × 4.2 cm × 2.8 cm mass in the perianal region, medially extending up to the external sphincter close to the anal verge. The mass was free from the prostate. The patient had undergone a biopsy

This is an open access article distributed under the terms of the Creative Commons Attribution-NonCommercial-ShareAlike 3.0 License, which allows others to remix, tweak, and build upon the work non-commercially, as long as the author is credited and the new creations are licensed under the identical terms.

For reprints contact: reprints@medknow.com

How to cite this article: Shetty N, Singh R, Naveed M, Ronghe AM, Barot FS. A rare case of lung cancer presenting as an ischioanal fossa mass. *Indian J Med Paediatr Oncol* 2016;37:300-2.

Access this article online

Quick Response Code:



Website:
www.ijmpo.org

DOI:
10.4103/0971-5851.195743

from the mass outside, which was suggestive of moderately differentiated adenocarcinoma. No immunochemical (IHC) evaluation was done. With a suspicion of a skip lesion from a higher growth, we performed a sigmoido-colonoscopy which showed a hard mass on the left side of perianal region with no clear growth arising from the rectal or anal mucosa. Carcinoembryonic antigen was 205.7 ng/ml. In view of unusual site of adenocarcinoma in the perianal region, a PET/CT scan was done which revealed a 2.6 cm × 2.3 cm mass in the right lower lobe of lung with hilar and axillary lymphadenopathy, bilateral lung nodules with a small adrenal nodule along with a 4.8 cm × 3.5 cm mass in the left ischioanal fossa [Figures 1 and 2]. We finally concluded that the patient has Stage 4 adenocarcinoma lung with metastases to ischioanal fossa, bilateral lung, and adrenal gland. Epidermal growth factor receptor (EGFR) and anaplastic lymphoma kinase (ALK) mutation analyses were negative. The patient was started on pemetrexed-carboplatin chemotherapy. After two cycles of pemetrexed-carboplatin, the patient did not have any benefit. Hence, subsequently, his chemotherapy was changed to paclitaxel-carboplatin and after the first cycle itself the mass began to shrink.

DISCUSSION

Here, we present a case of lung adenocarcinoma with a rare presentation of an ischioanal mass in a nonsmoker which was diagnosed on PET/CT. Lung cancer metastases commonly involve the adrenal glands, bone, and brain.^[4] Some rare sites of metastasis published in the literature are subcutaneous nodules, thyroid gland, intracranial tumor-meningioma, and multiple cavitory lesions in a patient with wild-type EGFR.^[4-7] Primary neoplasms

occurring in the ischioanal fossa are very uncommon. Angiomyxoma is a rare neoplasm which can also present with a well-defined lobulated mass in the ischioanal fossa as in our case.^[8]

Lung cancer is generally believed to be smoker’s disease as compared to nonsmoker’s which many at times leads to delayed diagnosis in nonsmokers. In our patient, detailed imaging excluded primary origin in the abdominal cavity as well as from epithelial lining of the rectal and anal mucosa. The histopathology report suggested moderately differentiated adenocarcinoma which led to the suspicion of skip lesion, and later on, PET scan was done which showed the origin in the lung with metastasis to adrenal too. It is essential to distinguish pulmonary adenocarcinoma with intestinal differentiation from metastatic colorectal carcinoma because of critical differences in therapeutic strategies and prognosis, which can be done by IHC and EGFR analysis.^[9]

EGFR mutations seem to influence the site of metastasis with a positive EGFR status favoring pleural metastasis in pulmonary adenocarcinoma.^[10,11] Since EGFR and AKL mutation were found to be negative in our case, the treatment was started on pemetrexed (folate antagonist)-carboplatin

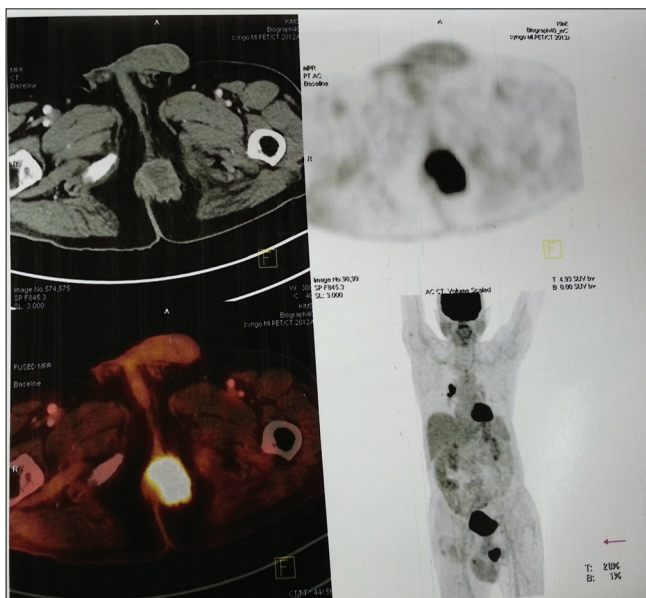


Figure 1: Positron emission tomography computed tomography showing fluorodeoxyglucose avid lesion in the ischioanal fossa

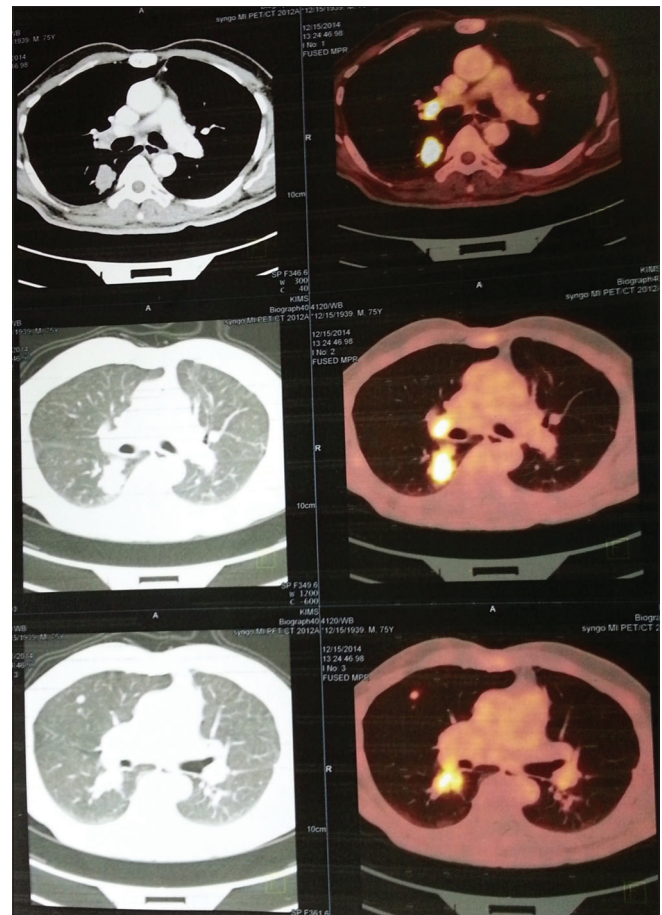


Figure 2: Positron emission tomography computed tomography showing fluorodeoxyglucose avid lung primary

chemotherapy and later on shifted to paclitaxel-carboplatin therapy which showed more effectiveness in suppressing the mass.

Overall, this case emphasizes that consideration should be given to wide range of diagnosis in atypical cases of anorectal masses. There are no similar reported cases of primary lung adenocarcinoma presenting as ischioanal fossa mass and this case represents a challenge in both diagnosis and long-term management.

CONCLUSION

There are no case reports of lung cancer presenting as an ischioanal fossa mass as the initial presentation. This case report emphasizes the varied forms of lung cancer presentation which is a diagnostic challenge, especially in nonsmokers.

Financial support and sponsorship

Nil.

Conflicts of interest

There are no conflicts of interest.

REFERENCES

1. GLOBOCAN Cancer Fact Sheets:Lung Cancers.Globocan.iarc.fr. N.p.2016. Available from: http://www.globocan.iarc.fr/Pages/fact_sheets_cancer.aspx?cancer=lung. [Last accessed on 2016 Jan 28].
2. Riihimäki M, Hemminki A, Fallah M, Thomsen H, Sundquist K, Sundquist J, *et al.* Metastatic sites and survival in lung cancer. *Lung Cancer* 2014;86:78-84.
3. Young WF Jr. Management approaches to adrenal incidentalomas. A view from Rochester, Minnesota. *Endocrinol Metab Clin North Am* 2000;29:159-85, x.
4. Zhao Q, Wang ZT, Sun JL, Han D, An DZ, Zhang DK, *et al.* Intratumoral heterogeneity of subcutaneous nodules in a never-smoker woman of lung squamous cell carcinoma detected on 18F-fluorodeoxyglucose positron emission tomography and computed tomography: A case report. *Medicine (Baltimore)* 2015;94:e851.
5. Murakami T, Taki M, Nambu T, Wakasa T, Kato T, Matsuda Y, *et al.* Diffuse thyroid enlargement following metastasis of lung adenocarcinoma. *Intern Med* 2015;54:807-12.
6. Glass R, Hukku SR, Gershenhorn B, Alzate J, Tan B. Metastasis of lung adenosquamous carcinoma to meningioma: Case report with literature review. *Int J Clin Exp Pathol* 2013;6:2625-30.
7. Murakami S, Manabe S, Yamada K. A case of lung adenocarcinoma with multiple cavitary metastases. *Jpn J Clin Oncol* 2015;45:504-5.
8. Clancy C, Iqbal Z, Sheehan M, Joyce MR. An unusual ischioanal fossa mass. *Int J Surg Case Rep* 2014;5:79-81.
9. Na II, Park JH, Choe du H, Lee JK, Koh JS. Association of epidermal growth factor receptor mutations with metastatic presentations in non-small cell lung cancer. *ISRN Oncol* 2011;2011:756265.
10. Wu SG, Gow CH, Yu CJ, Chang YL, Yang CH, Hsu YC, *et al.* Frequent epidermal growth factor receptor gene mutations in malignant pleural effusion of lung adenocarcinoma. *Eur Respir J* 2008;32:924-30.
11. Hoffman PC, Mauer AM, Vokes EE. Lung cancer. *Lancet* 2000;355:479-85.