

## Letter to the Editor-I

# Extramedullary Granulocytic Sarcoma

Sir

Granulocytic sarcomas are rare extramedullary tumours associated with hematologic disorders e.g. acute myeloid leukaemia (FAB types M2, M4, M5), myelodysplastic syndrome and myeloproliferative disorders or rarely may arise *de novo*. Most common sites are bones and lymph nodes. Presentation as a fungating mass is rare.

**CASE :** A 17 year old female presented in April 2008 with a history of large fungating mass associated with pain in her right thigh along with stiffness of right leg for 1 year duration. The patient had no complaints of bone pain, fever, bruising, malaise or weight loss. The mass was gradually increasing in size and was darkening in colour. On examination, a large ulceroproliferative and cauliflower like mass about 12 × 10 cm was palpable in the anterior aspect of her right thigh. It was yellowish-brown in colour, firm, non-mobile and tender (Fig.1).

MRI scan of right thigh on T2- weighted image-lesion revealed a heterogeneous mass lesion involving cutaneous and subcutaneous portion of inguinal region and upper thigh. The lesion was infiltrating into deep muscle planes and neuro-vascular planes with involvement of inguinal canal and marked soft tissue edema bone was not involved (Fig. 2).

Incisional biopsy done from the mass, revealed sheets of round or oval cells with vesicular nuclei and scanty cytoplasm in dermis and was infiltrating the surrounding muscle fibres. Mitotic figures were evident. A clinical diagnosis of a malignant small round cell tumour was made (Fig. 3).

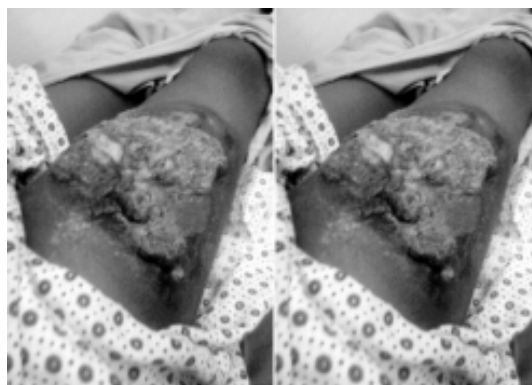

Figure 1: Photograph of the lesion showing an ulceroproliferative and cauliflower like growth in anterior aspect of right thigh.

On immunohistochemistry cells were immunoreactive for myeloperoxidase (MPO) and leucocyte common antigen (CD45) and immunonegative for CD3, CD20 and TdT. A diagnosis of extramedullary myeloid tumour (Granulocytic sarcoma) was made.

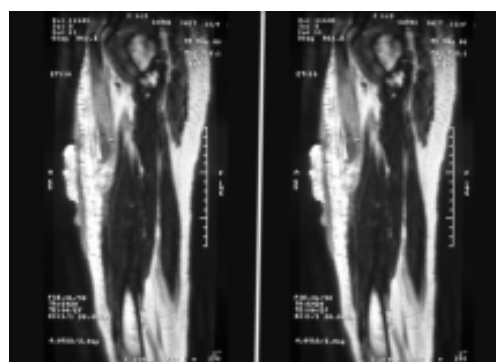


Figure 2 MRI scan showing a heterogeneous mass lesion in inguinal region and upper thigh on T2W1 and involvement of inguinal canal and neurovascular planes.

Blood counts revealed: Hb 9.5gm%, WBC 11600/cmm ( $N_{07}$ ,  $L_{15}$ ,  $E_{02}$ ,  $M_{02}$ ,  $B_0$  and blast cells 74%), and platelet 200,000/cmm. Bone marrow aspirate showed hypercellular BM with > 90% blast cells with fine nuclear chromatin,

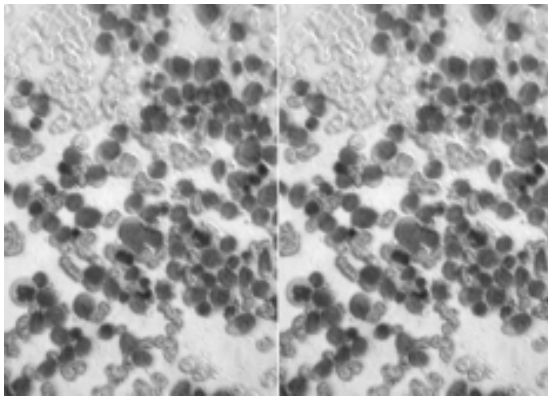


Figure 3: Photomicrograph of the lesion in right thigh showing sheets of round or oval cells with vesicular nuclei and scanty cytoplasm. (H&E stained 40x)

prominent nucleoli and scanty light basophilic cytoplasm. Occasional cells showed Auer rods. (Fig. 4) The features were consistent with AML-M1. She was advised systemic chemotherapy.

#### COMMENTS:

Granulocytic sarcomas (also called chloroma) are rare, extramedullary tumour masses of immature malignant white blood cells called myeloblasts.

The condition was first described by the British physician A. Burns in 1811<sup>1</sup>, although the term 'chloroma' did not appear until 1853.<sup>2</sup> The link between chloroma and acute leukaemia was first recognised in 1902 by Dock and Warthin.<sup>3</sup> However, because upto 30% of these tumours can be white, gray or brown rather than green, the more correct term, granulocytic sarcoma (GS) was proposed by Rappaport in 1967.<sup>4</sup> Granulocytic sarcomas are associated with AML. FAB sub Types M2, M4 and M5; Expression of surface markers CD2, 7 and 56, Cytogenetic abnormalities t(8;21) or inv (16).

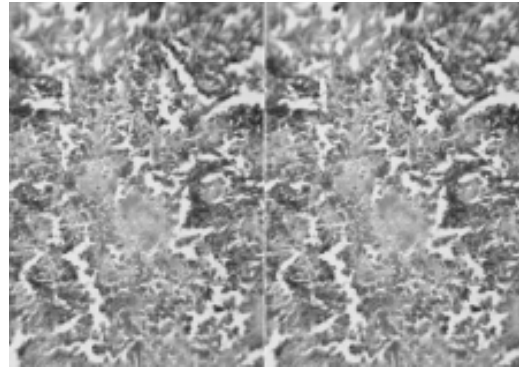


Figure 4: Photomicrograph of bone marrow aspirate showing innumerable blast cells with prominent nuclei and scanty basophilic cytoplasm (40x)

It may also be associated with myelodysplastic syndrome (MDS) and myeloproliferative disorders (MPS). Very rarely, granulocytic sarcoma can arise de novo without a known pre-existing or concomitant diagnosis of acute leukaemia or MDS/ MPS. In almost all reported cases of primary granulocytic sarcoma, acute leukaemia has developed shortly afterward.<sup>5</sup>

GS may occur at sites like subperiosteal bone- skull, pelvis, ribs, sternum; lymph node; skin; gums and rarely in epidural sites, small intestine, mediastinum, uterus and ovaries. The WHO<sup>6</sup> has classified granulocytic sarcoma into 3 main types, depending on the degree of maturation (i) Blastic- composed mainly of myeloblasts (ii) Immature- myeloblasts and promyelocytes (iii) Differentiated- promyelocytes and more mature myeloid cells.

The diagnosis of granulocytic sarcoma can be difficult and some times may be misdiagnosed. In one published series, 47% patients were initially misdiagnosed, most often as having a malignant lymphoma.<sup>7</sup> In our case, the location, invasive nature and histopathological examination of the tumour made malignant small round cell tumour or soft tissue sarcoma the most probable diagnosis. Further investigations-CBC, bone marrow morphology, immunocytochemistry, immunophenotyping and cytogenetics helped in diagnosis.<sup>8</sup>

Optimal therapy for these patients has not been well defined. Systemic chemotherapy like for AML is typically utilised as the first line treatment; unless there is an emergent indication for local treatment for granulocytic sarcoma (e.g. compression of spinal cord). If the lesion persists after completion of induction chemotherapy, local treatment e.g. surgery or radiotherapy must be considered. Prognosis can be variable.<sup>9,10</sup>

#### REFERENCES:

1. Burns A. *Observations of Surgical Anatomy, Head and Neck*. Edinburgh, United Kingdom, Thomas Royce and Co, 1811;p364-366.
2. King A. *A Case of Choloroma*. *Monthly J Med*, 1853;17:p17.
3. Dock G, Warthin AS. *A new case of Choloroma with Leukaemia*. *Trans Assoc Am Phys*, 19:64,1904;p115
4. Rappaport H. *Tumours of the hematopoietic system, in Atlas of Tumour Pathology, Section III, Fascicle 8*. Armed Forces Institute of Pathology, Washington DC, 1967;p241-247.
5. Byrd JC, Edenfield JW, Shields DJ, et al. *Extramedullary myeloid tumours in acute nonlymphocytic leukaemia: A clinical review*. *J Clin Oncol*, 1995;13:p1800.
6. Jaffe ES, Harris NL, Stein H. *World Health Organisation Classification of Tumours- Tumours of Haematopoietic and Lymphoid Tissues*, 2001;p105.
7. Yamauchi K, Yasuda M. *Comparison in treatments of nonleukaemic granulocytic sarcoma: report of 2 cases and a review of 27 cases in the literature*. *Cancer* 2002;94(6);p1739-1746.
8. Traweek ST, Arber DA, Rappaport H, et al. *Extramedullary myeloid cell tumours: an immunohistochemical and morphologic study of 28 cases*. *Am J Surg Pathol*, 1993;17:p1011-1019
9. Tanravahi R, Qumsiyeh M, Patil S, et al. *Extramedullary leukaemia adversely affects hematologic complete remission and overall survival in patients with t(8;21)(q22;q22): Results from Cancer and Leukaemia Group B 8461*. *J Clin Oncol*, 1997;15:p466
10. Bisschop MM, Revesz T, Bierings M, et al. *Extramedullary infiltrates at diagnosis have no prognostic significance in children with acute myeloid leukaemia*. *Leukaemia*, 2001;15:p46

**Sayan Kundu, S Chatterjee,  
D Mondol, A G Dastidar, A Roy**  
Department of Radiotherapy, Medical College  
Hospital, Kolkata-700073(India)  
Email: drsayan203@yahoo.co.uk