

## Extrarenal Nephroblastoma

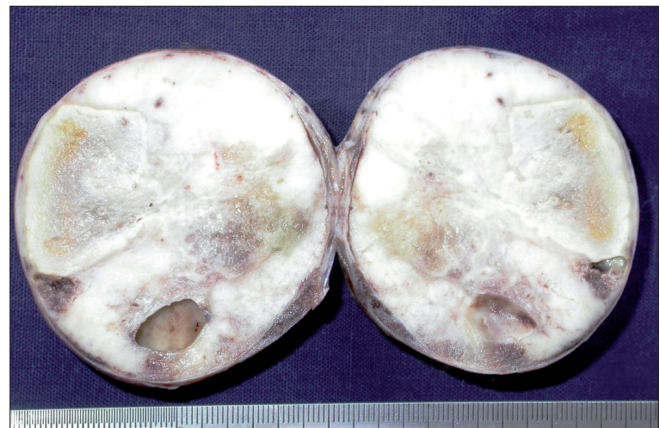Sir,

Nephroblastoma is the commonest primary malignant tumor of kidney in children occurring between the ages of 2 and 5 years. The occurrence of the extrarenal nephroblastoma without the involvement of kidney is exceedingly rare.<sup>[1]</sup> It is generally located anywhere in the retroperitoneum from the nephric region down through lumbar, iliac, pelvic region to inguinal canal.<sup>[2]</sup> The clinical presentation may vary depending on its location with pressure effects on the adjacent vital structures such as blood vessels, nerves, ureter, bladder, and bowel. We report a rare well-proven case of an extrarenal nephroblastoma arising in the retroperitoneum.

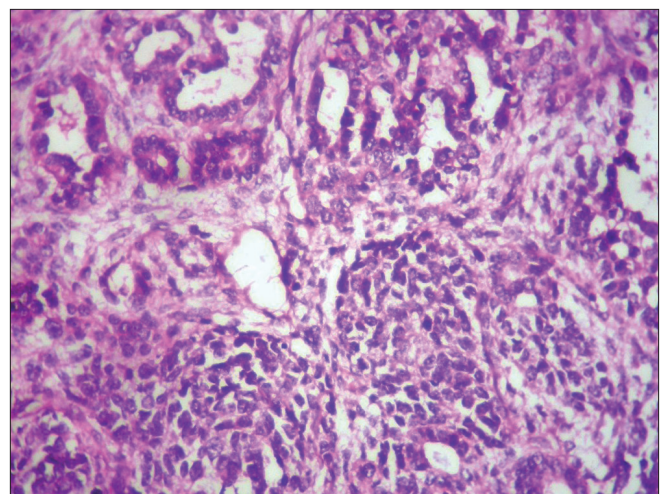
A girl aged 6 years was brought to the hospital for pain abdomen, mass per abdomen, increased frequency of defecation and micturation of 6 months duration. There was no history of passing blood in stool and urine. A nontender freely mobile mass, with rounded border, firm to hard in consistency, was situated in right lower lumbar and iliac fossa. No other abnormalities were detected on systemic examination. Ultrasonography revealed a heterogeneous mass measuring  $58 \times 65 \times 51 \text{ mm}^3$  with specks of calcification, situated anterior to right iliac vessels and lateral to urinary bladder. Right kidney showed minimal hydronephrosis, and left kidney appeared normal. Urine examination showed specific gravity 1.015, pH 6. Urine sediment showed 2–3 polymorphs per high power field, calcium oxalate crystals, and no erythrocytes were seen. At operation, a single fully encapsulated spherical retroperitoneal mass was seen in right iliac fossa which was seen sitting on right ureter and right iliac vessels. The mass was displacing small bowel, cecum and appendix. Both kidneys and ovaries appeared normal. The mass was measuring 6 cm in diameter and was shelled out easily and sent for histopathological examination. Cut surface appeared soft fleshy to greyish white with areas of necrosis and small foci of cystic change [Figure 1]. Microscopy revealed predominantly islands and sheets of blastemal cells with foci of abortive glomeruli and tubular epithelial differentiation separated by variable

amounts of connective tissue containing spindle cells, myocytes with striations, and myxoid areas [Figure 2]. Tumor cells showed mild pleomorphism, occasional mitotic figures with extensive areas of tumor necrosis. The capsule contained islands of occasional compressed tubules. Areas of anaplasia were not seen.

Nephroblastoma or Wilms' tumor is the commonest malignant tumor of children occurring between 2 and 5 years of age, arising from embryonic kidney tissue. Extrarenal nephroblastomas are exceedingly rare retroperitoneal tumors without involving the kidneys. Extrarenal nephroblastomas vary in their clinical presentation depending on their location and pressure effects on bowel, bladder, ureter, blood vessels, and nerves. Other sites of occurrence are inguinal region, endocervix, uterus, epididymis, ova testis and any place in retroperitoneum along paravertebral area have been described.<sup>[2]</sup> The histogenesis, morphology, clinical staging,



**Figure 1:** Well-encapsulated spherical mass showing grayish white cut surface with necrosis and cystic change



**Figure 2:** Photomicrography shows spindle cell stroma, separating lobules of blastemal tissue containing abortive tubules and glomeruli (H and E, 400x)

behavior, prognosis, and response to therapy are similar to those of renal nephroblastomas.<sup>[1]</sup>

Extrarenal nephroblastomas are believed to arise from heterotrophic metanephric blastema. Nephrogenic rests (NR) and nephroblastomatosis are considered to be the precursor lesions of nephroblastoma and most rests are destined for eventual atresia.<sup>[3]</sup> NR are an abnormal focal persistence of clusters of embryonal cells (metanephric blastema) into later infancy and childhood.<sup>[3,4]</sup> They are present multifocal or diffuse in nephroblastomatosis. Focal NR may be located in perilobular or intralobular region. Perilobular NR occurs in fetal overgrowth and with certain overgrowth syndromes. Intralobular NR are frequently associated with deletions or mutations of WT1.<sup>[3]</sup> Nephroblastomatosis can be perilobular (subcapsular), pan lobular (diffuse cortical), or intralobular (in the renal parenchyma along the columns of bertin). Nephroblastomatosis is also associated with (1) WAGAR syndrome, (2) Denys-Drash Syndrome, and (3) Beckwith Weidman Syndrome. These syndromes are associated with increased risk of developing Wilms' tumor, suggesting related manifestations of genetic damage, affecting single gene or closely linked genes WT1 and WT2. The expression of WT1-mRNA has also been seen in some extrarenal nephroblastoma, indicating similar histogenesis as that of renal nephroblastoma.<sup>[4]</sup>

Staging and management of extrarenal nephroblastoma will be the same as those of renal nephroblastomas.<sup>[1]</sup> Histologically, these tumors show similar to renal nephroblastomas.<sup>[2]</sup> The presence of anaplasia, characterized by extreme polyploidy, with nuclear and mitotic atypia, indicates poor prognosis as they show increased resistance to therapy. Distribution of anaplasia is having critical prognostic relevance.<sup>[5]</sup> The present case did not show any anaplastic features. The diagnosis of extrarenal Wilms's tumor has to be done after ruling out an extension from the intrarenal Wilms' tumor or a metastatic lesion. However, the final diagnosis is established by histopathology.<sup>[2]</sup>

The recommended management of the extrarenal nephroblastoma is similar to intrarenal nephroblastoma. All cases treated by surgery need postoperative adjuvant chemotherapy, and drugs used for renal nephroblastoma, were equally effective for extrarenal nephroblastoma.<sup>[3]</sup> Radiotherapy should be reserved for those patients with unresectable gross residual tumor and those with distant metastasis. This case was treated surgically with postoperative adjuvant chemotherapy. There was no evidence of recurrence of the tumor after 4 years of treatment.

**S Teerthanath**

Department of Pathology and Surgery,  
K.S. Hegde Medical Academy, Nithyanand Nagar,  
Derelakatte, Mangalore, Karnataka, India.

**Address for correspondence:** Dr. S. Hariprasad,  
E-mail: raohariprasads@yahoo.co.in

## REFERENCES

1. Waingankar VS, Meisheri IV, Patel MP, Ramesh S, Naregal A, Muthal P. Extrarenal Wilms' tumour: a case report and review of literature. *Indian J Cancer* 1995;32:135-40.
2. Lakhkar BN, Rajgopal KV, Shetty CM, Avinash KR. Extrarenal wilms' tumour: A case report. *Indian J Radiol Imaging* 2004;14:147-8
3. Roberts DJ, Haber D, Sklar J, Crum CP. Extrarenal Wilms' Tumour. A study of their relationship with classical renal Wilms' Tumour using expression of WT1 as a molecular marker. *Lab Invest* 1993;68:528-36.
4. Faria P, Beckwith JB, Mishra K, Zuppan C, Weeks DA, Breslow N, Green DM. Focal versus diffuse anaplasia in Wilms tumor—new definitions with prognostic significance: a report from the National Wilms' Tumor Study Group. *Am J Surg Pathol* 1996;20:909-20.
5. Beckwith JB. New developments in Pathology of Wilms' Tumour. *Cancer Invest* 1997;15:153-62.

### Access this article online

#### Quick Response Code:



**Website:**  
www.jlponline.org

**DOI:**  
10.4103/0974-2727.78572