

Squamous Predominant Teratoid Wilms' Tumor

Yogesh Kumar Yadav, Uma Sharma, Kusum Gupta, Rashmi Arora

Department of Pathology, V.M.M.C and Safdarjung Hospital, New Delhi- 29, India

Address for correspondence: Dr. Yogesh Kumar Yadav, E-mail: dr.yogi007@gmail.com

ABSTRACT

Teratoid Wilms tumor is an unusual histological variant of nephroblastoma with predominant heterologous component. Frequently present components include adipose tissue, glial tissue, muscle, cartilage or bone. The presence of squamous epithelial component on the other hand is rarely reported. We describe a case of unilateral teratoid Wilms' tumor in a 2-year-old boy with lung metastasis. In this case, tumor showed the familiar triphasic histologic pattern of nephroblastoma along with extensive squamous epithelial component.

Keywords: Teratoma, Wilms tumor, squamous epithelium

INTRODUCTION

Teratoid Wilms tumor, a rare variant of nephroblastoma, has a predominance of heterologous elements. To date less than 30 cases of teratoid Wilms tumor have been reported in the literature.^[1-3] There is only one case in the literature, which has the squamous epithelial component comprising 70% of the tumor.^[4] We describe a case in which the squamous epithelium with keratin cysts comprised majority (about 75%) of tumor mass. Metastasis is seldom reported in teratoid wilms. Our patient presented with lung metastasis.

CASE REPORT

A 2-year-old boy presented with palpable mass on the right side of abdomen for 2 months. Physical examination revealed a firm mass that was palpable in the lumbar region. Contrast-enhanced computed tomography (CECT) scan showed large heterodense lesion in the right lumbar region measuring 17 cm × 8 cm × 7cm. The right lung showed nodular opacities

in posterior and lateral basal segments of about 0.5 cm in diameter suggestive of metastasis. CECT scan done after 6 weeks of chemotherapy showed little change in the size of tumor and the patient underwent nephrectomy.

Grossly, nephrectomy specimen measured 17 cm × 8 cm × 6 cm that was soft in consistency. The cut section was predominantly solid and pale grey with areas of cystic change, necrosis, and hemorrhage. A thin segment of normal kidney was seen compressed at periphery [Figure 1].

Microscopically, the tumor showed classical triphasic pattern with blastemal, epithelial, and mesenchymal components without anaplasia; about 75% of the tumor revealed areas of squamous differentiation with keratin pearl formation but without adnexal structures [Figures 2 and 3]. There were also small foci of mature adipose tissue and glial tissue [Figure 4]. Capsular, renal sinus, or vascular invasions were not observed. There was no lymph node metastasis. These findings were compatible with teratoid Wilms' tumor.

DISCUSSION

Wilms' tumor is an embryonic tumor typically composed of variable admixture of blastemal, epithelial and stromal components. Wilms' tumor can include heterologous elements in addition to these components and Variend *et al*,^[5] in 1984,

Access this article online	
Quick Response Code: 	Website: www.jlponline.org
	DOI: 10.4103/0974-2727.98675

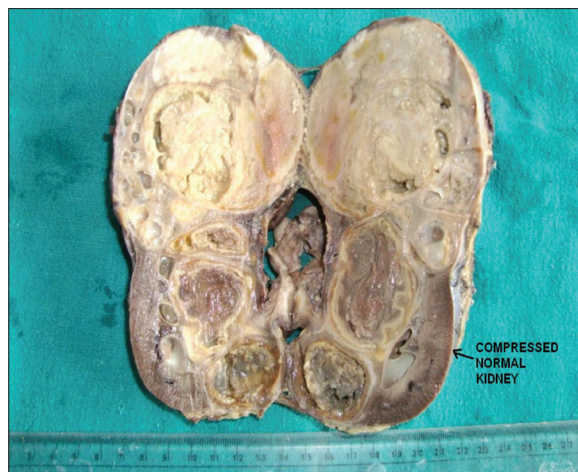


Figure 1: Gross-predominantly cystic appearance of teratoid kidney

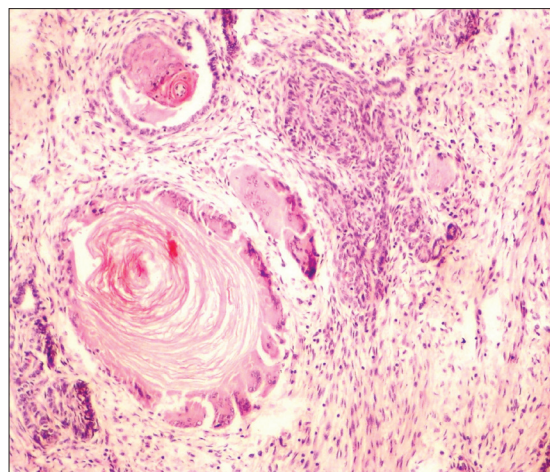


Figure 2: Giant cell reaction to keratin with blastema. (H and E, x400)

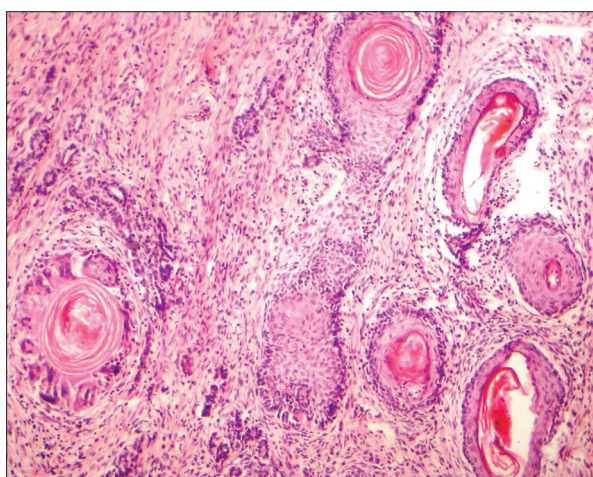


Figure 3: Squamous differentiation with keratin pearls. (H and E, x400)

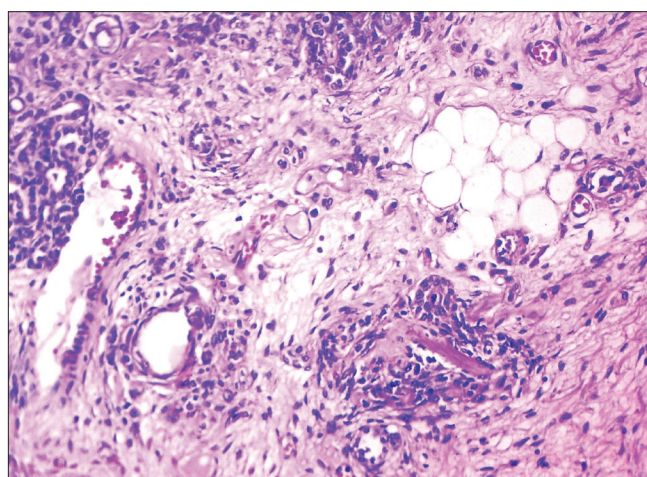


Figure 4: Adipose tissue differentiation with foci of blastema. (H and E, x400)

coined the term teratoid Wilms tumor for them. Fernandes *et al.*^[6] defined teratoid Wilms as a tumor that contains heterologous elements comprising more than 50% of the tumor mass. To date, less than 30 cases of teratoid Wilms tumors have been reported.^[1-3]

The pathogenesis of this entity is still debated; it is likely that it originates from totipotent primitive metanephric blastema. The variable presence of intracellular matrix proteins may influence the presence, extent, and diversity of heterologous differentiation.^[7,8] The teratoid elements seen frequently are skeletal muscle, smooth muscle, adipose tissue, glial tissue, cartilage, bone, and are generally assumed to represent aberrant mesenchymal differentiation. Squamous epithelium on the other hand is rarely reported.^[9] There is only one case of teratoid Wilms in the literature, reported by Karaka I *et al.*, which had squamous epithelial component comprising 70% of the tumour. We report a case that showed the familiar triphasic pattern of nephroblastoma along with the extensive squamous epithelial components constituting about 75% of the tumor.

The differential diagnosis of teratoid Wilms is intrarenal teratoma, metastatic germ cell tumor, and retroperitoneal infiltration of teratoma.^[10] In our case, classical triphasic pattern of Wilms tumour was seen and there was no attempt to form the adnexal structures or organogenesis thus ruling out intrarenal teratoma. Also, the presence of normal testis excluded the possibility of metastatic testicular germ cell tumor. Renal capsule was also free of tumor so retroperitoneal infiltration of teratoma was also ruled out.

Although it is reported that teratoid Wilms' tumor is not usually aggressive or has metastatic potential.^[4] The case reported by Karaka *et al.*, which had extensive squamous areas, died of metastasis. Our patient had lung metastasis at the time of presentation. In our case, there were no areas of dysplasia or nephroblastomatosis. Whether the squamous differentiation is associated with higher stage at presentation remains to be seen.

The treatment of teratoid Wilms tumor has not yet been established because of its rarity and varying tumor

components.^[11,12] There is inconsistent response with chemotherapy.^[11,12] Both surgeons and pathologists should be aware that the treatment of this rare variant should be focused on total surgical removal of the tumor.

REFERENCES

1. Treetipsatit J, Raveesunthornkiet M, Ruangtrakool R, Sanpaki K, Thorner PS. Teratoid Wilms' tumor: case report of a rare variant that can mimic aggressive biology during chemotherapy. *J Pediatr Surg* 2011;46:e1-6.
2. Sultan I, Ajlouni F, Al-Jumaily U, Al-Ashhab M, Hashem H, Ghandour K, *et al.* Distinct features of teratoid Wilms tumor. *J Pediatr Surg* 2010;45:e13-9.
3. Song JS, Kim IK, Kim YM, Khang SK. Extra renal teratoid Wilms' tumor: Two cases in unusual locations, one associated with elevated serum AFP. *Pathol Int* 2009;60:35-41.
4. Karaca I, Sencan A, Ortaç R, Bostanci-Sencan A, Mir E. Teratoid Wilms' tumor: a case report. *Turk J Pediatr* 2000;42:242-5.
5. Variend S, Spicer RD, Mackinnon AE. Teratoid Wilms' tumor. *Cancer* 1984;53:1936-42.
6. Fernandes ET, Parham DM, Ribeiro RC, Douglass EC, Kumar AP, Wilimas J. Teratoid Wilms' tumor: the St Jude experience. *J Pediatr Surg* 1988;23:1131-4.
7. Beckwith JB, Kiviat NB, Bonadio JF. Nephrogenic rests, nephroblastomatosis, and the pathogenesis of Wilms' tumor. *Pediatr Pathol* 1990;10:1-36.
8. Sariola H, Ekblom P, Rapola J, Vahery A, Timple R. Extracellular matrix and epithelial differentiation of Wilms Tumor. *Am J Pathol* 1985;118:96-107.
9. Parikh B, Trivedi P, Shukla K. A unilateral teratoid Wilms' tumor with raised serum alpha-fetoprotein level. *Indian J Pathol Microbiol* 2007;50:317-9.
10. Beckwith JB. Wilms' tumor and other renal tumors of childhood: a selective review from the National Wilms' Tumor Study Pathology Center. *Hum Pathol* 1983;14:481-92.
11. Inoue M, Uchida K, Kohei O, Nashida Y, Deguchi T, Komada Y, *et al.* Teratoid Wilms' tumor: a case report with literature review. *J Pediatr Surg* 2006;41:1759-63.
12. Gupta DK, Sharma S, Agarwal S, Carachi R. Saga of wilms tumour: Lessons learnt from the past. *J Indian Assoc PediatrSurg* 2005;10:217-28.

How to cite this article: Yadav YK, Sharma U, Gupta K, Arora R. Squamous predominant teratoid wilms' tumor. *J Lab Physicians* 2012;4:50-2.

Source of Support: Nil. **Conflict of Interest:** None declared.